

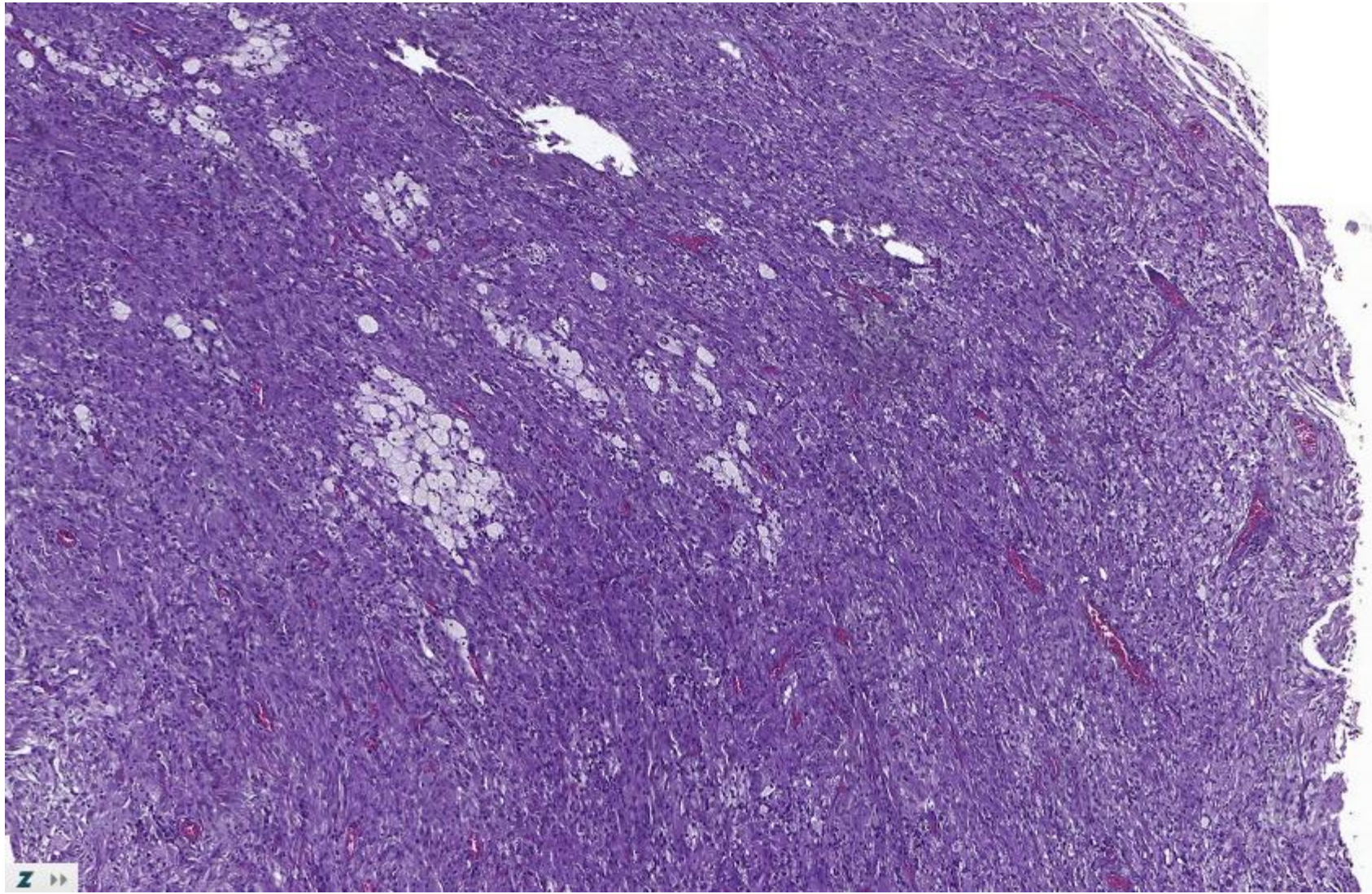


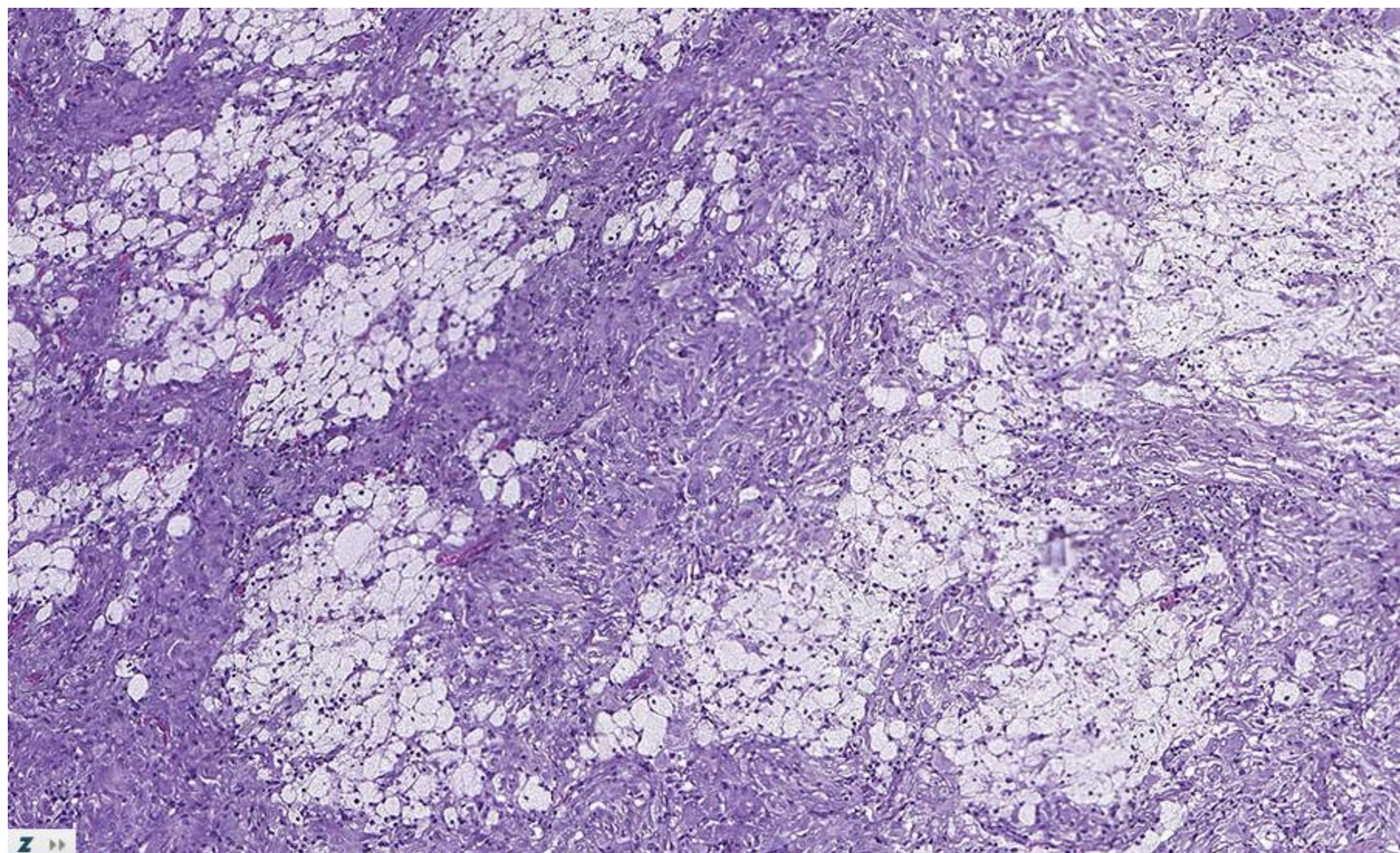
Sociedade Brasileira de Patologia

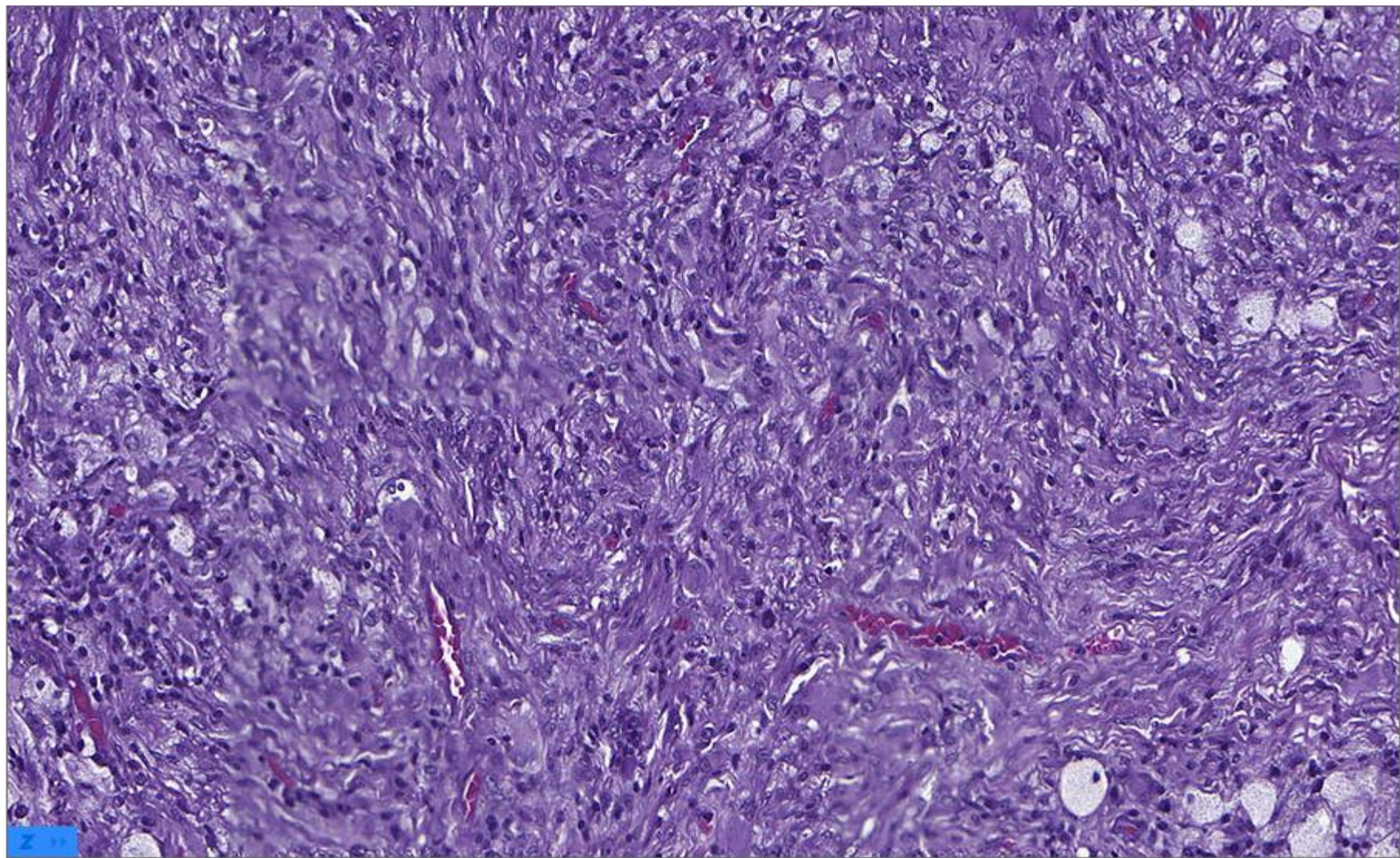
- Paciente do sexo masculino, 50 anos.
Tumor meníngeo. Meningioma?

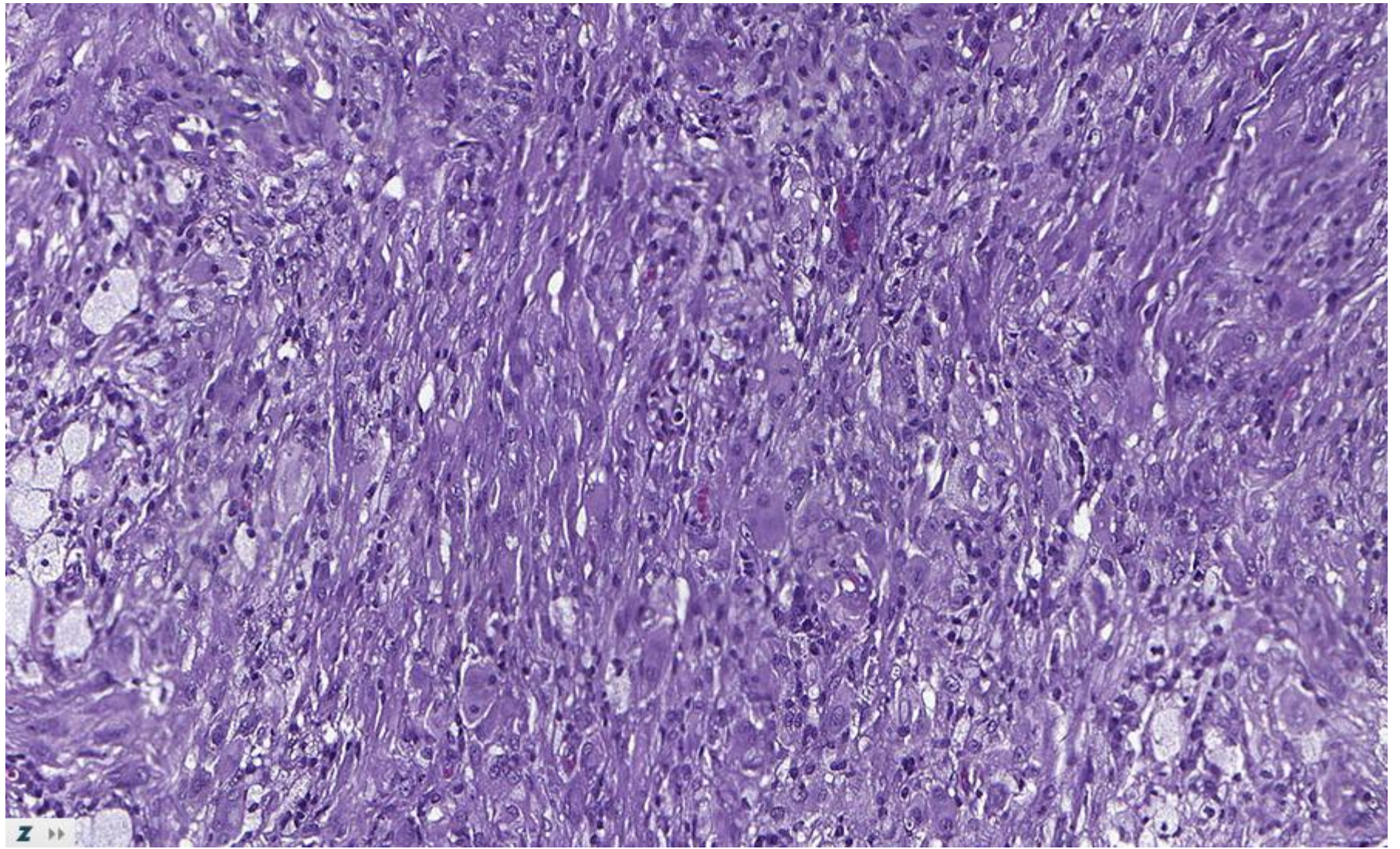
Emílio Pereira
emilio@szd.com.br

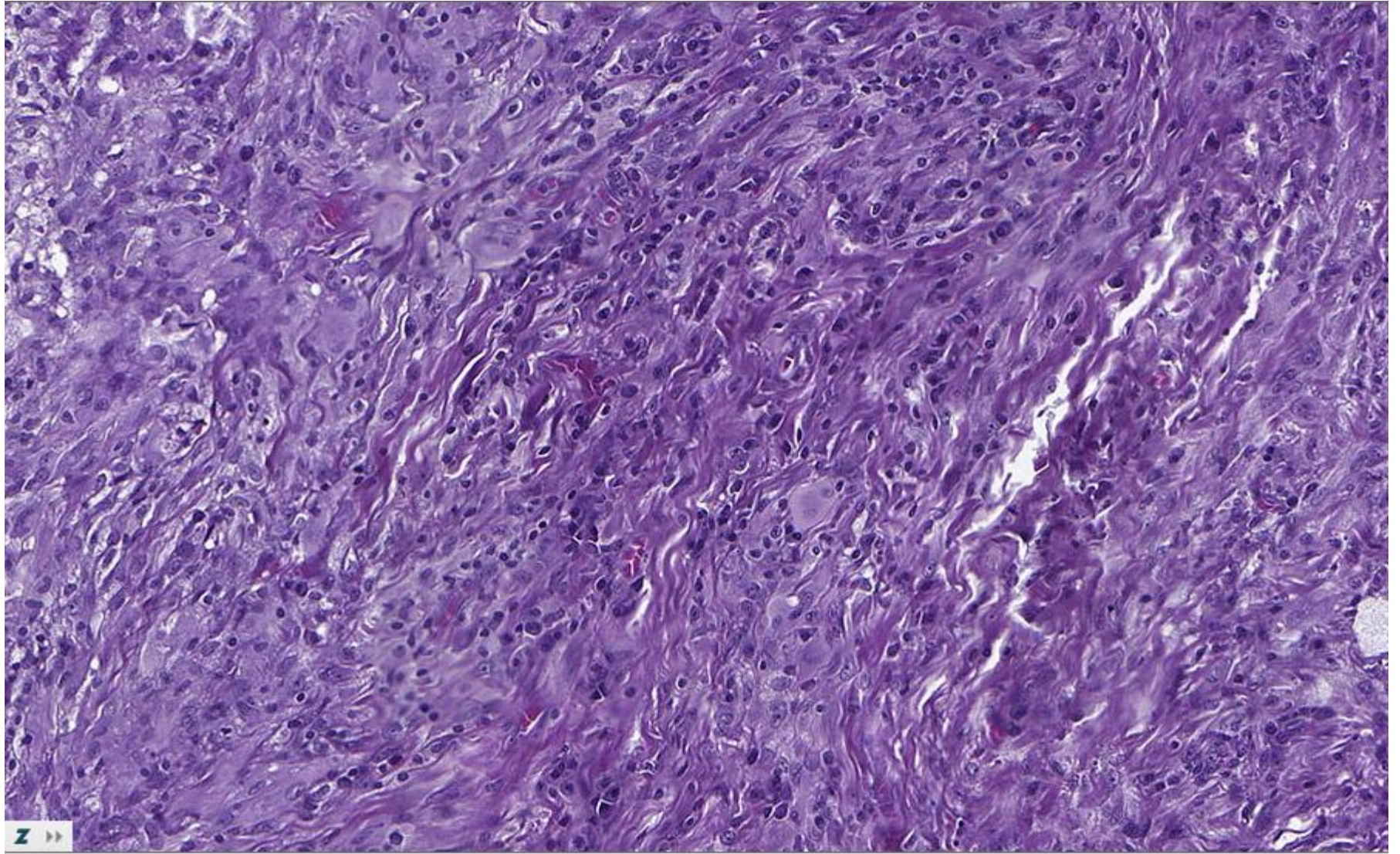
SALOMÃO ZOPPI
DIAGNÓSTICOS

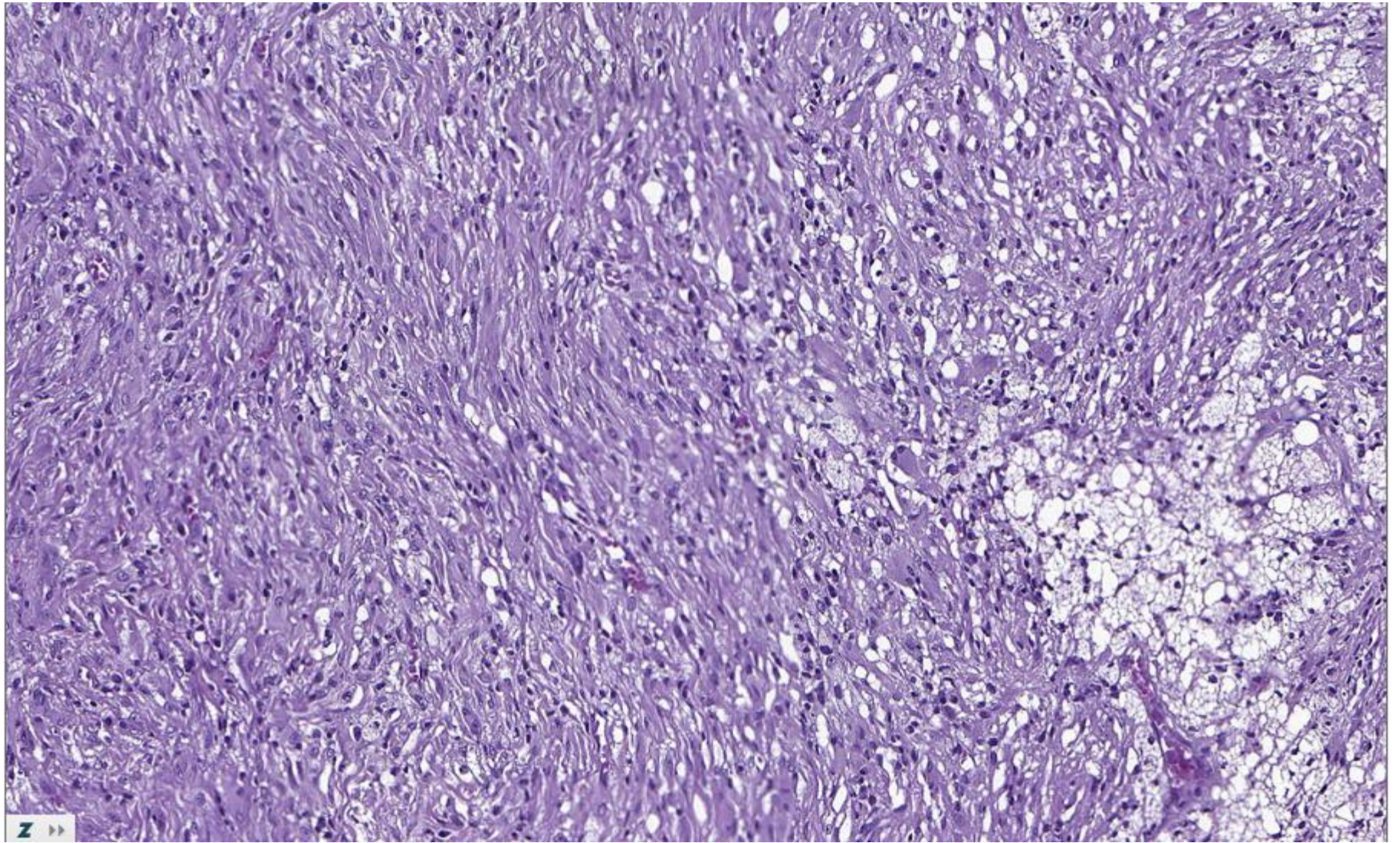


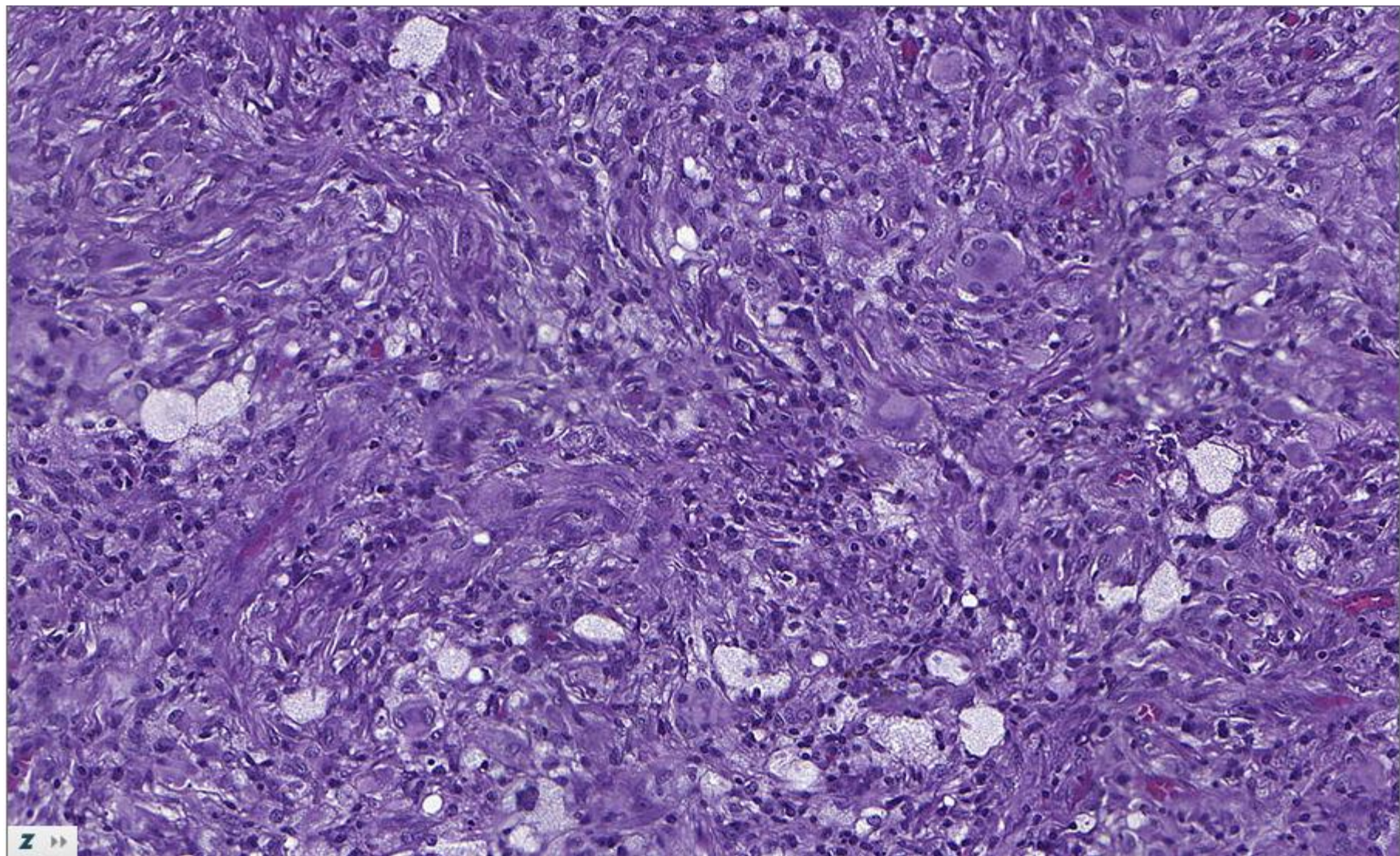


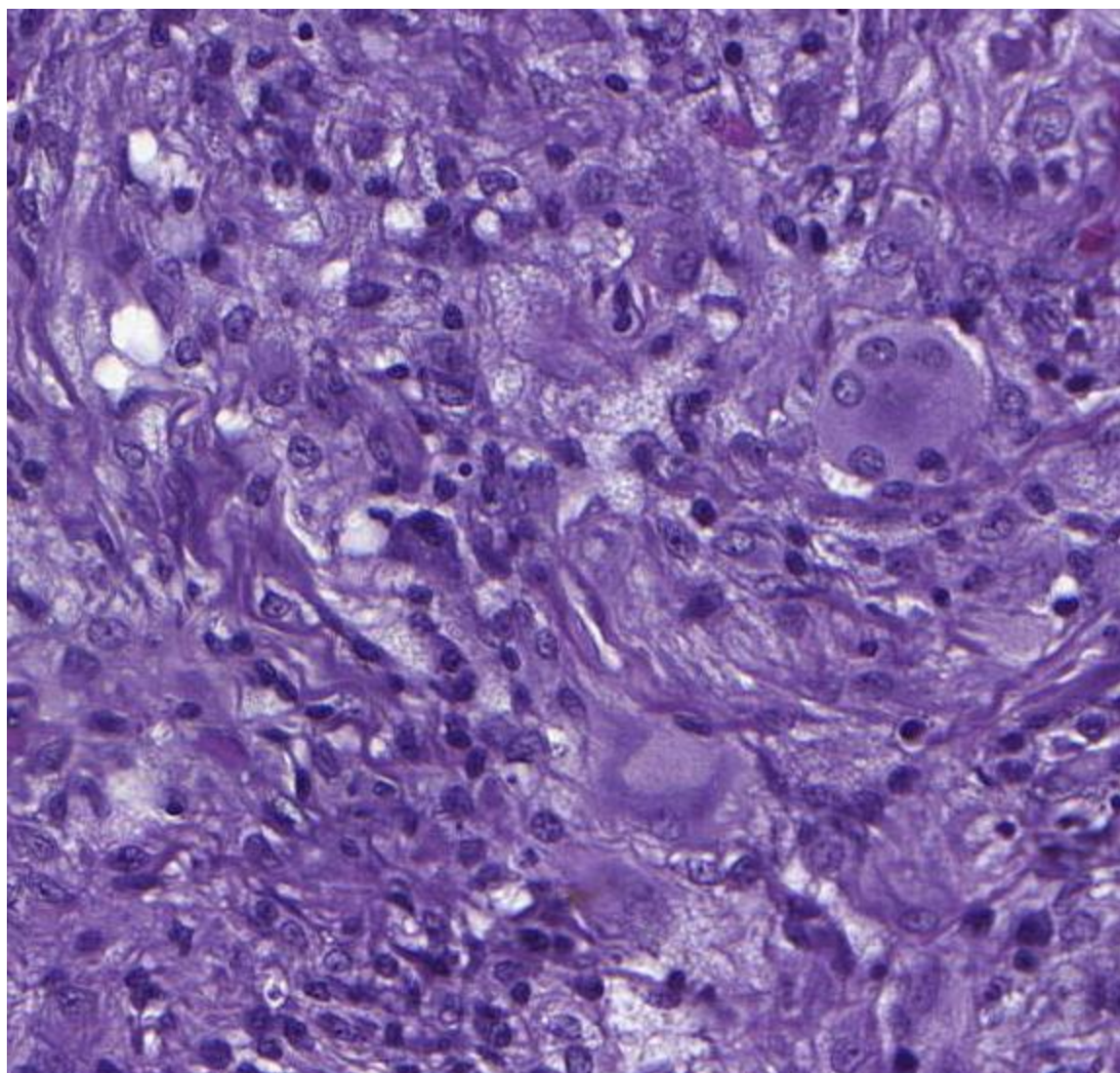




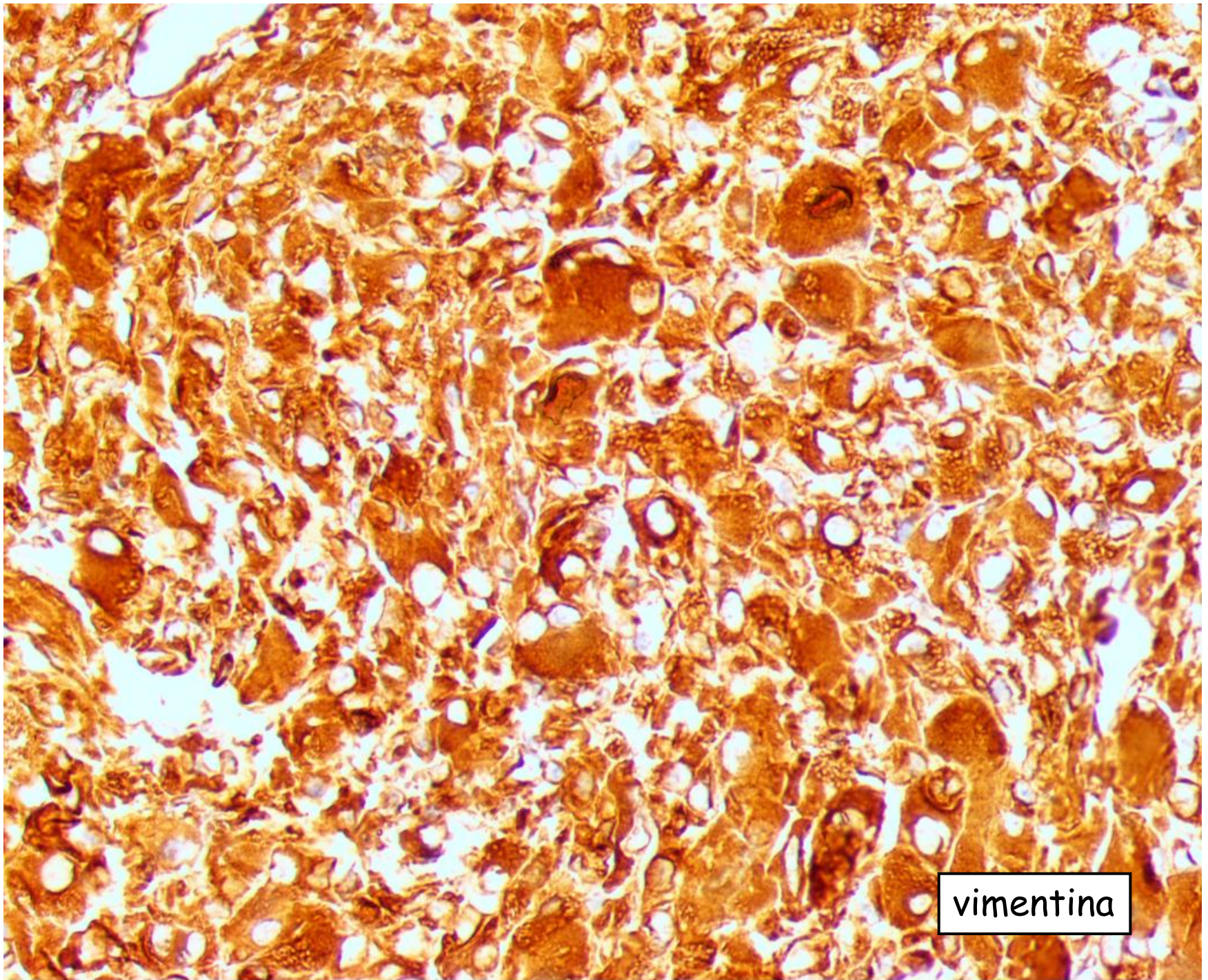




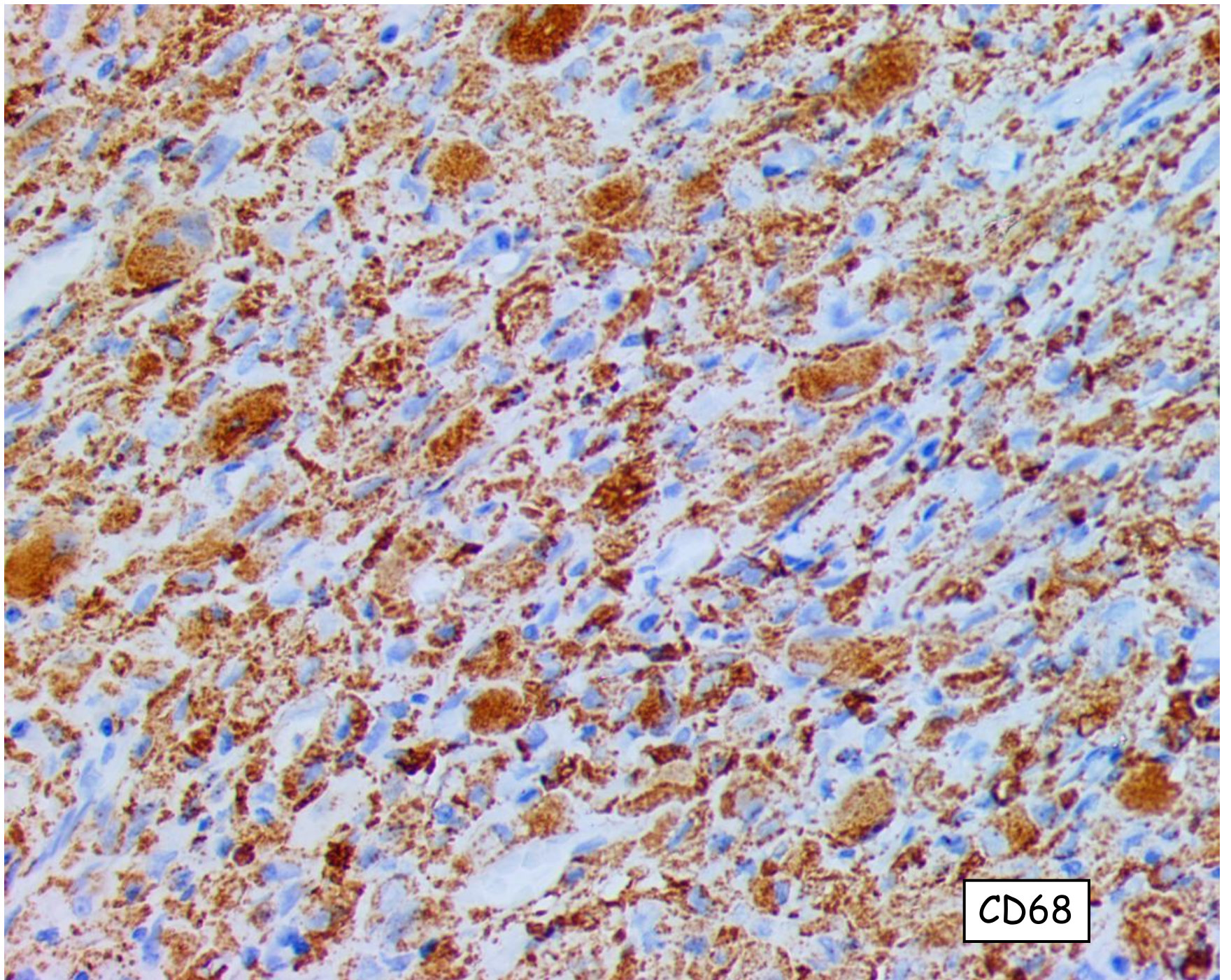




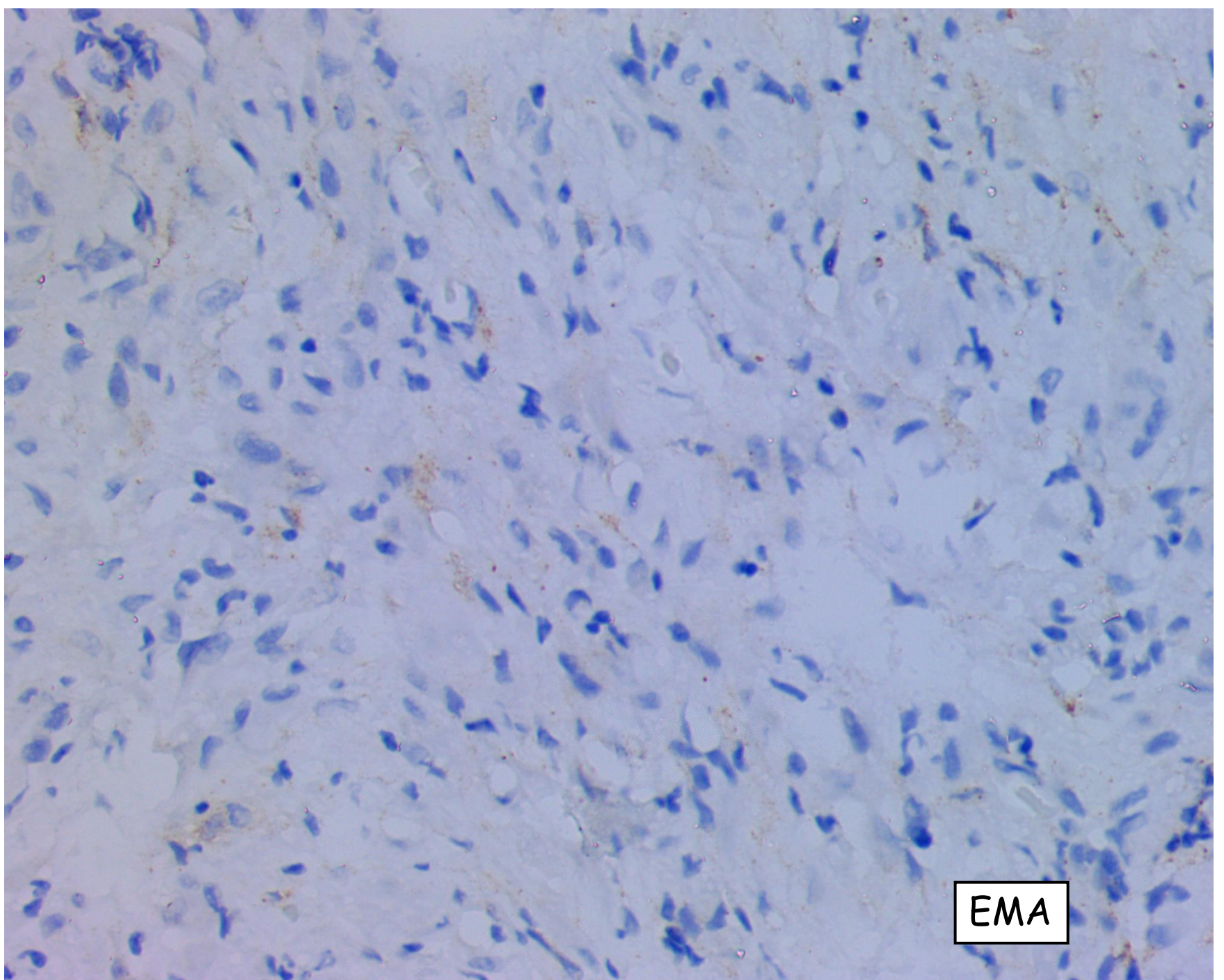
Imuno-histoquímica



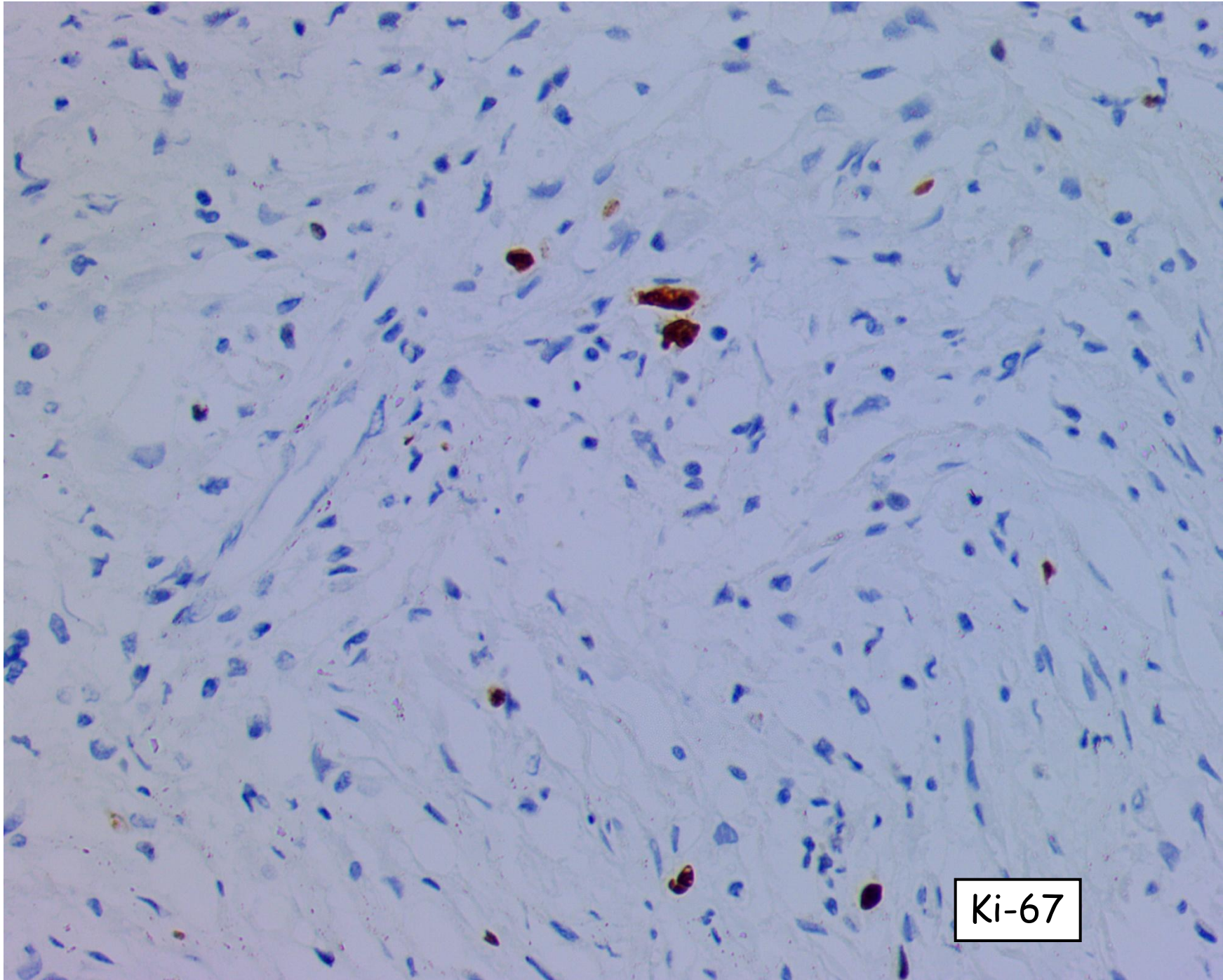
vimentina



CD68



EMA



Ki-67



Sociedade Brasileira de Patologia

**Com base nos achados
morfológicos e
imunohistoquímicos, qual o seu
diagnóstico?**