



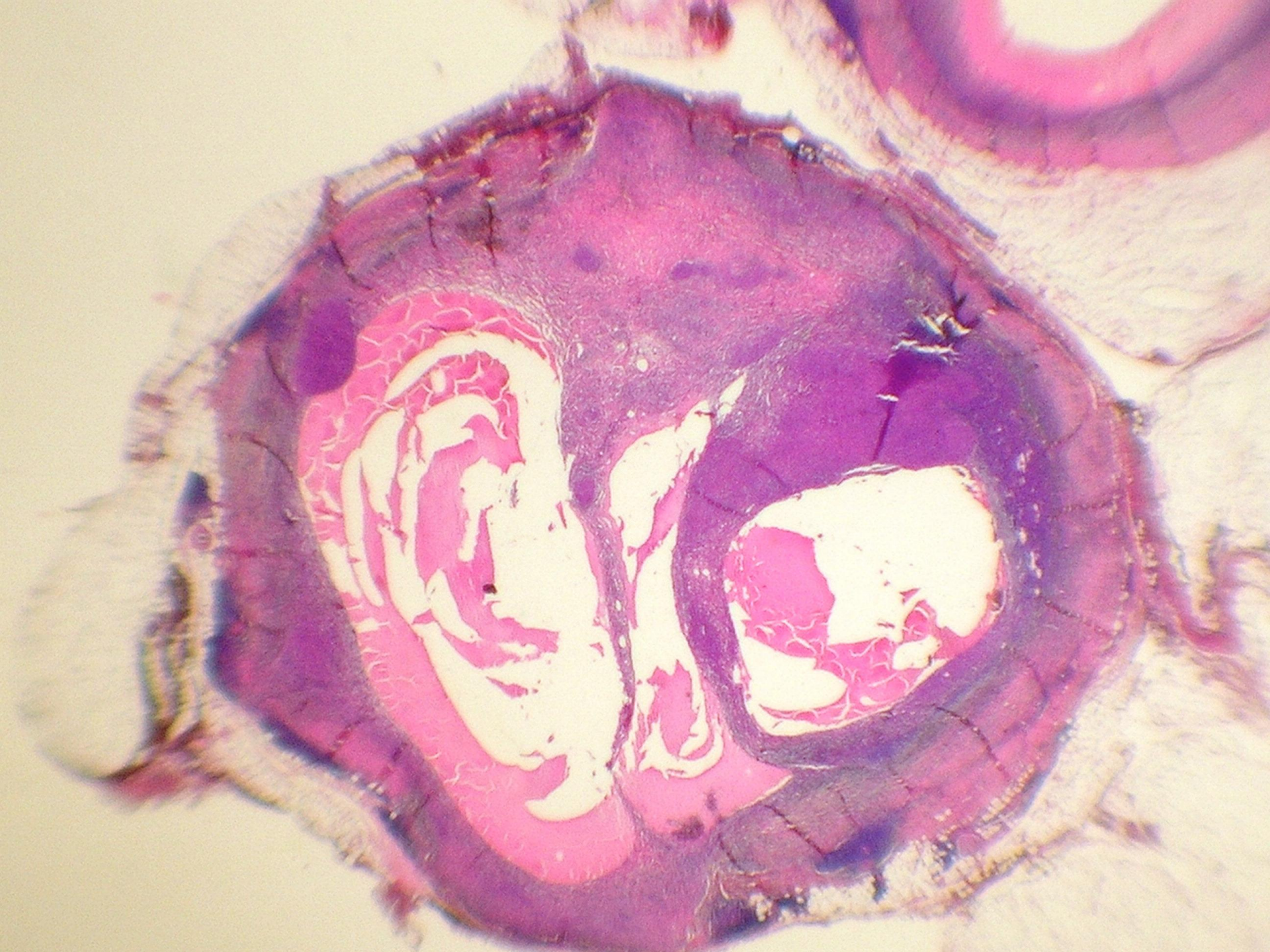
Sociedade Brasileira de Patologia

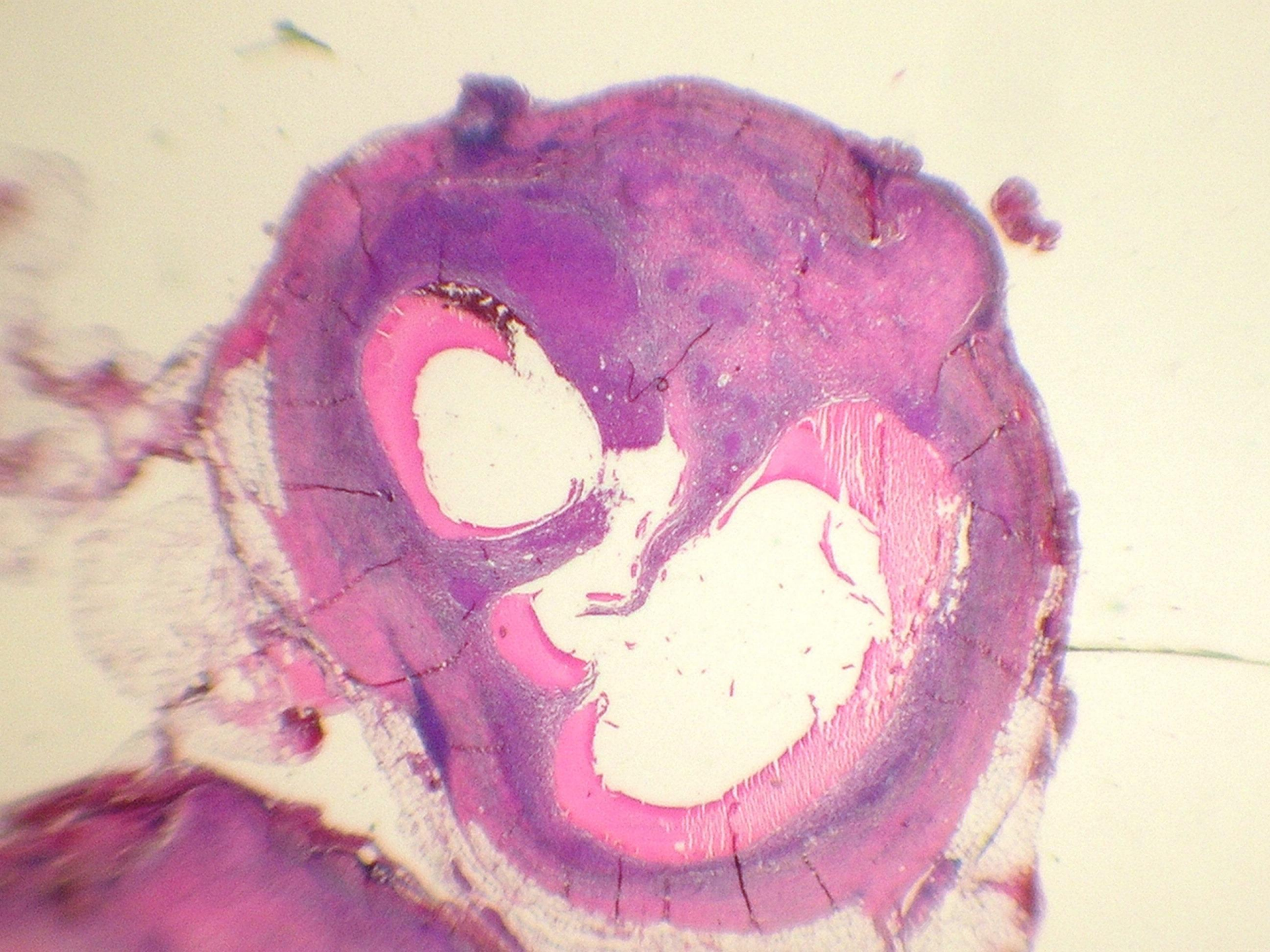

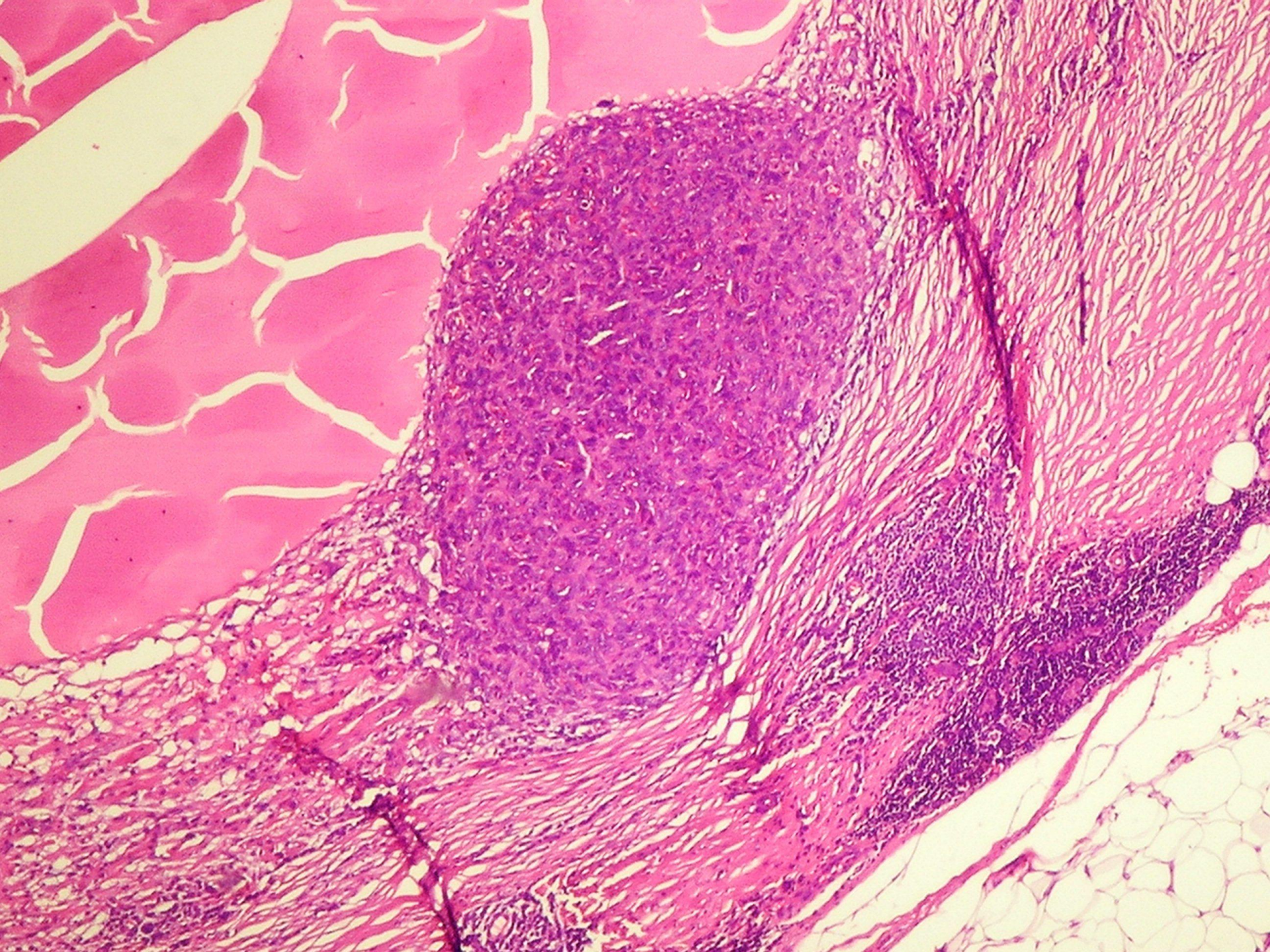
**Prof. Dr. Luiz Carlos da Silva**  
**Faculdade de Medicina de Marília**  
**Hospital de Clínicas de Marília**

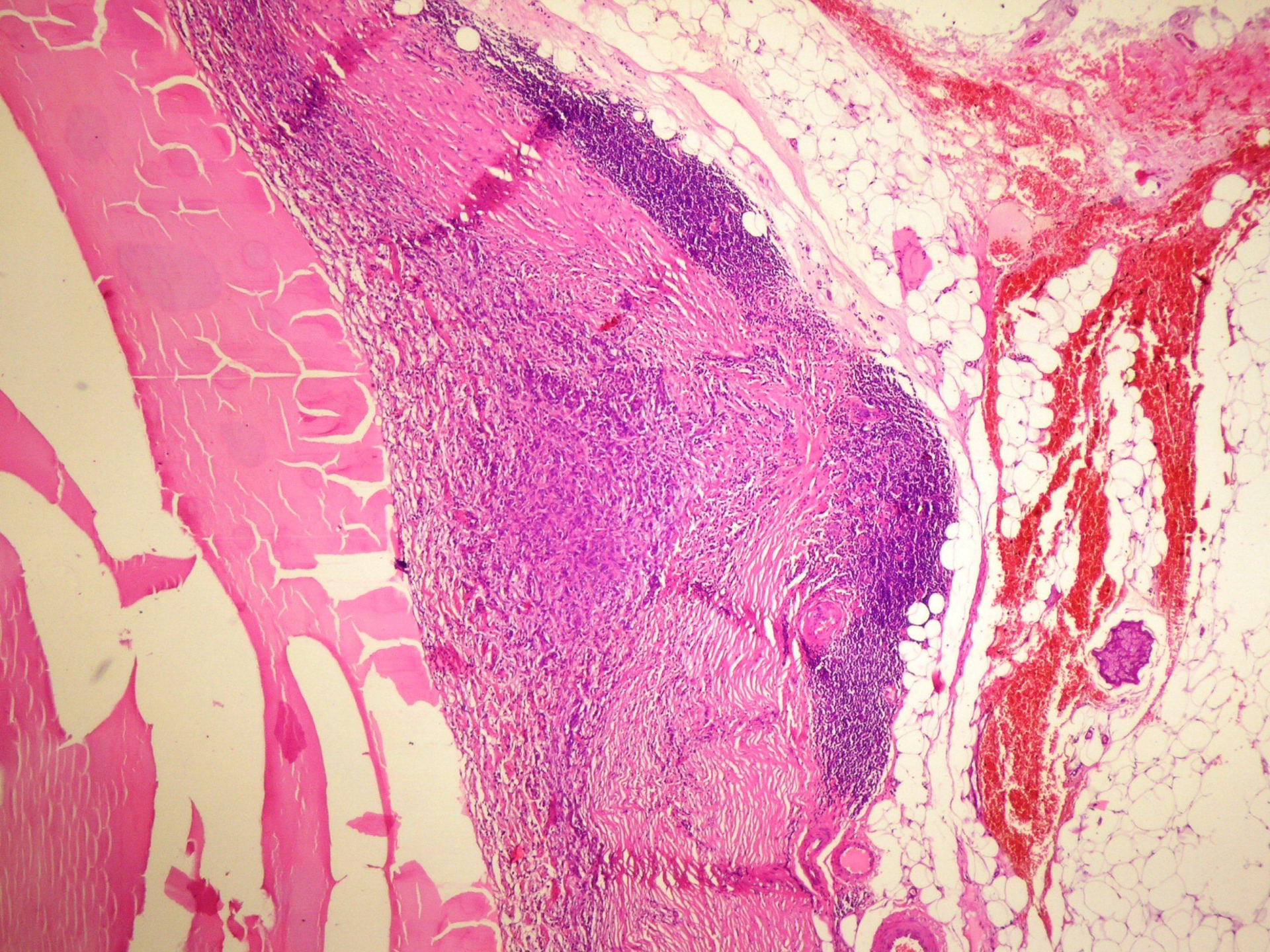
# CASO DE MARÍLIA

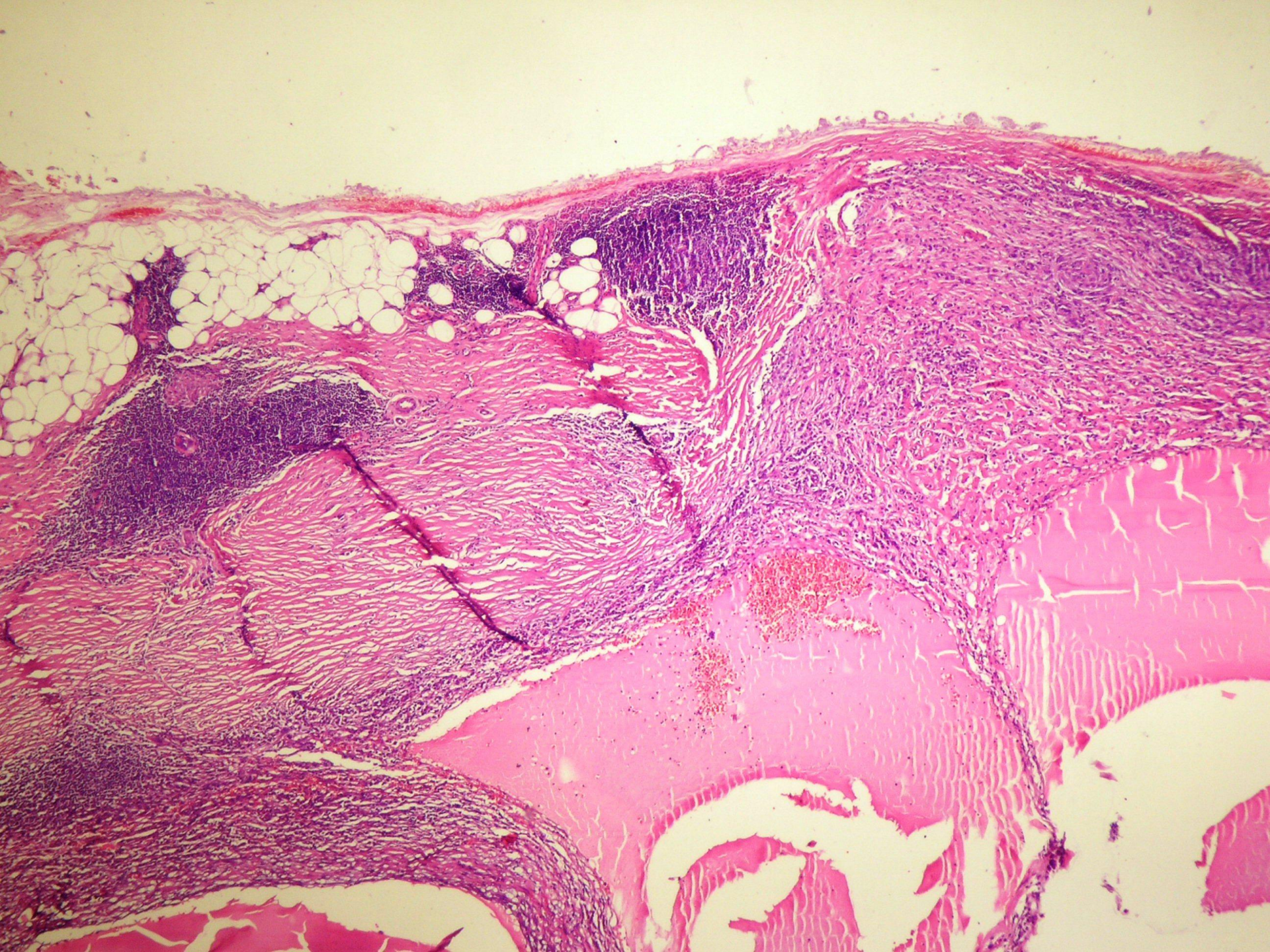
- Mulher de 48 anos com lesão no braço. Neuroma?

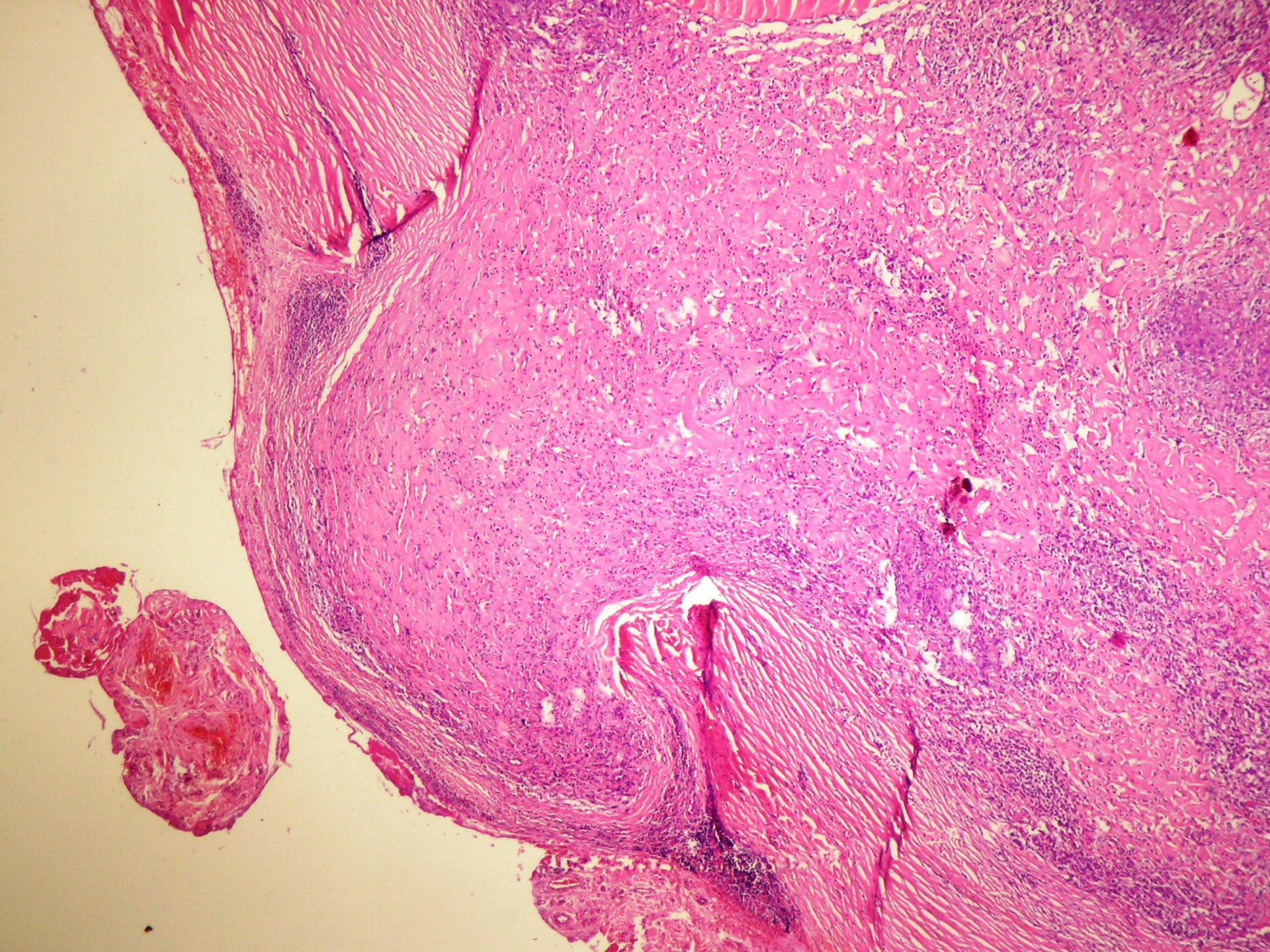




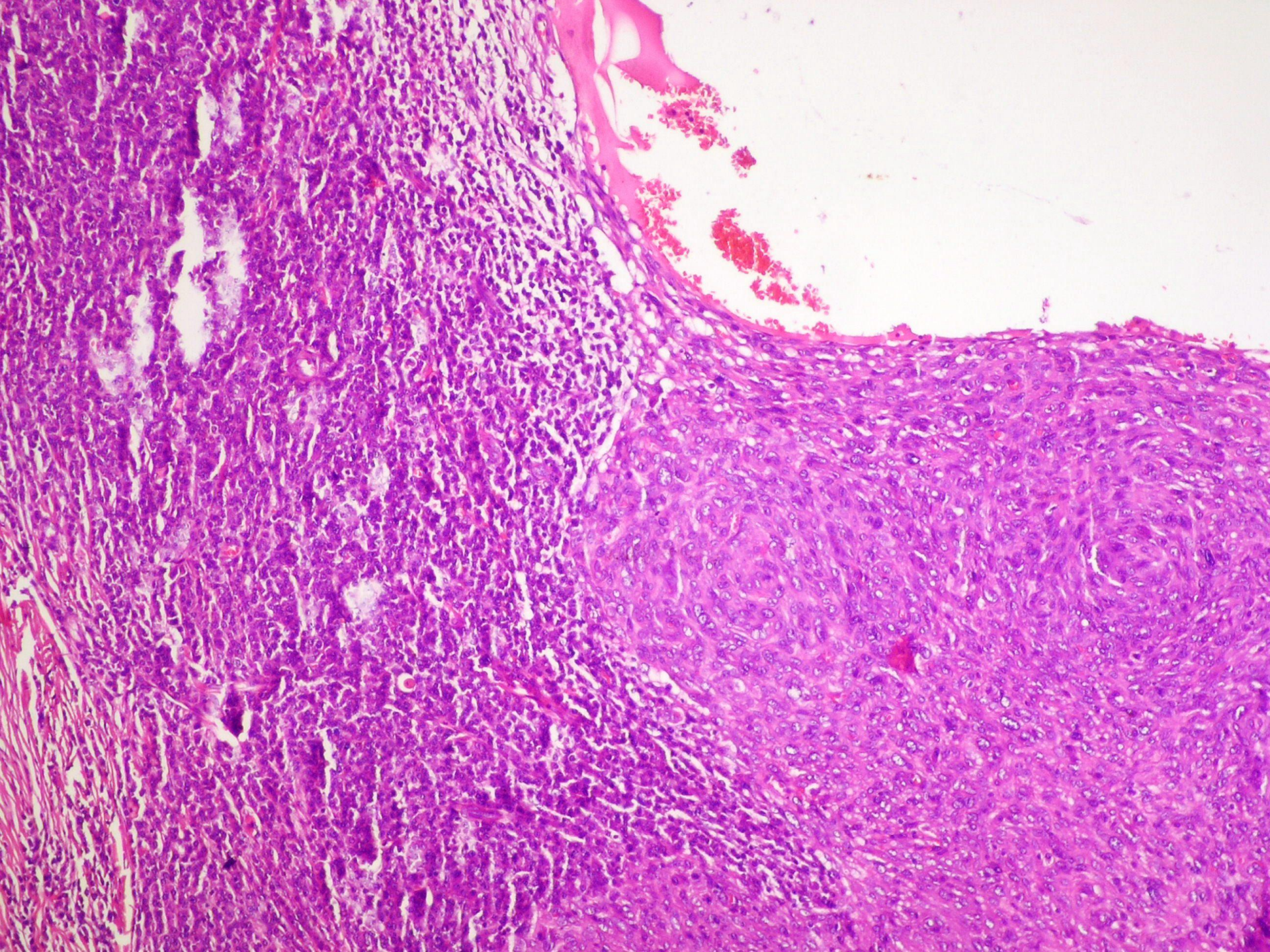


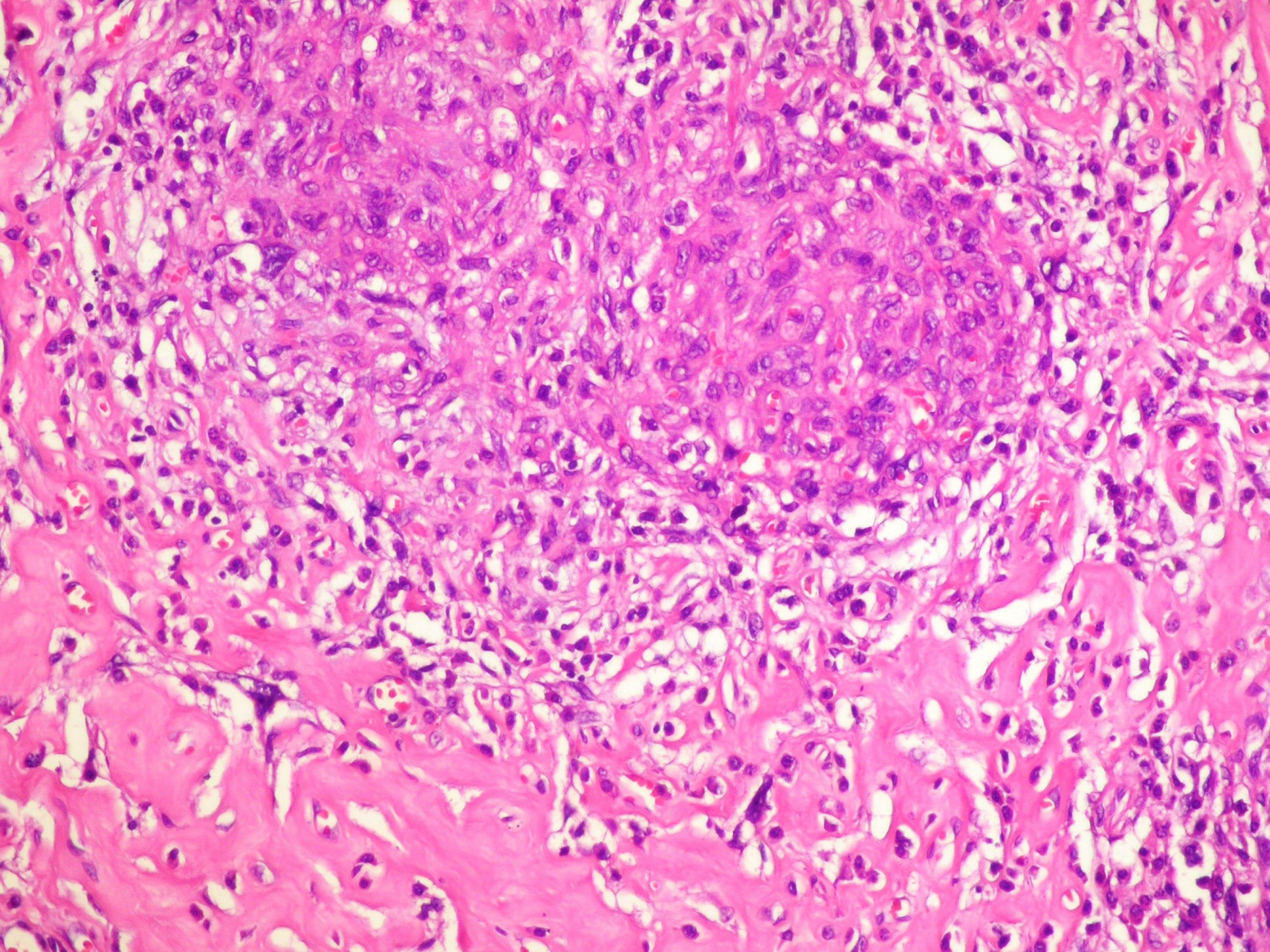


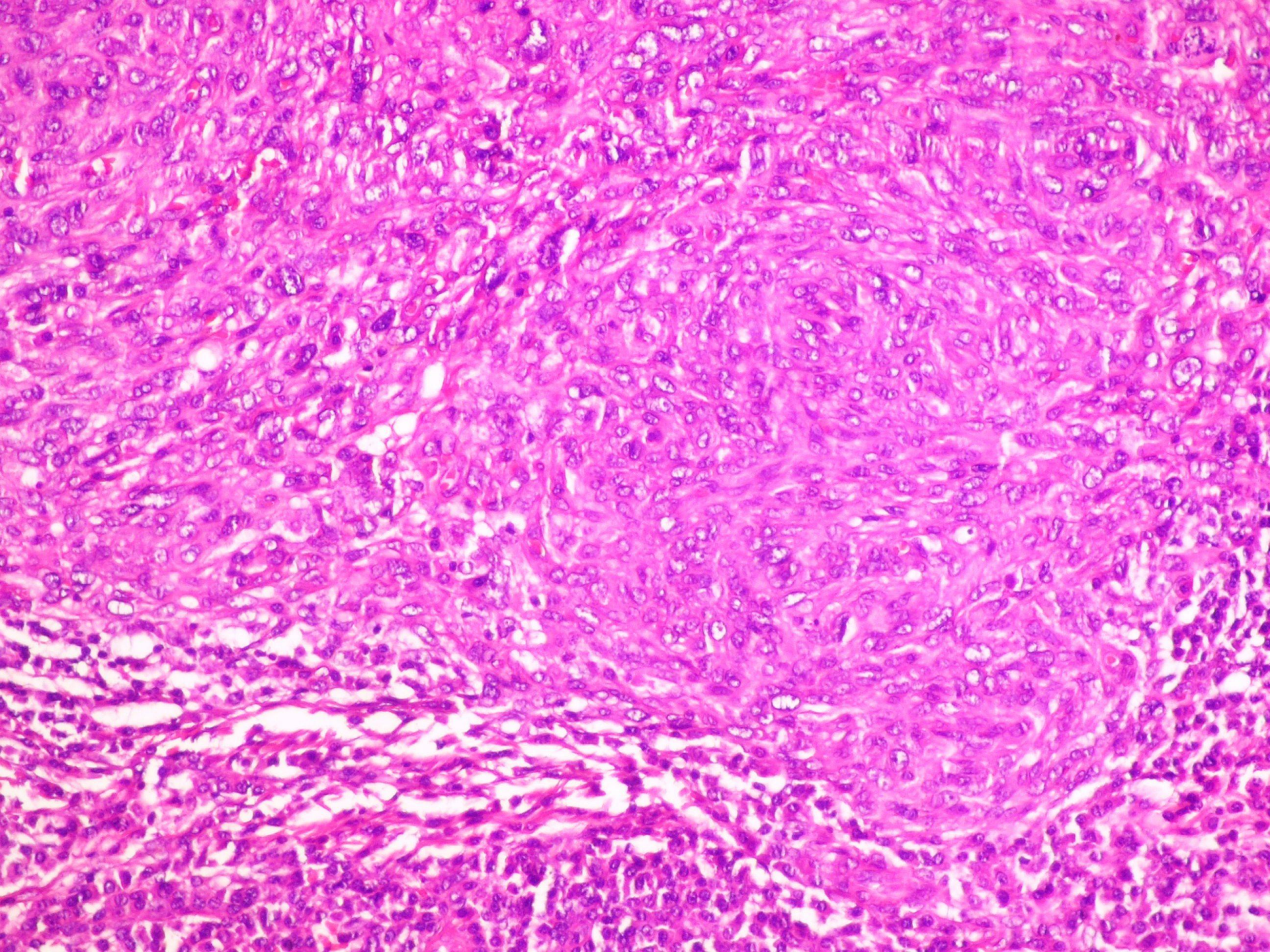


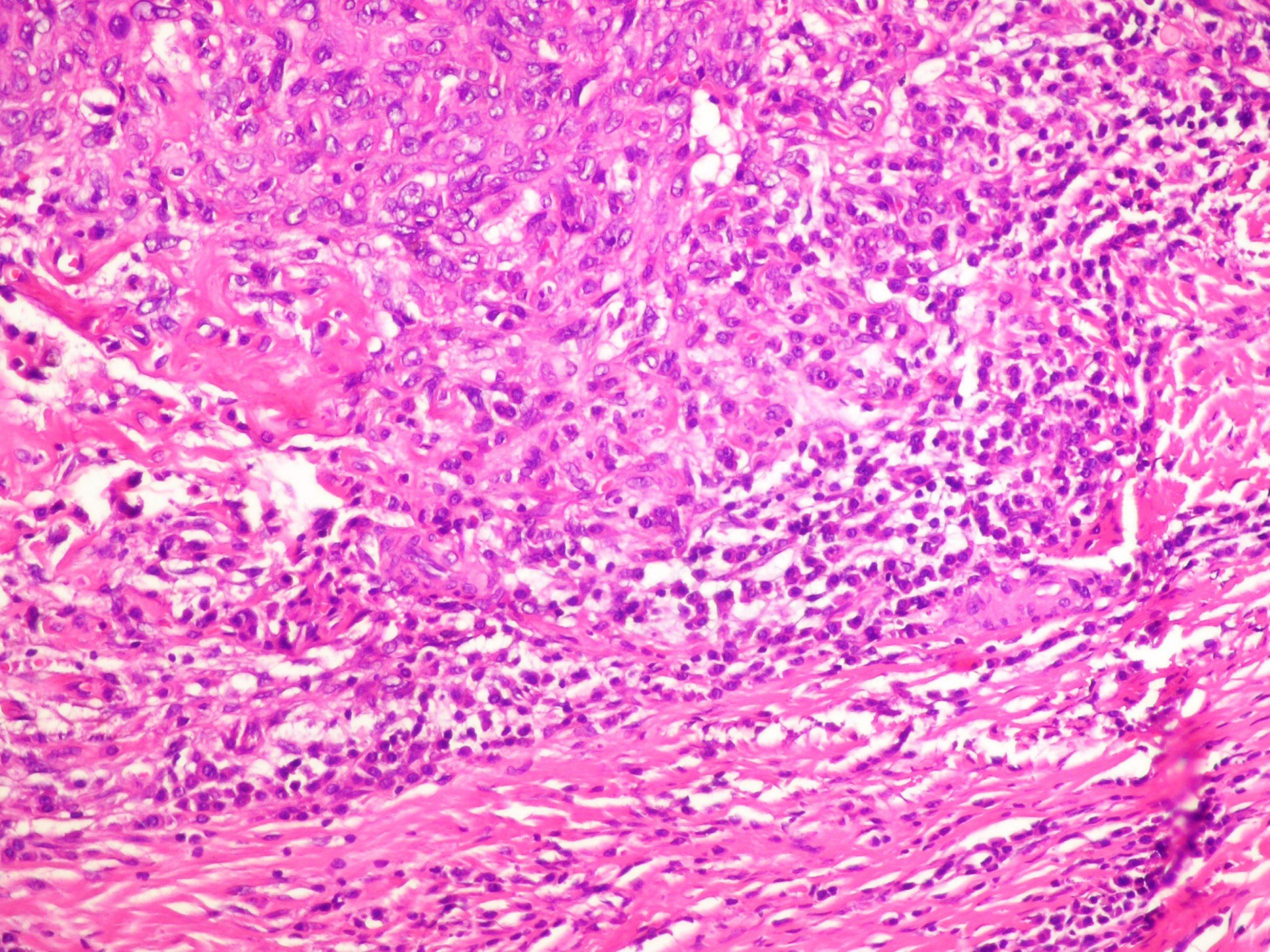


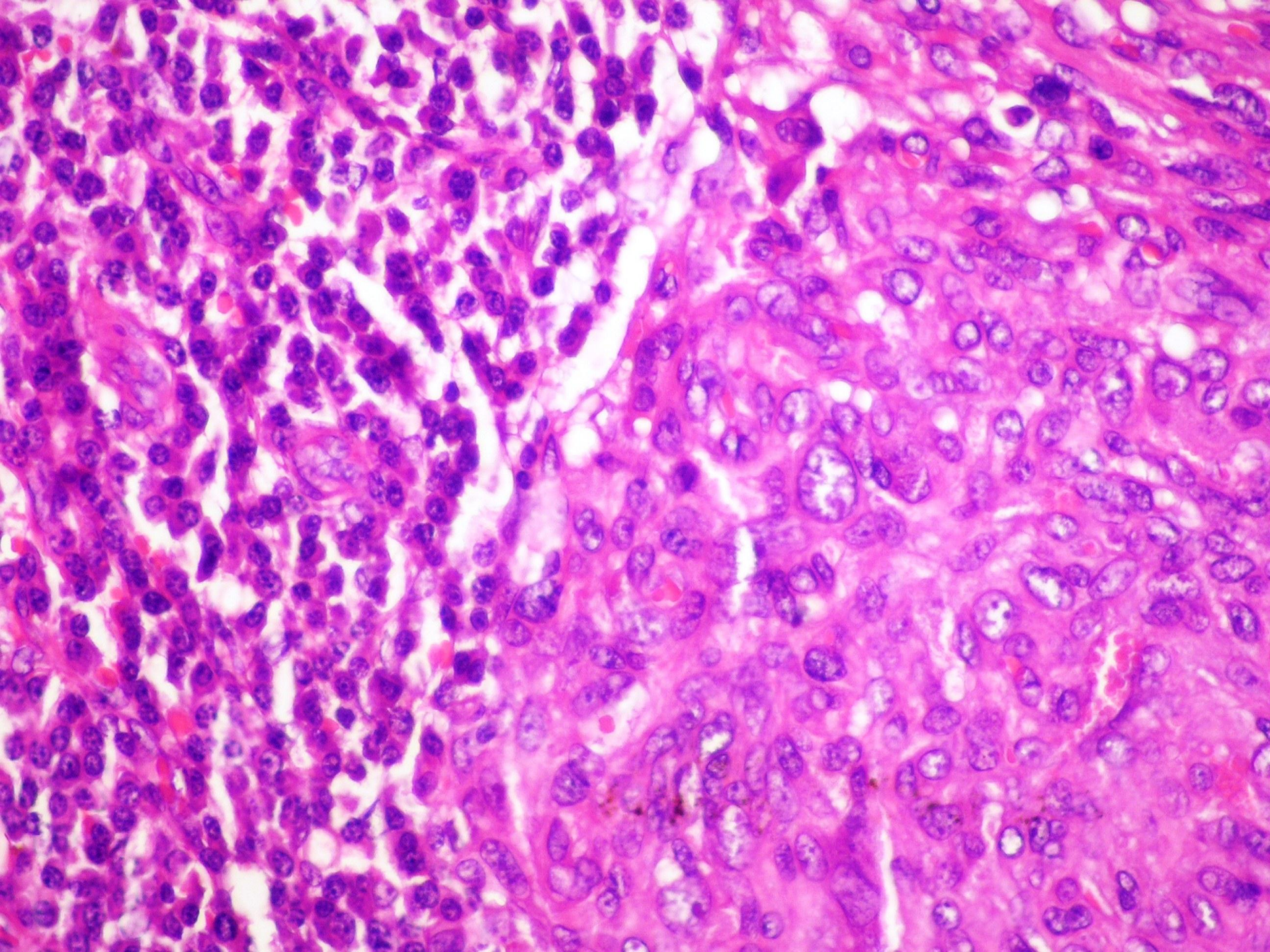


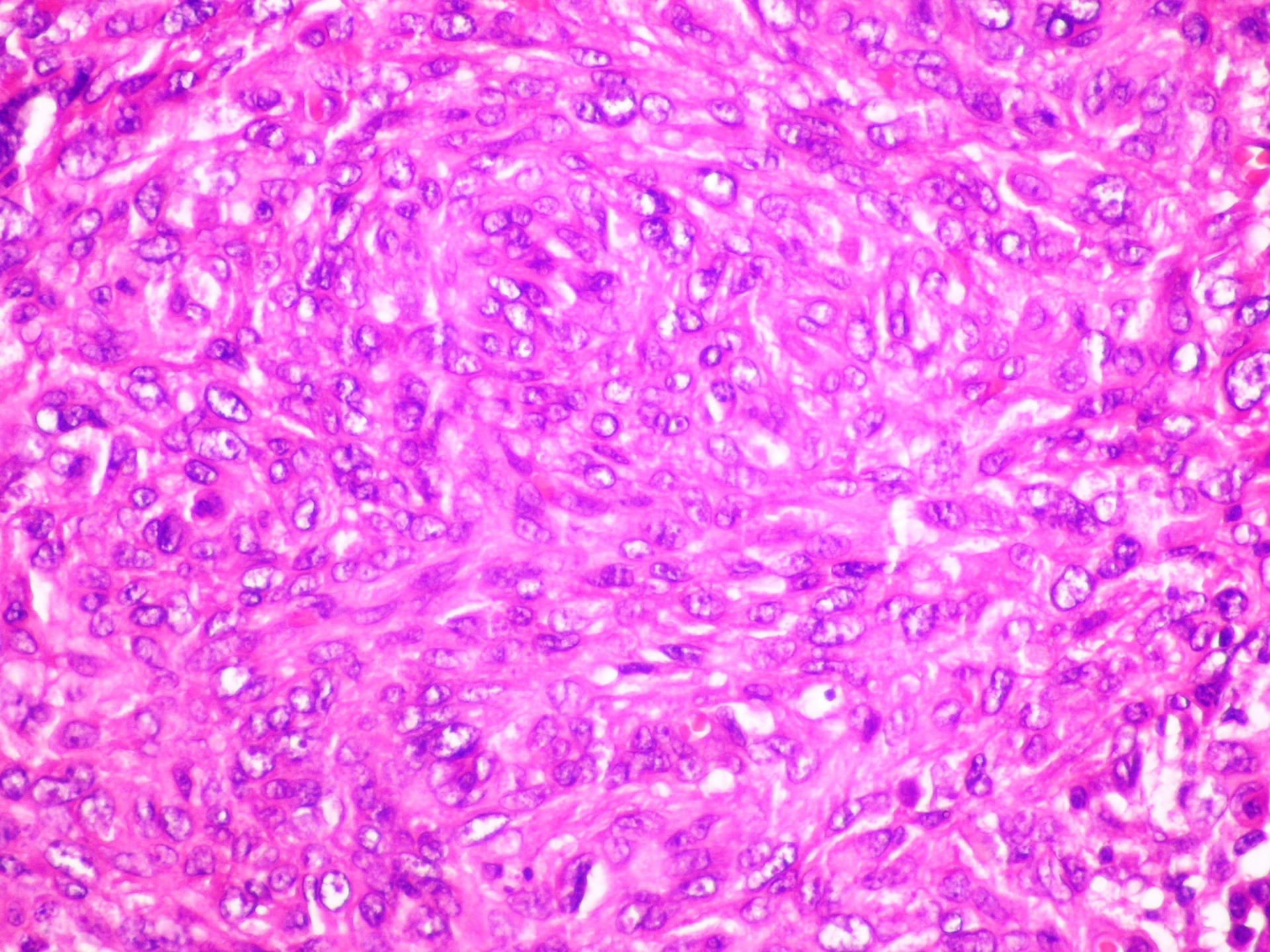


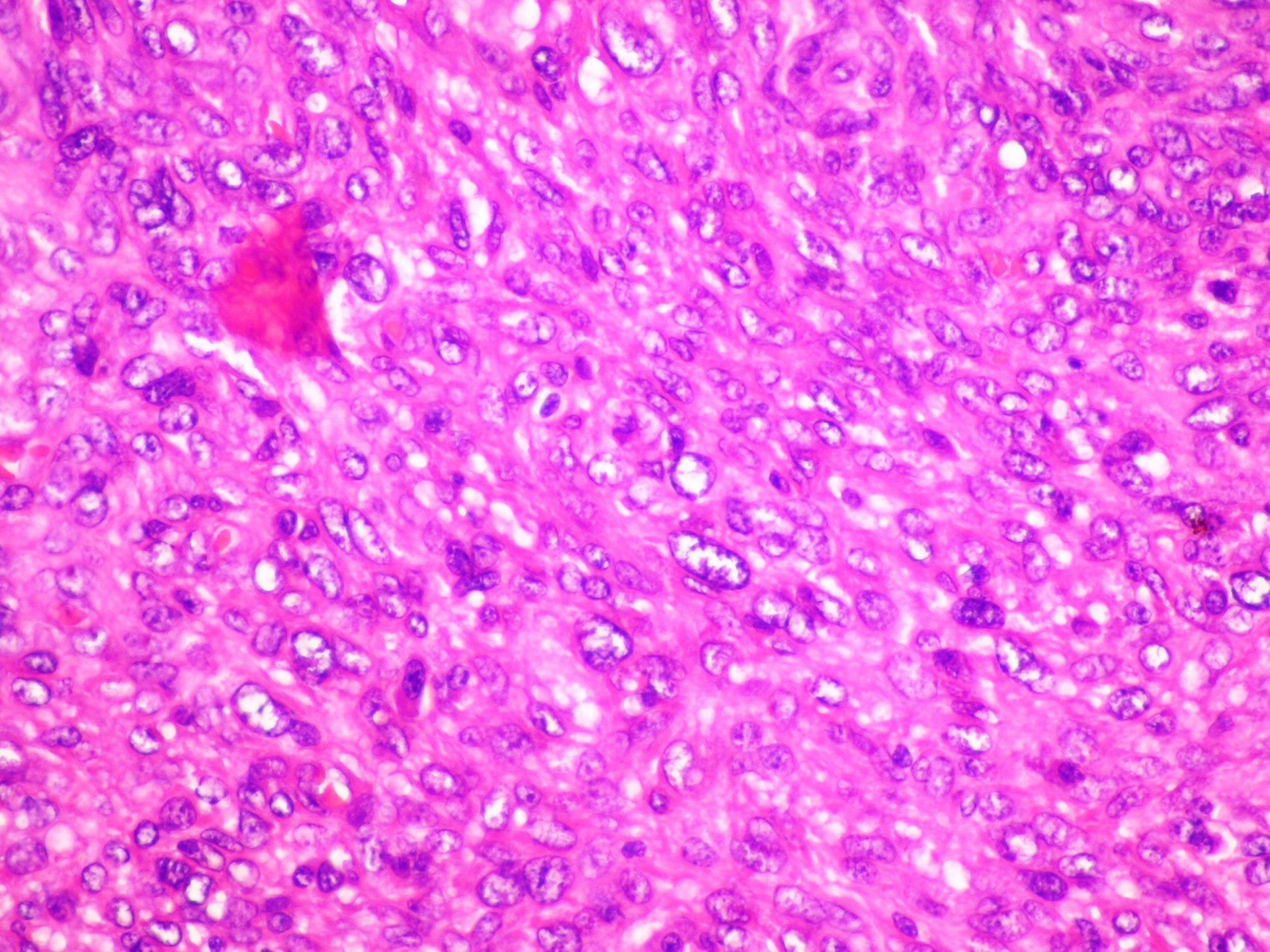


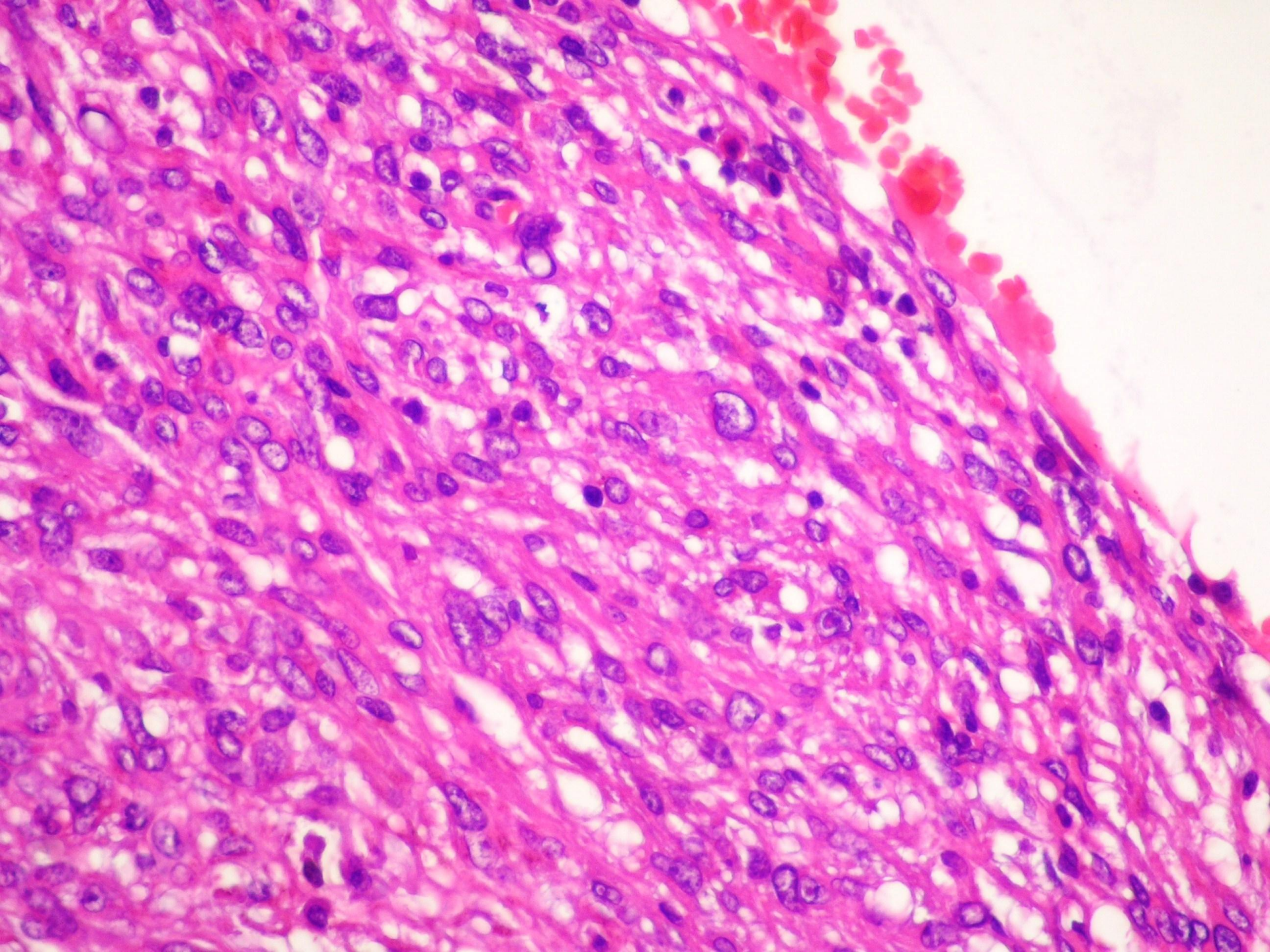




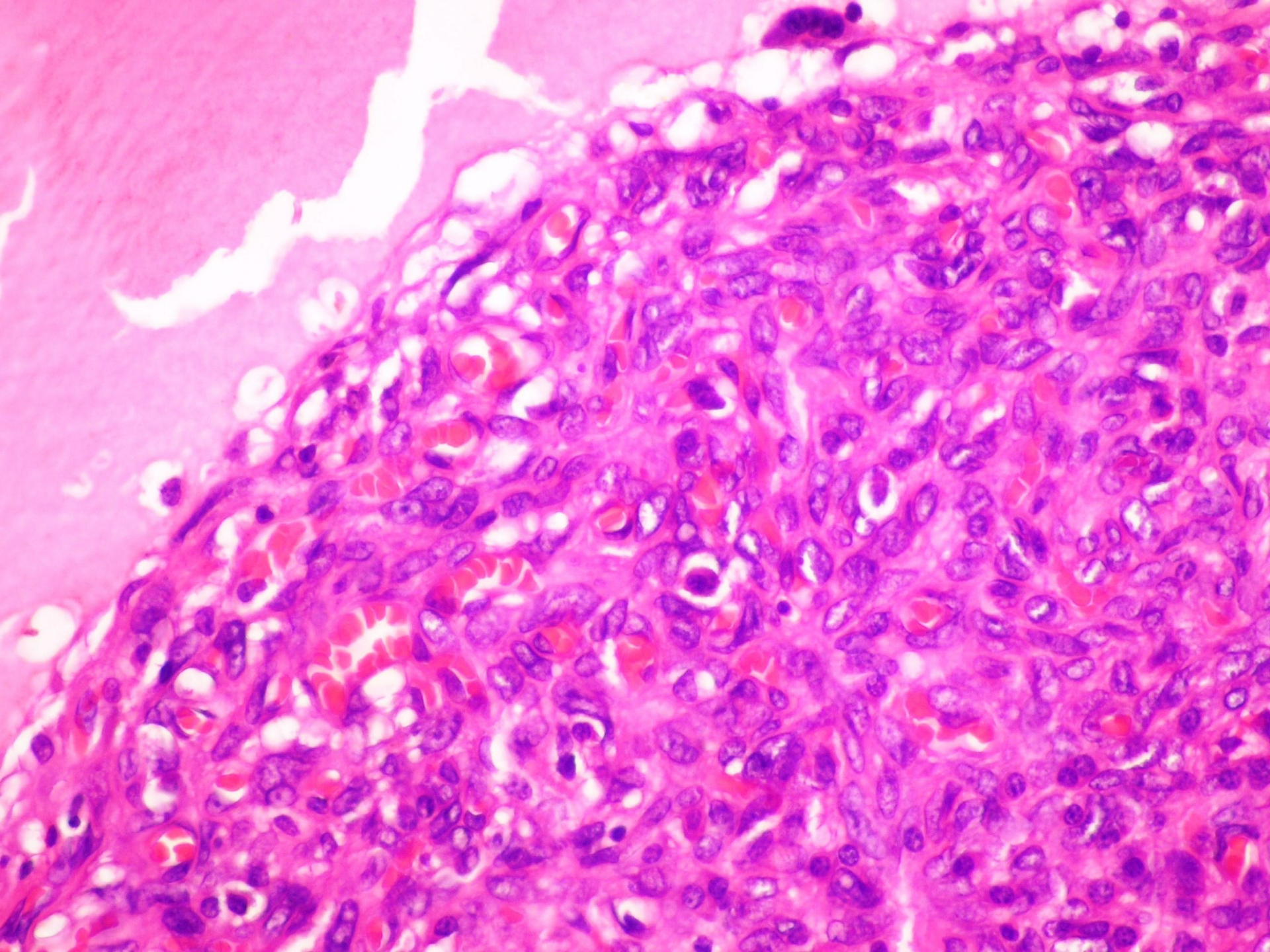












# RESUMO DA MICROSCOPIA:

- 1 – Células tumorais
- 2 – Cavidades hemorrágicas
- 3 – Pseudocápsula fibrosa
- 4 – Infiltrado linfoplasmocitário

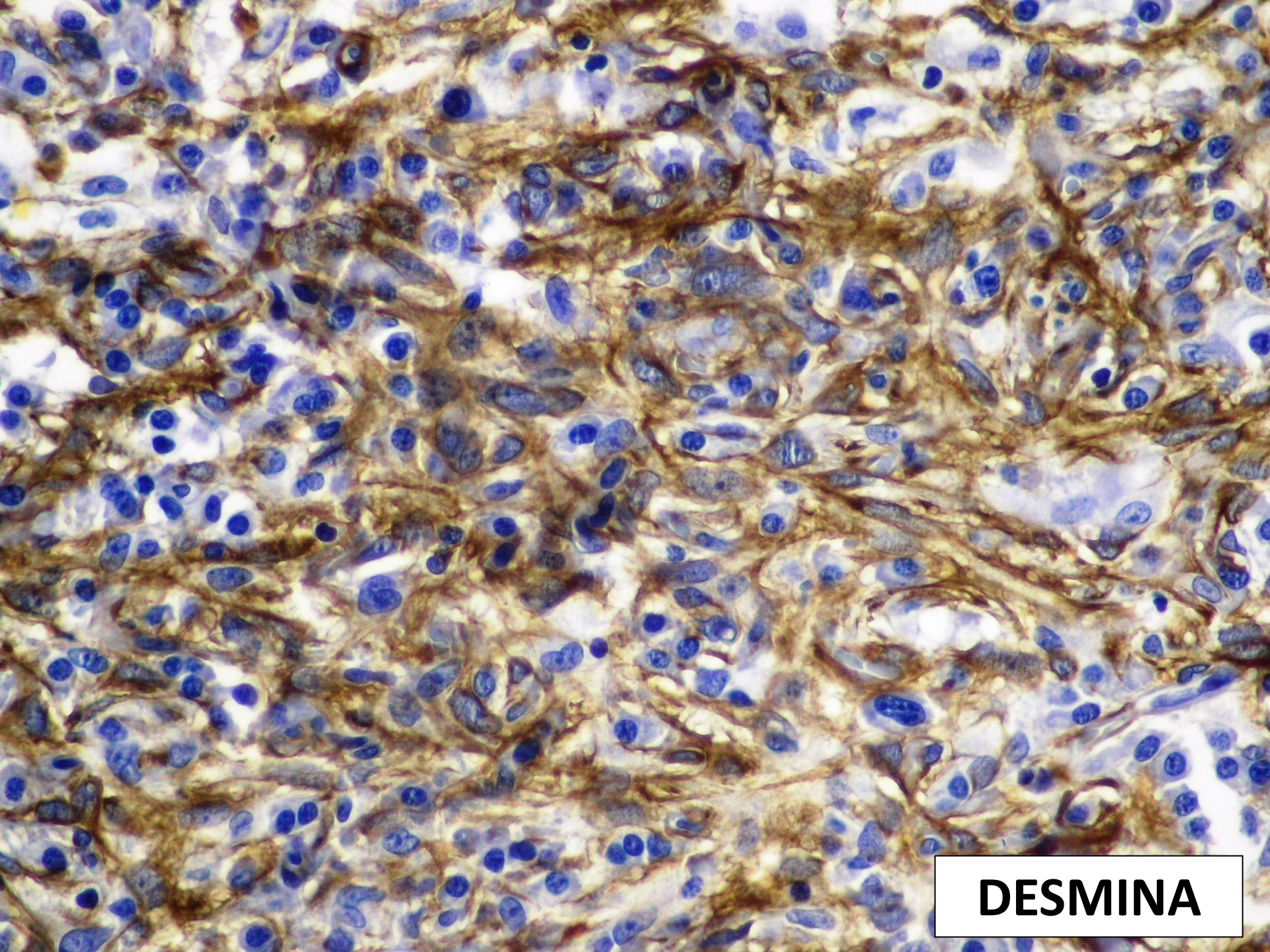


Sociedade Brasileira de Patologia

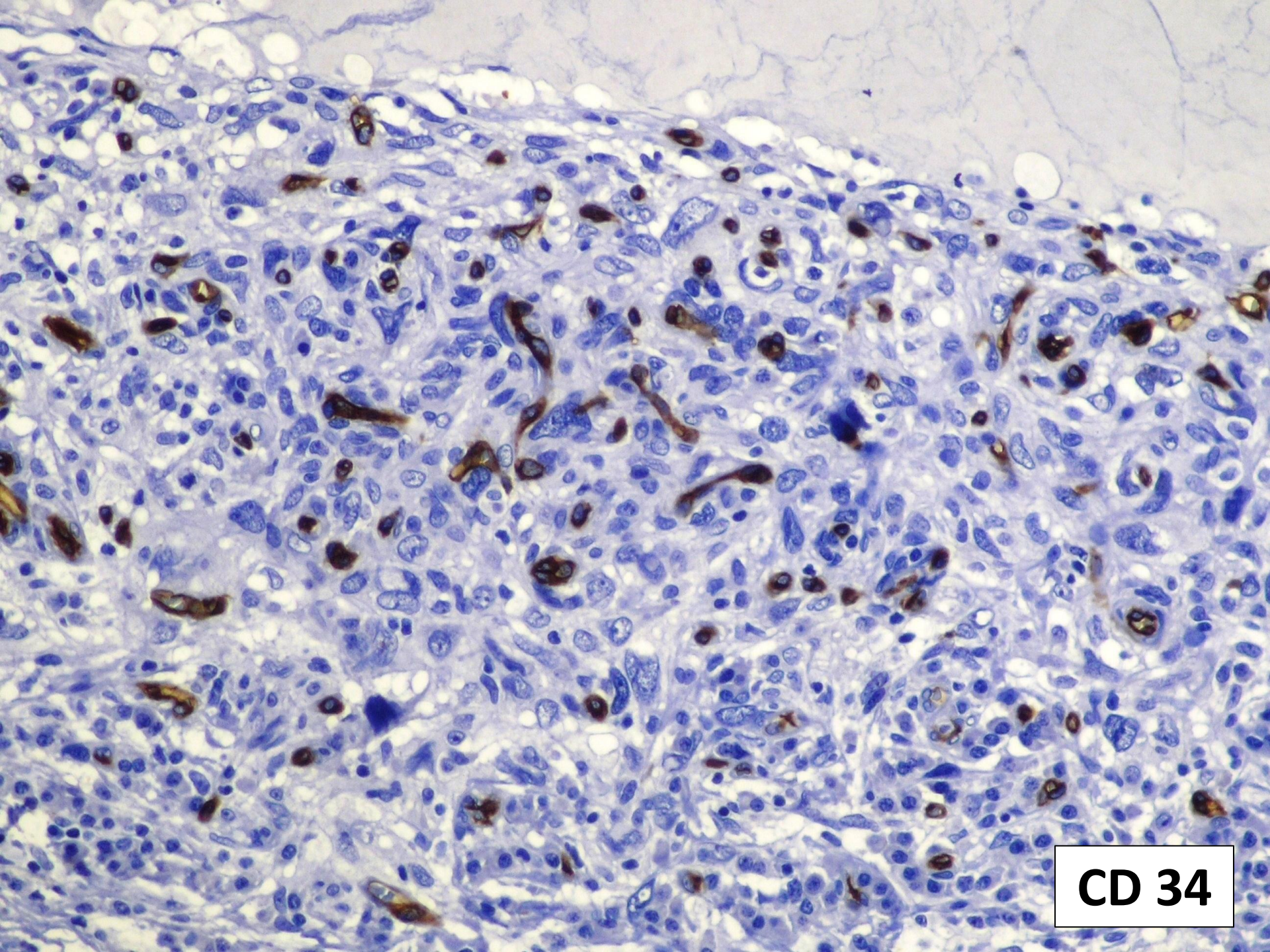
**Com base nos achados  
morfológicos, qual o seu  
diagnóstico?**



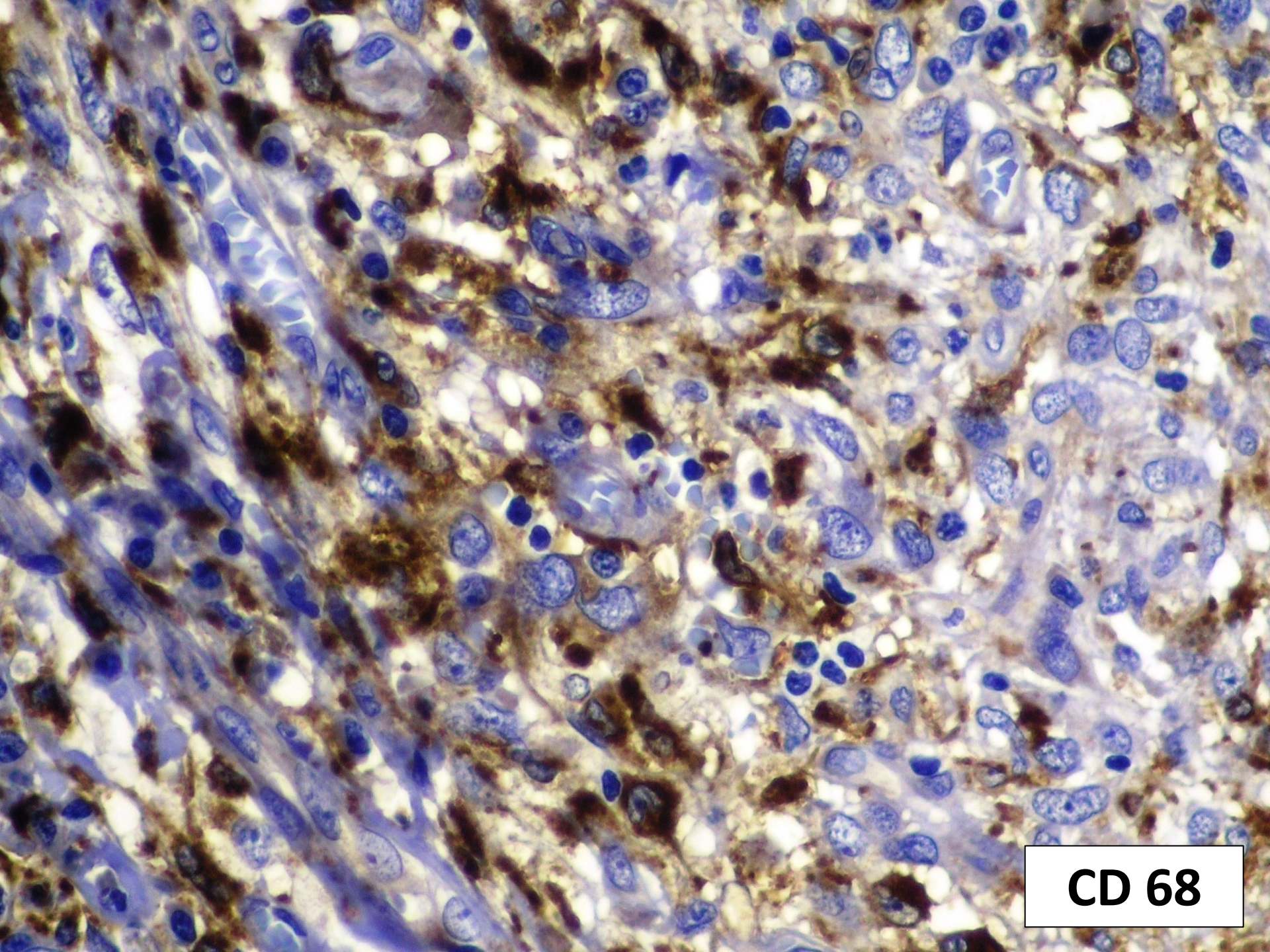
# ESTUDO IMUNOISTOQUÍMICO



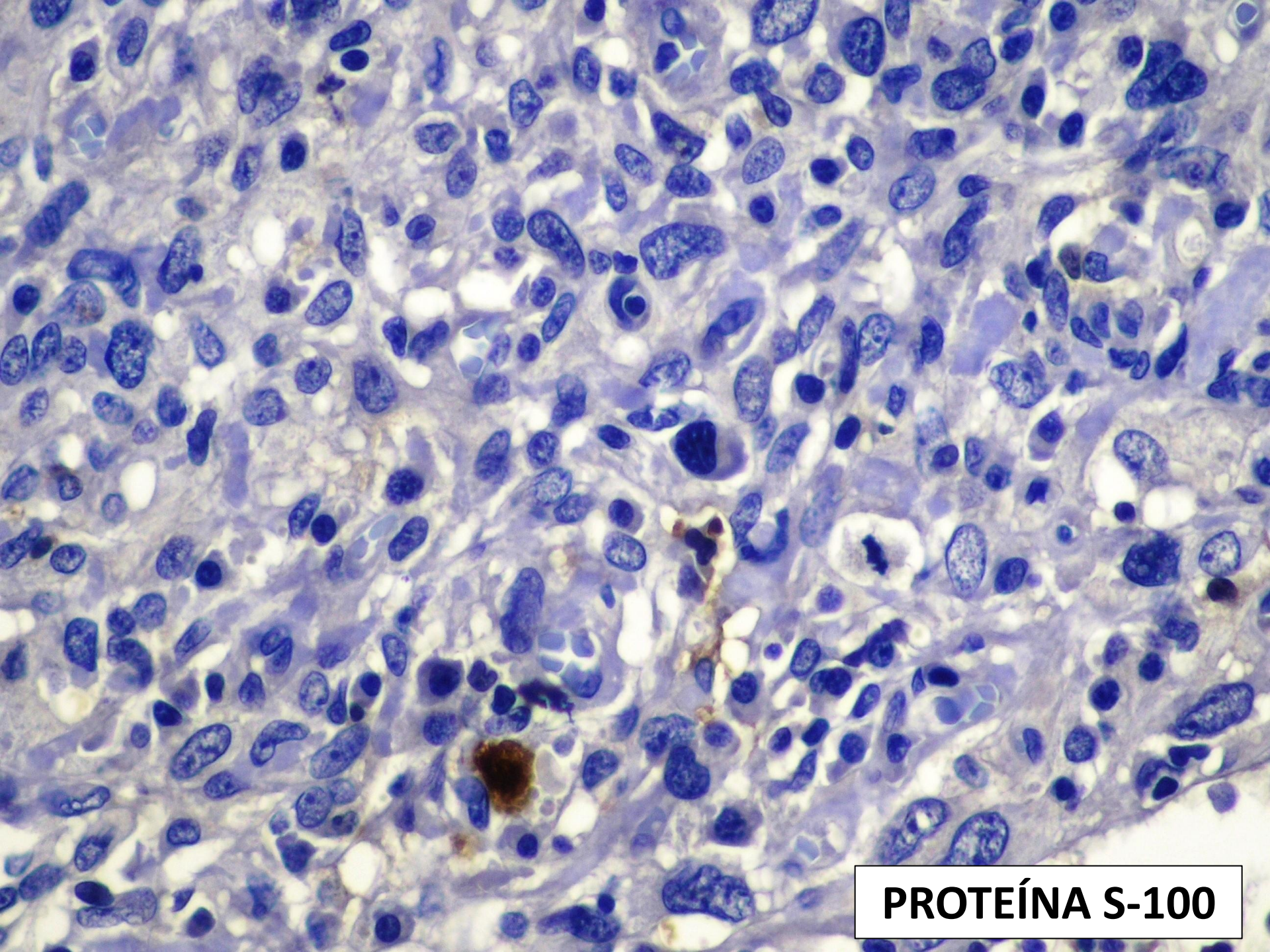
**DESMINA**



**CD 34**

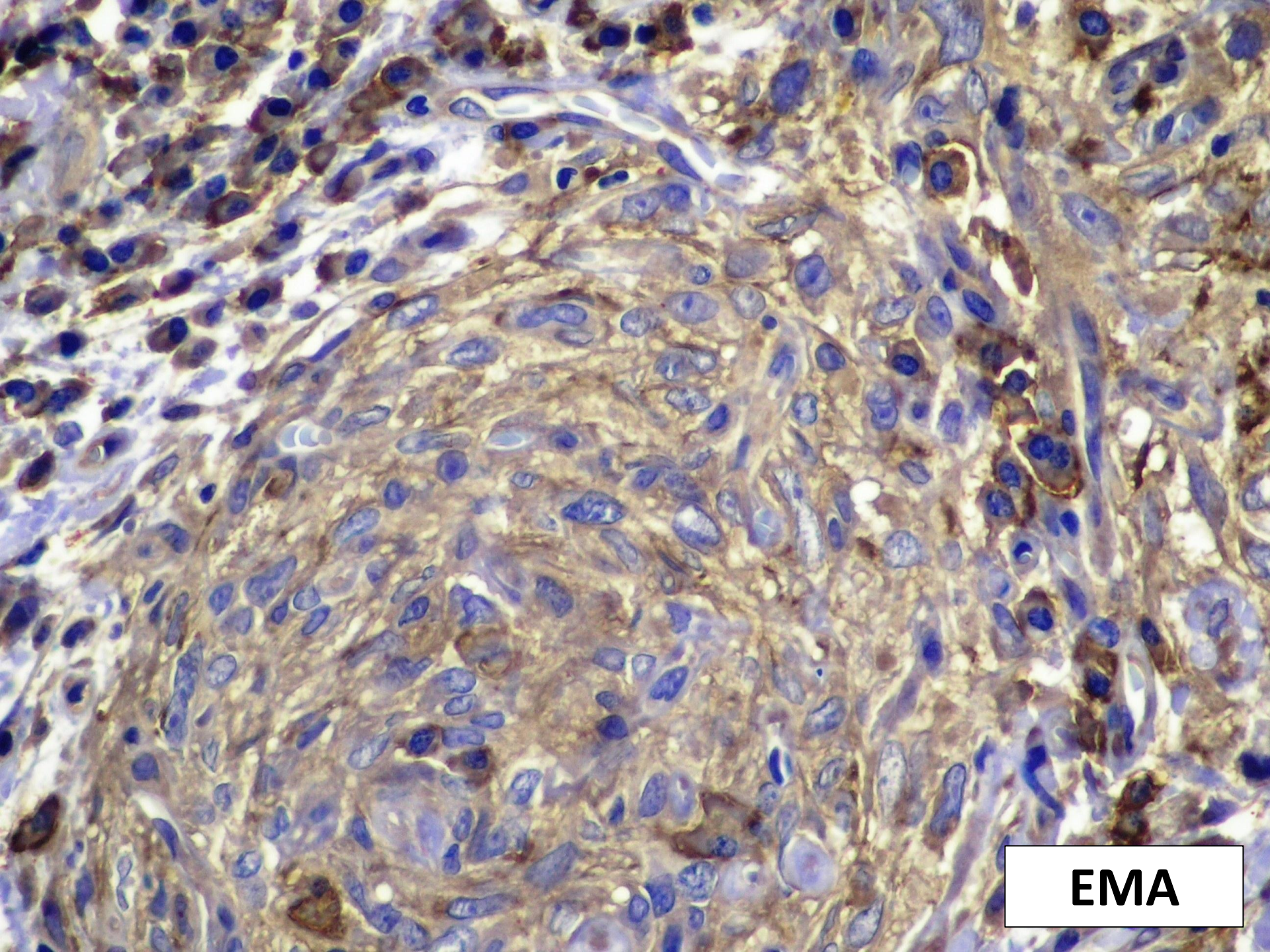


**CD 68**

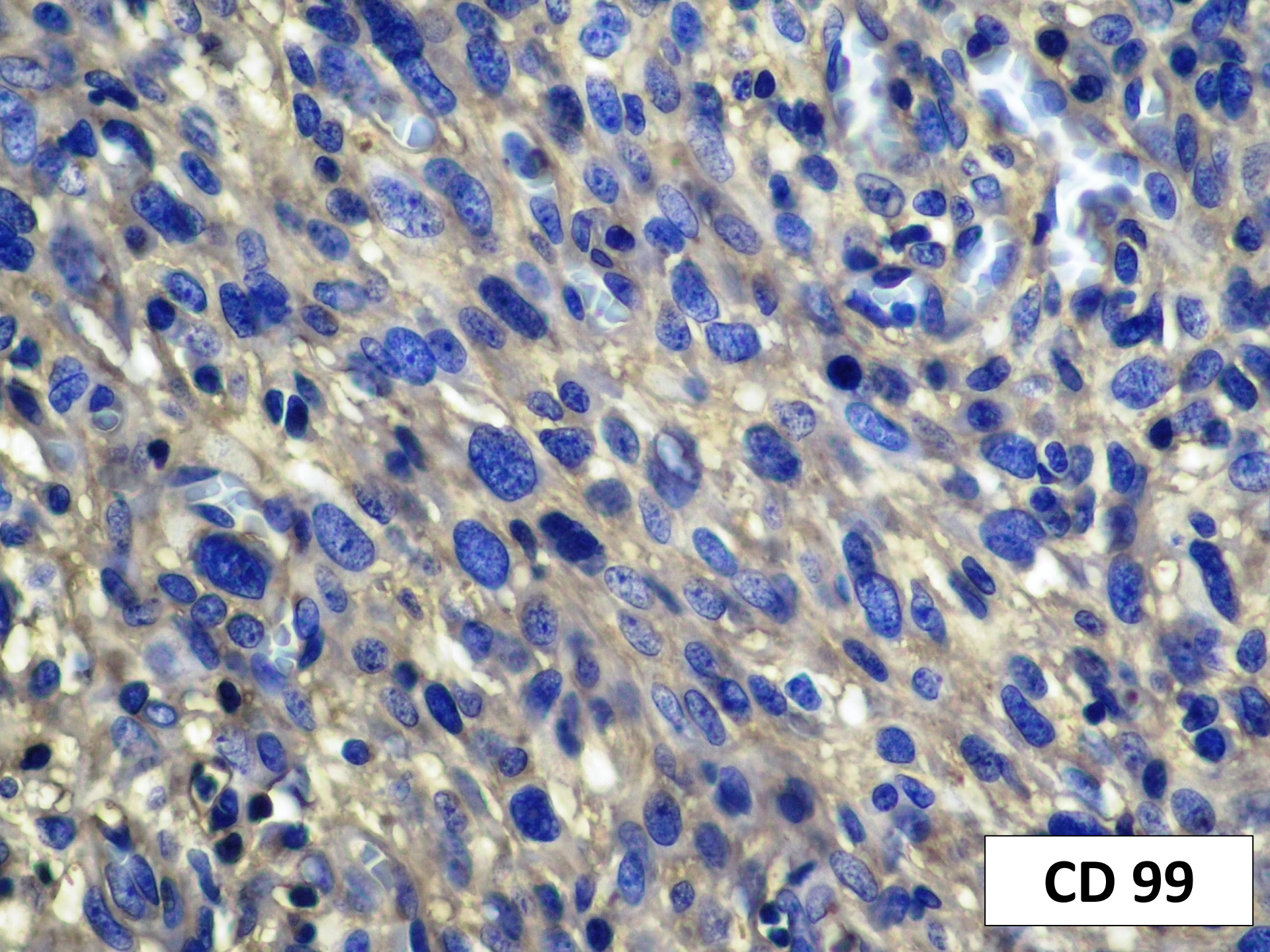


**PROTEÍNA S-100**

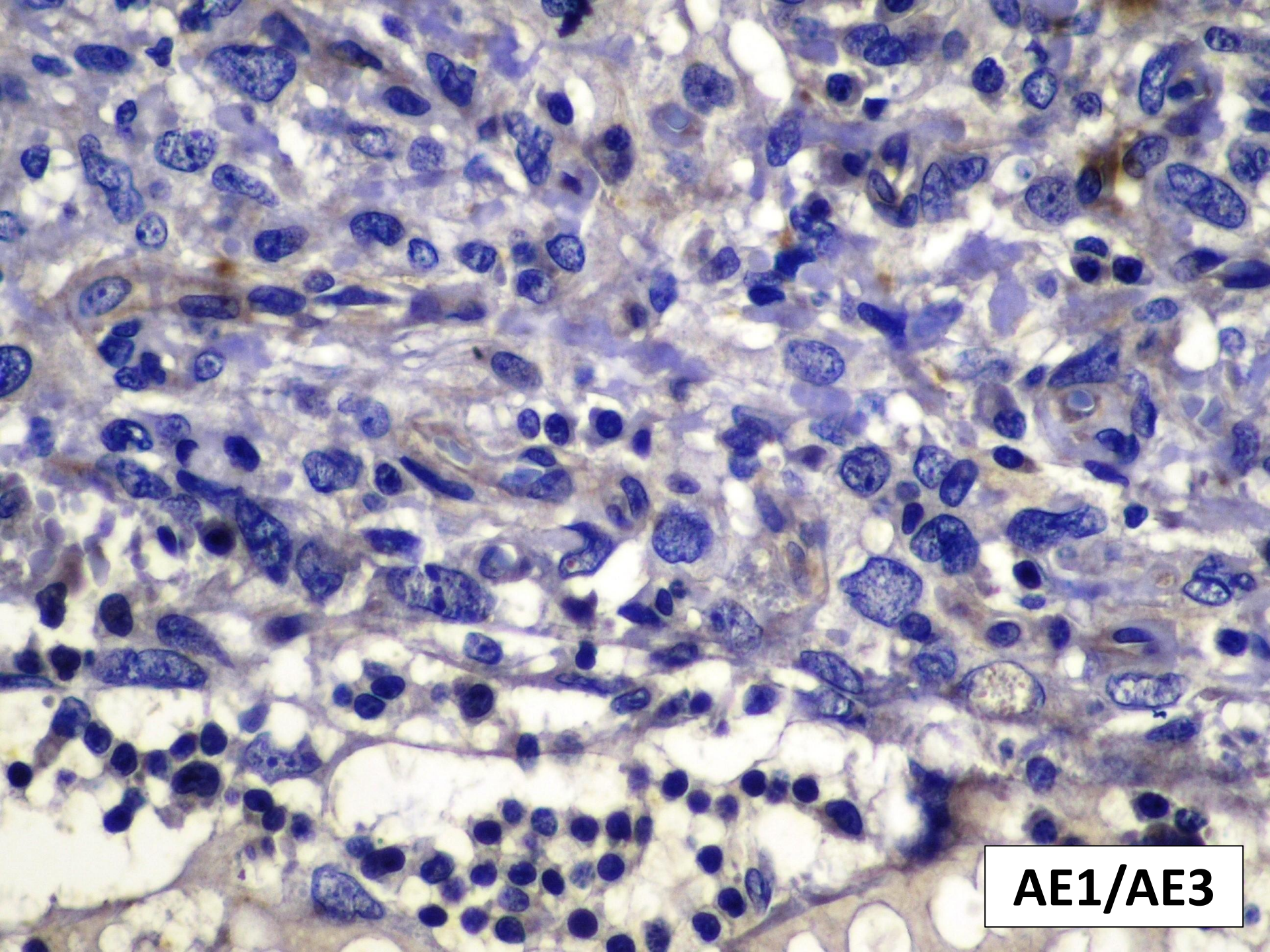




**EMA**



**CD 99**



**AE1/AE3**

# SUMÁRIO DA IMUNO-HISTOQUÍMICA

- Marcadores positivos
  - Desmina
  - EMA
  - CD-68
  - CD-99

# SUMÁRIO DA IMUNO-HISTOQUÍMICA

- Marcadores negativos
  - Musculares
  - Citoqueratinas
  - Proteína S-100
  - Vasculares
  - HMB - 45

DIAGNÓSTICO DEFINITIVO:

FIBROHISTIOCITOMA  
ANGIOMATOIDE

# CITOGENÉTICA

- - t(2:22) (q 33:q12) – EWSR 1 – CREB 1
- - t(12:16) (q13:p11) – FUS – ATF 1
- - t(12:22) (q13:q12) – EWSR 1 – ATF 1

# FATORES PROGNÓSTICOS

- - Comportamento indolente
- - Recidiva local (10-15%)
- - Metástase (- 1%)
- - Mortalidade rara



# REFERÊNCIAS BIBLIOGRÁFICAS

- Enzinger & Weiss's. Soft Tissue Tumors. In: Fibrohistiocytic tumors of intermediate malignancy. Chapter 12. p.404-405; 410-411. 2014.
- Fletcher, CDM et al. World Health Organization Classification of Tumours. Pathology and Genetics of Tumours of Soft Tissue and Bone. In: Fanburg-Schmidt, JC; Dal Clin, P. Angiomatoid fibrous histiocytoma. p.194-195. 2002.
- Fischer C. et al. Soft Tissue Tumors. In: Lesions uncertain differentiation. Angiomatoid Fibrous Histiocytoma. section. 15, p.24-29. 2011.