

Caso do mês

Março de 2016 - 1

Mônica N Moura

Sérgio de Oliveira Romano

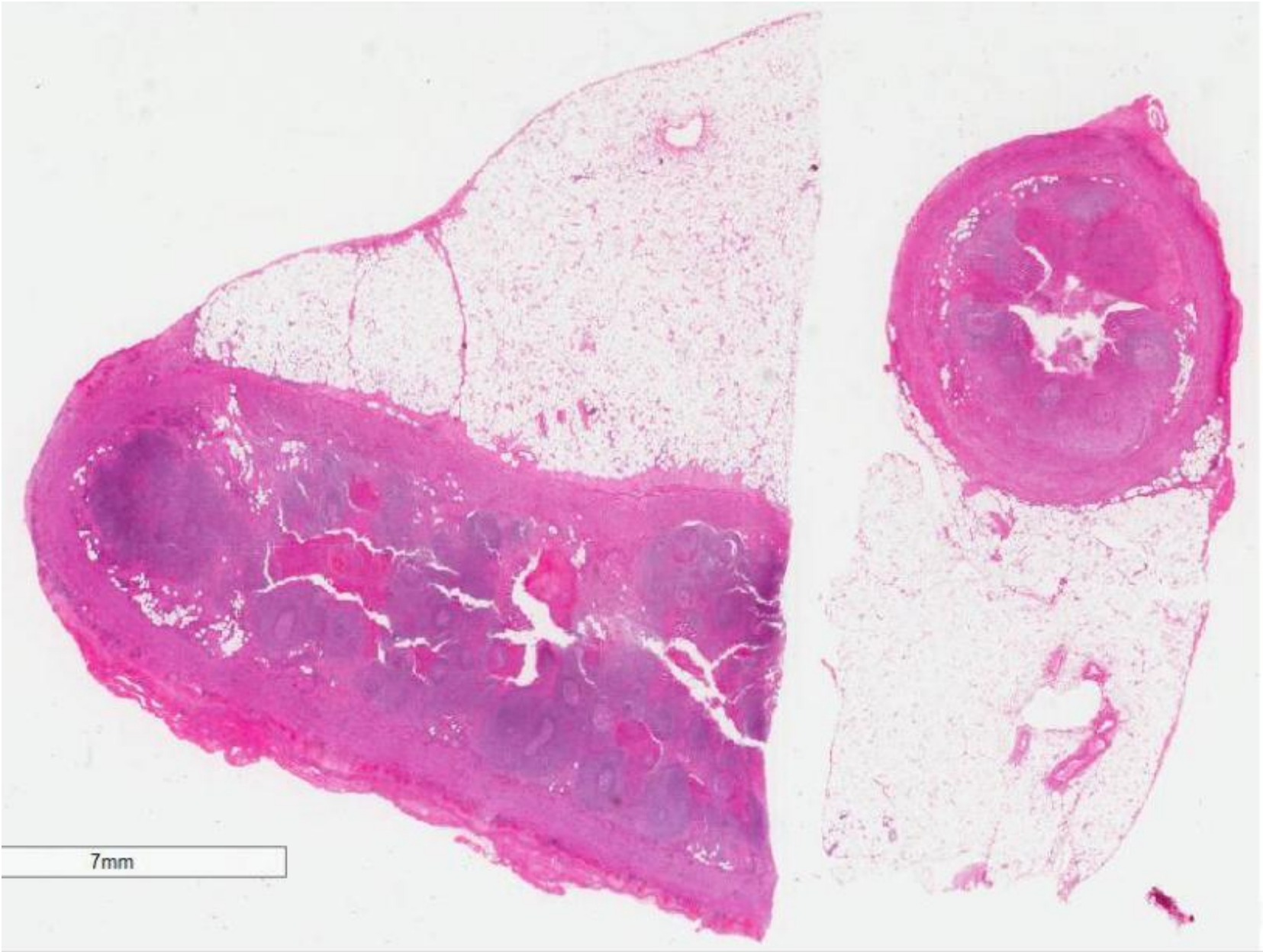


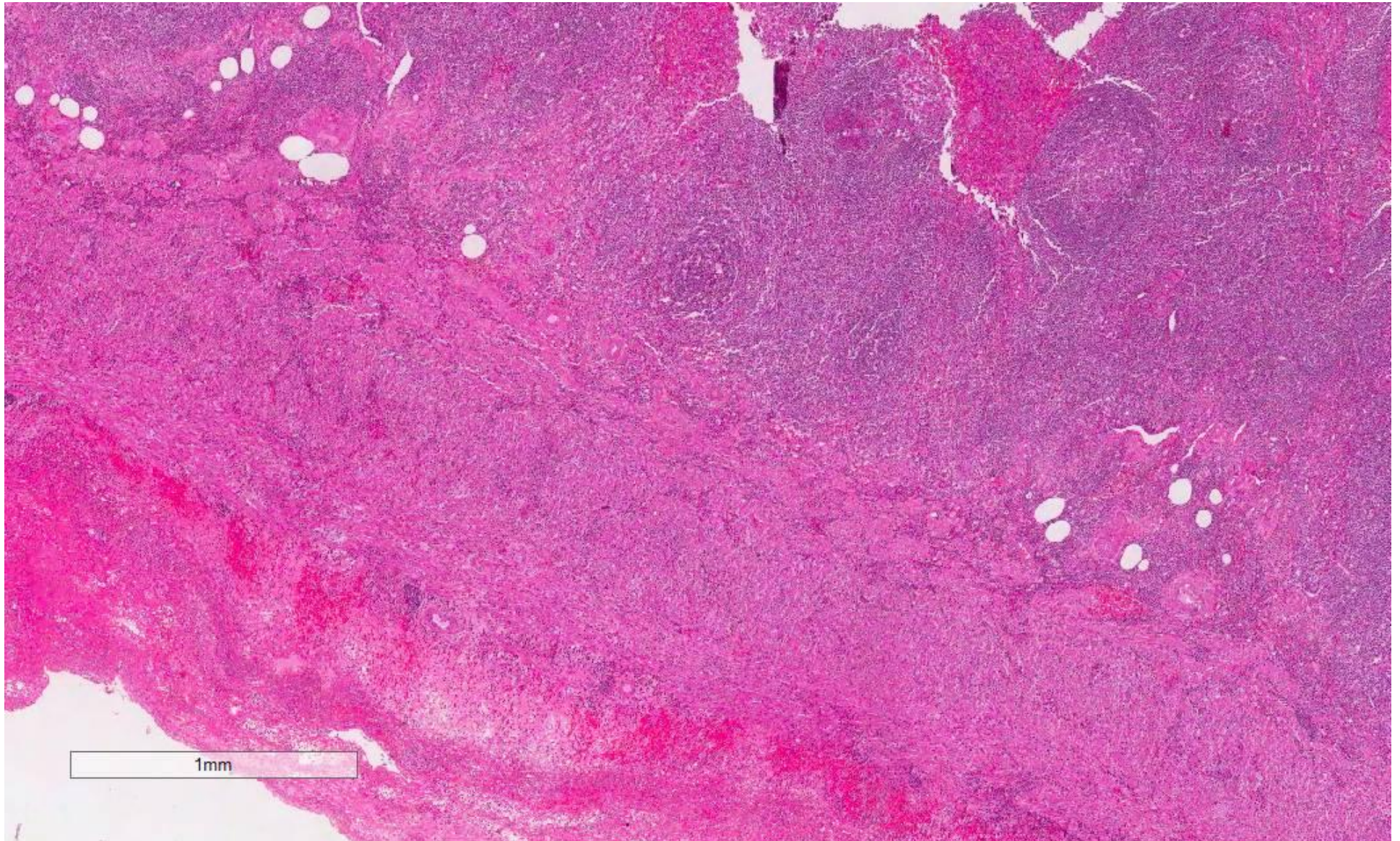
Sociedade Brasileira de Patologia

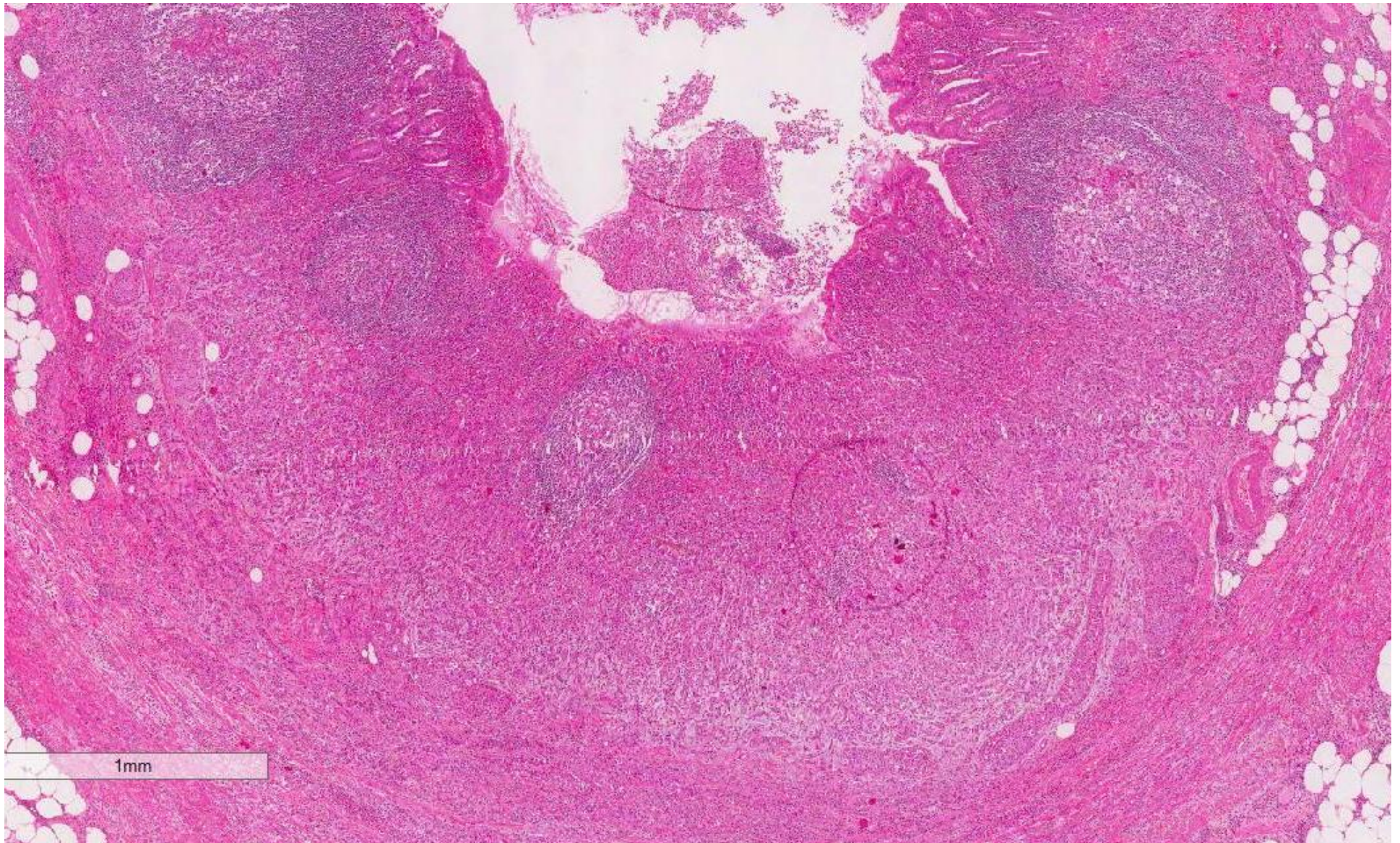
CASO

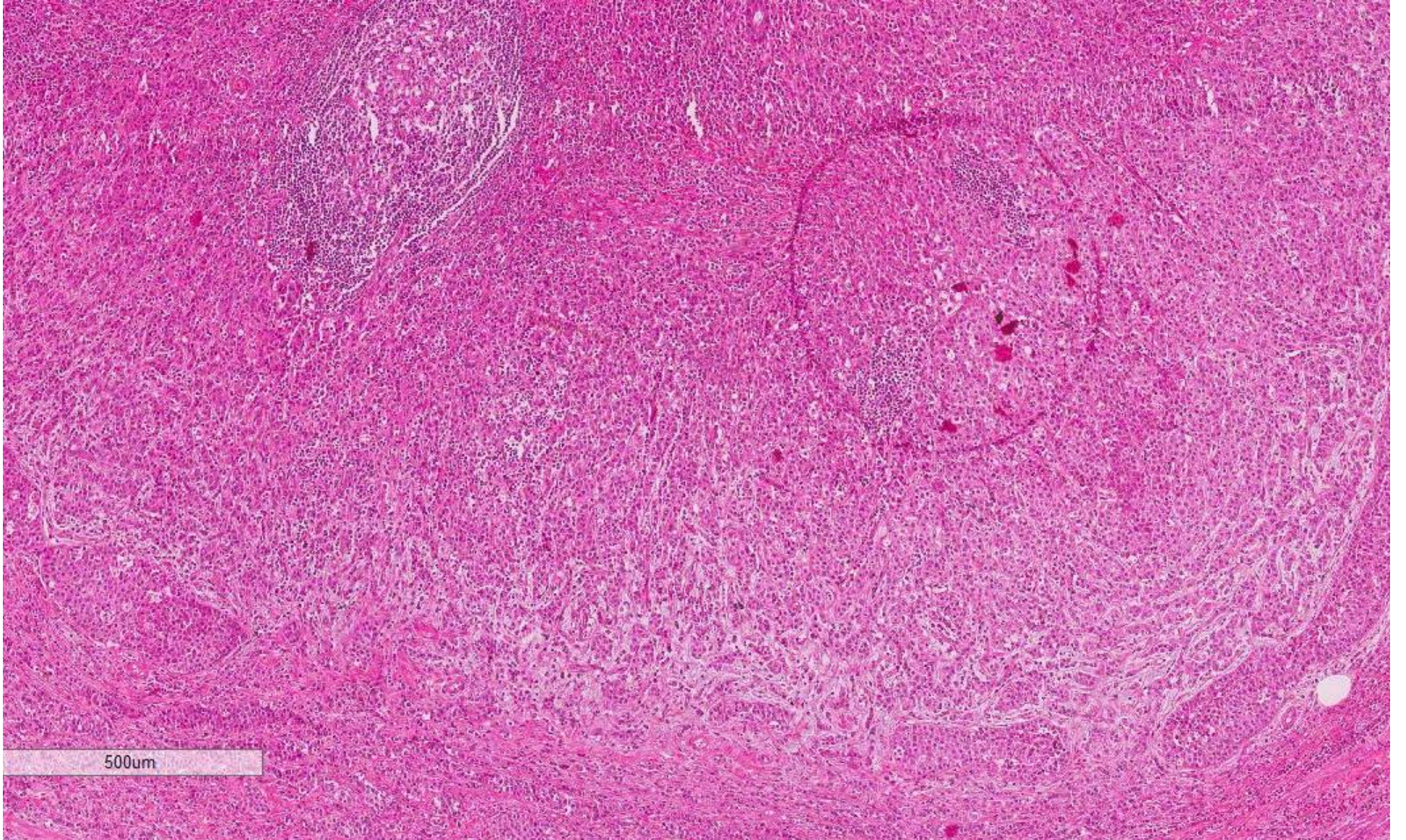


- Identificação:
 - Sexo Feminino
 - 80 anos
 - História: paciente operada por abdome agudo/apendicite, sendo realizada apendicectomia.

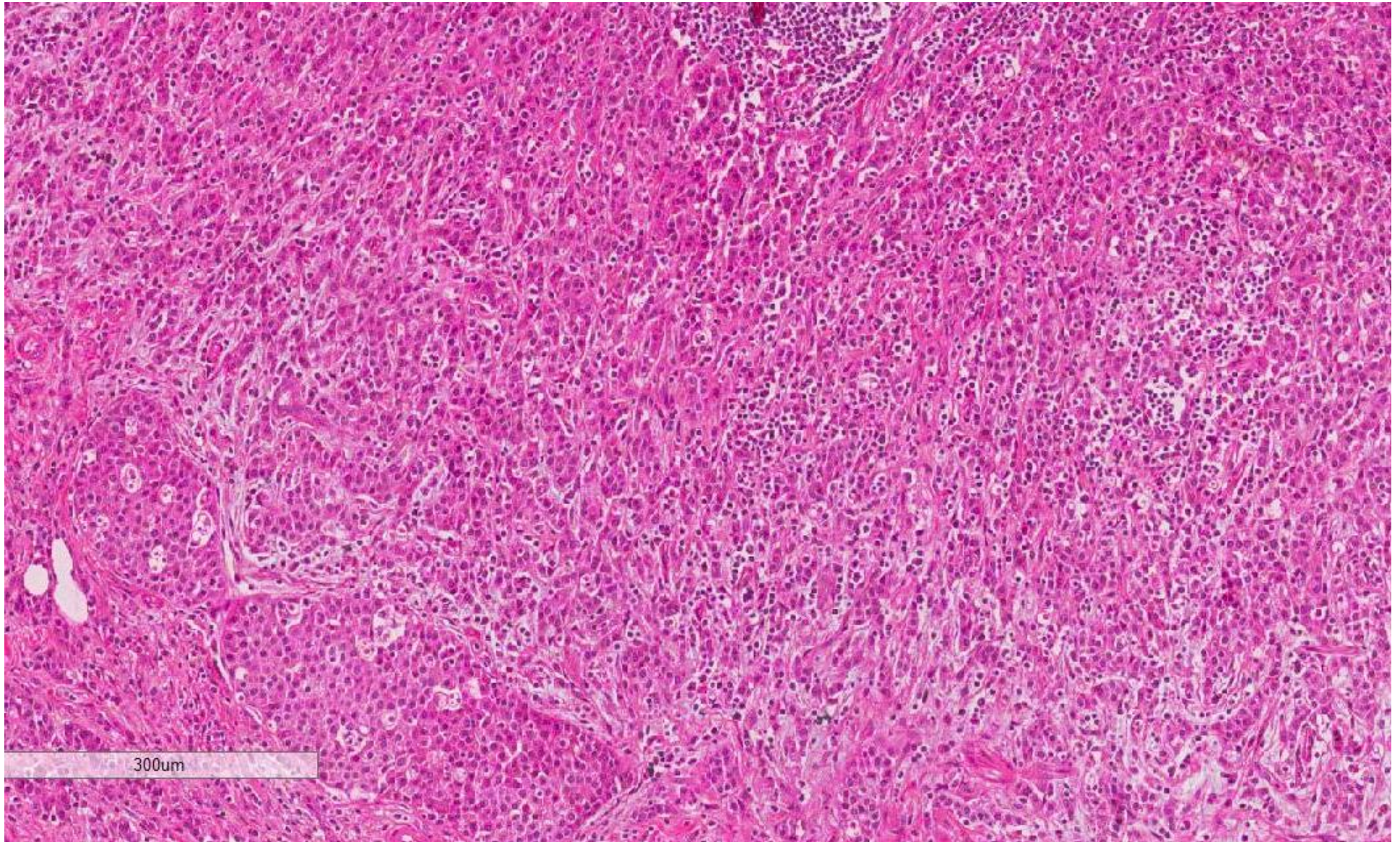


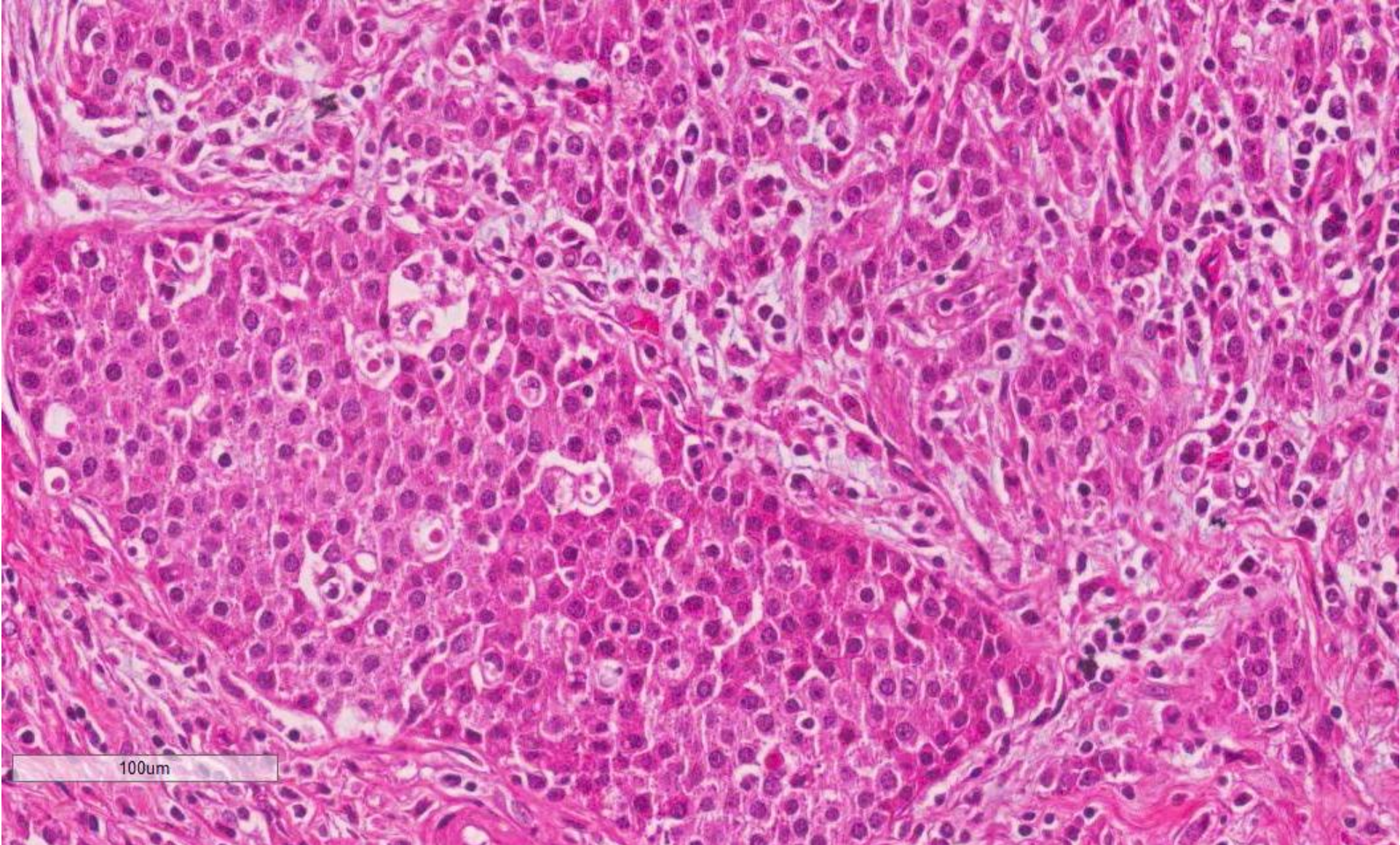






500µm





100um

**Com base nos achados
morfológicos, qual o seu
diagnóstico?**