
Caso do Mês

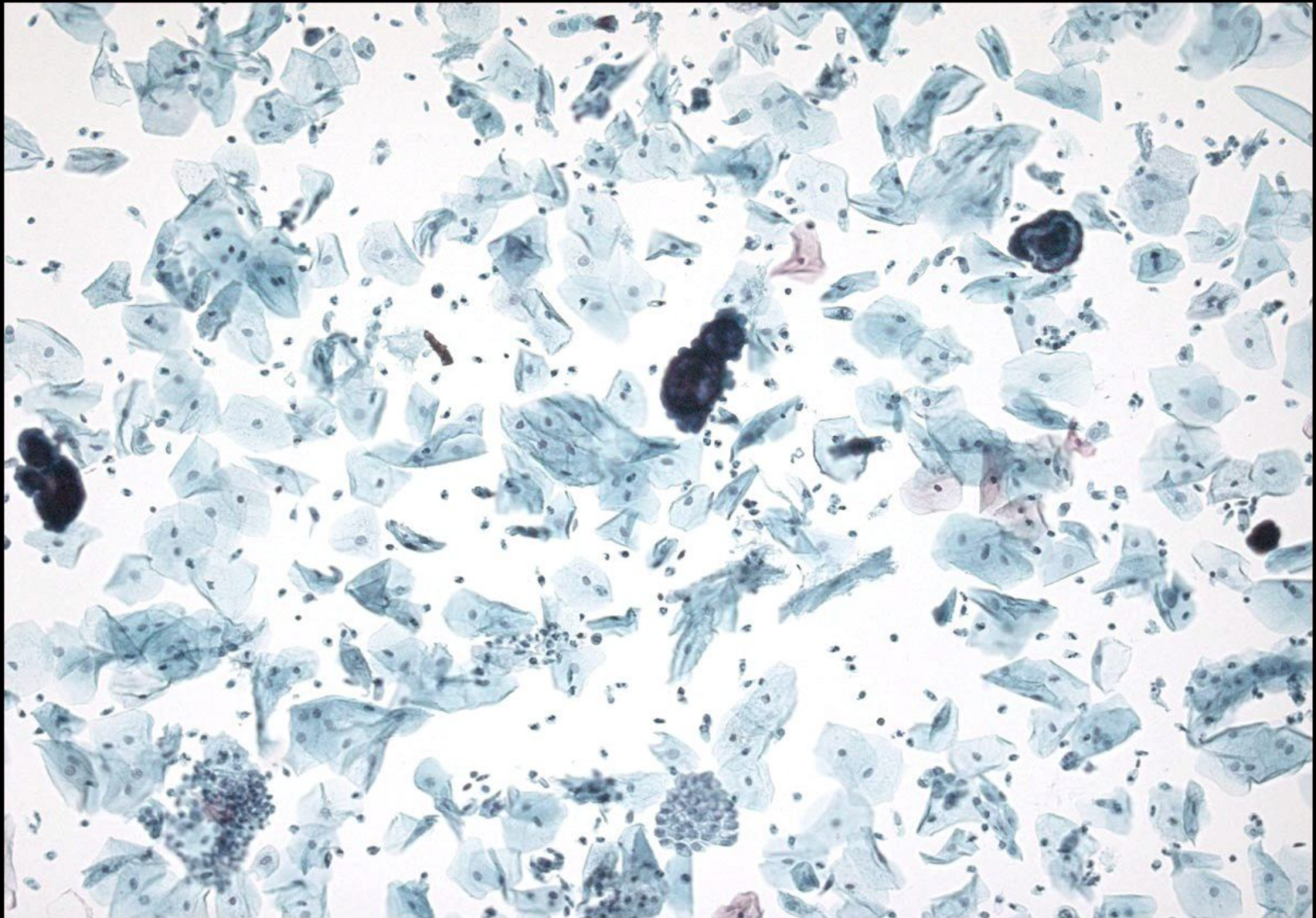
Sociedade Brasileira de
Patologia

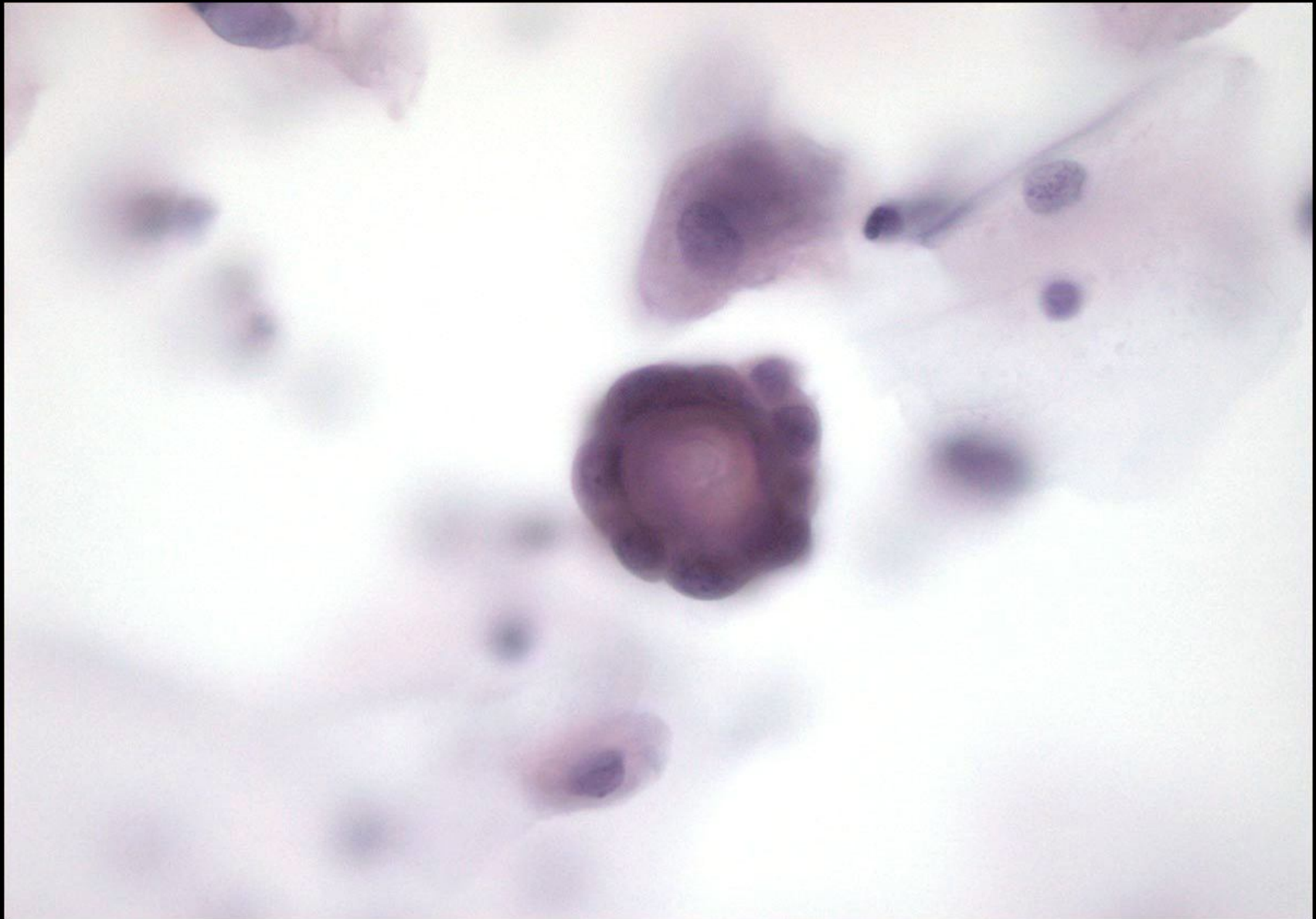
42 anos

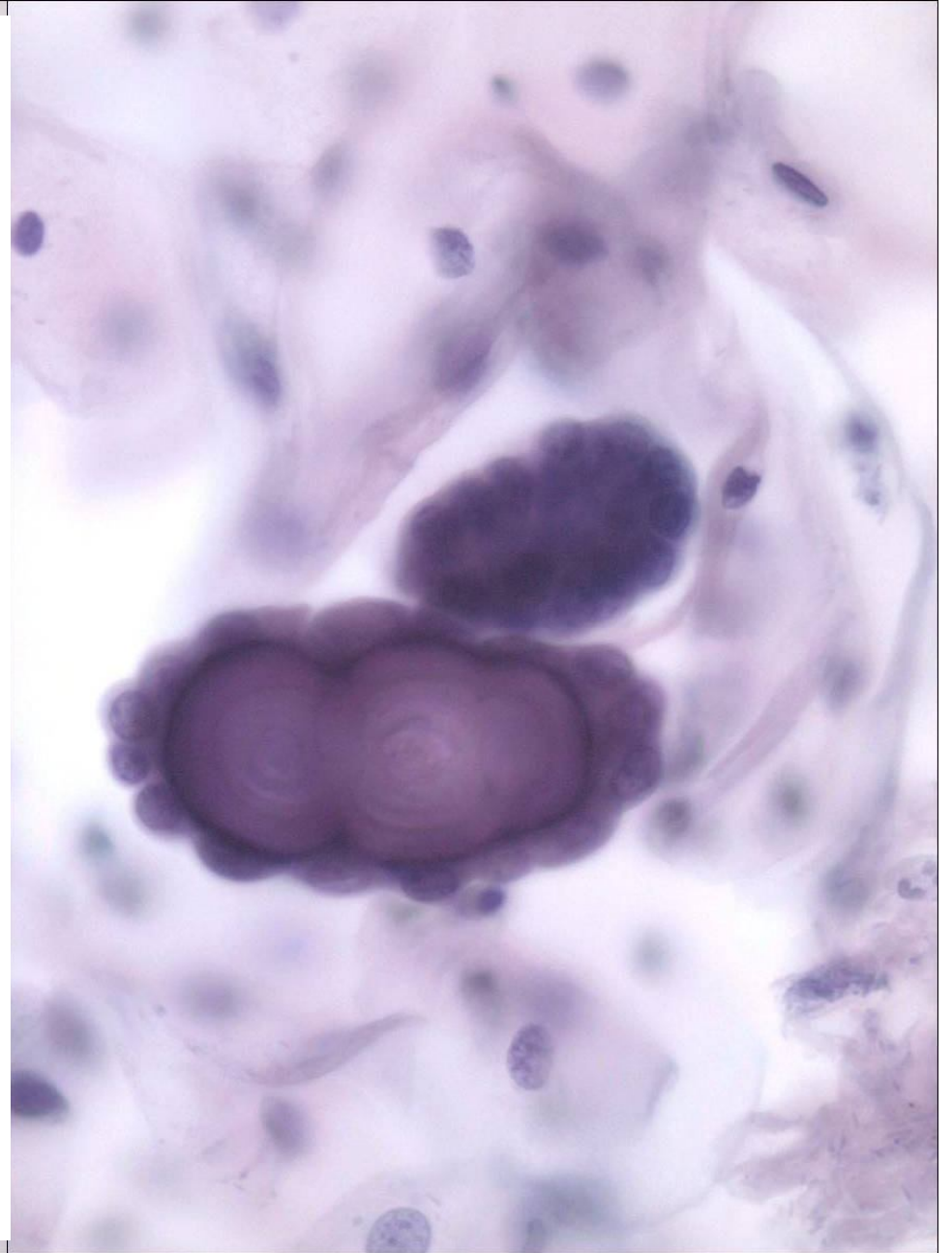
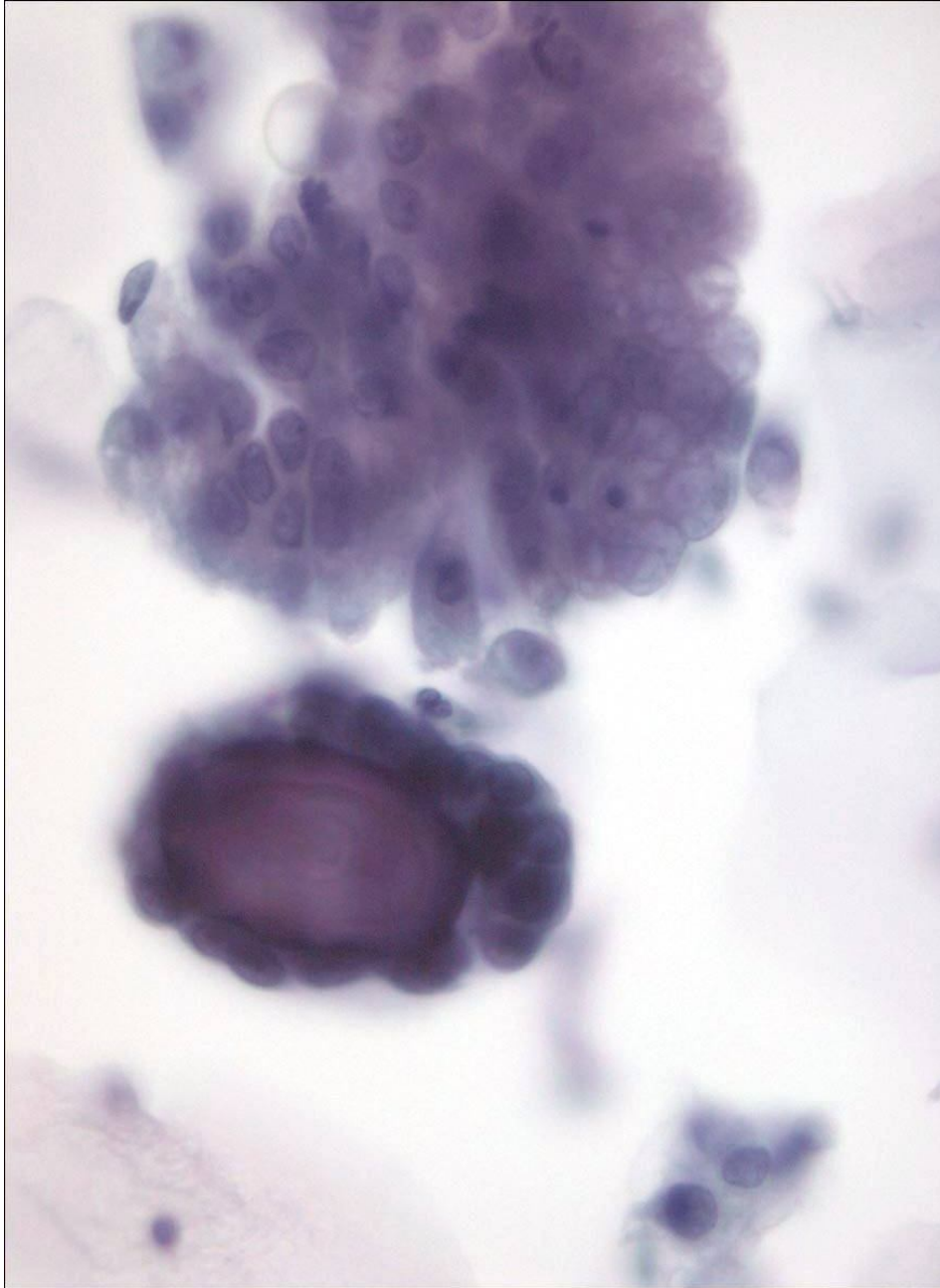
Citologia cervicovaginal

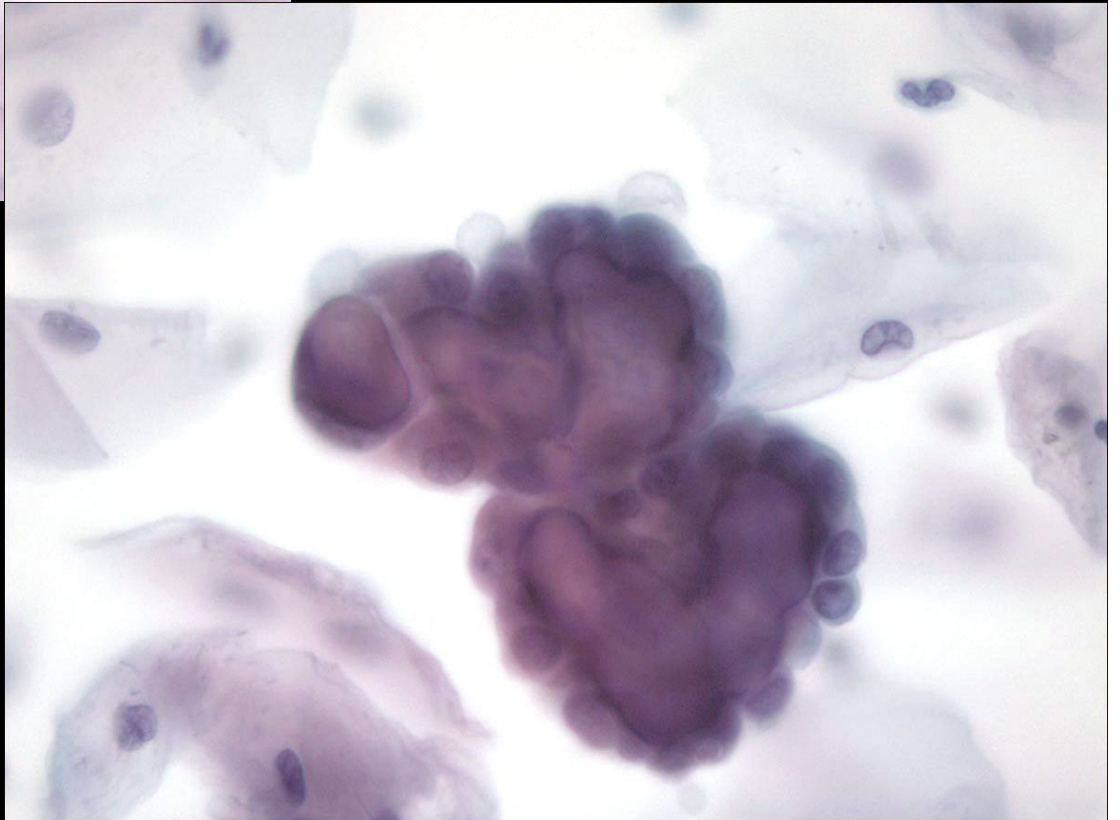
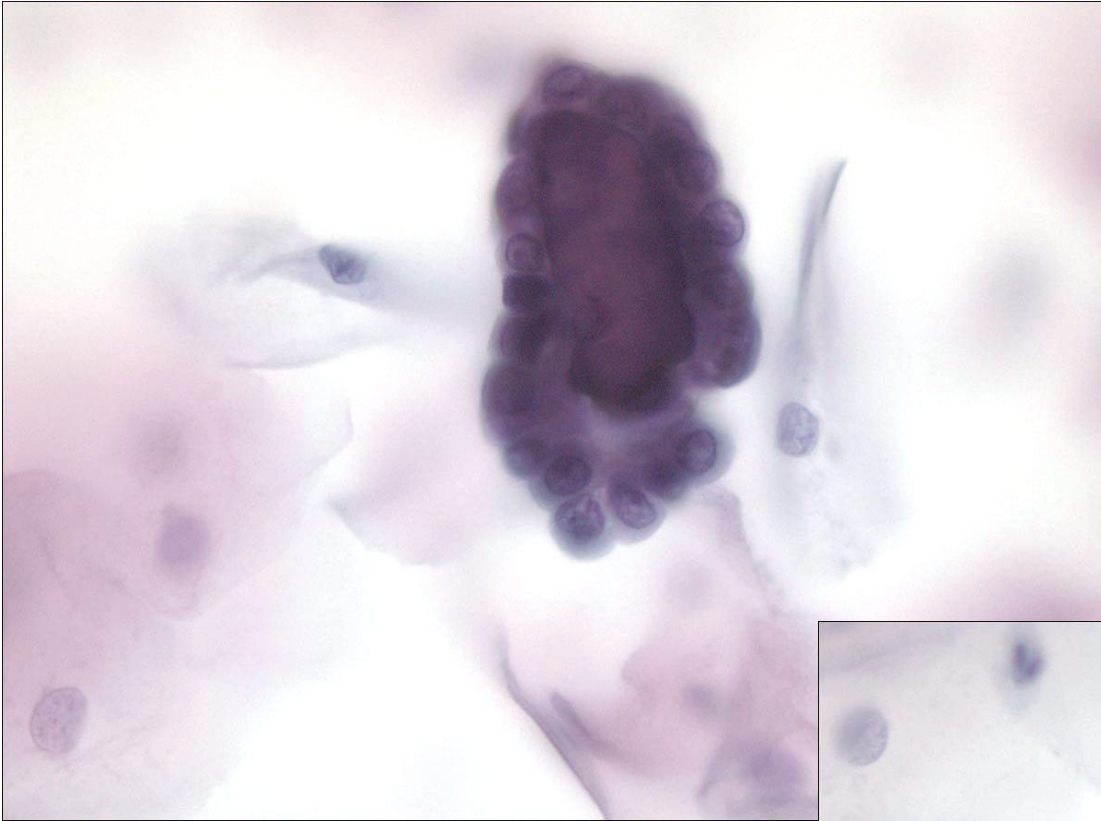
9º dia do ciclo.

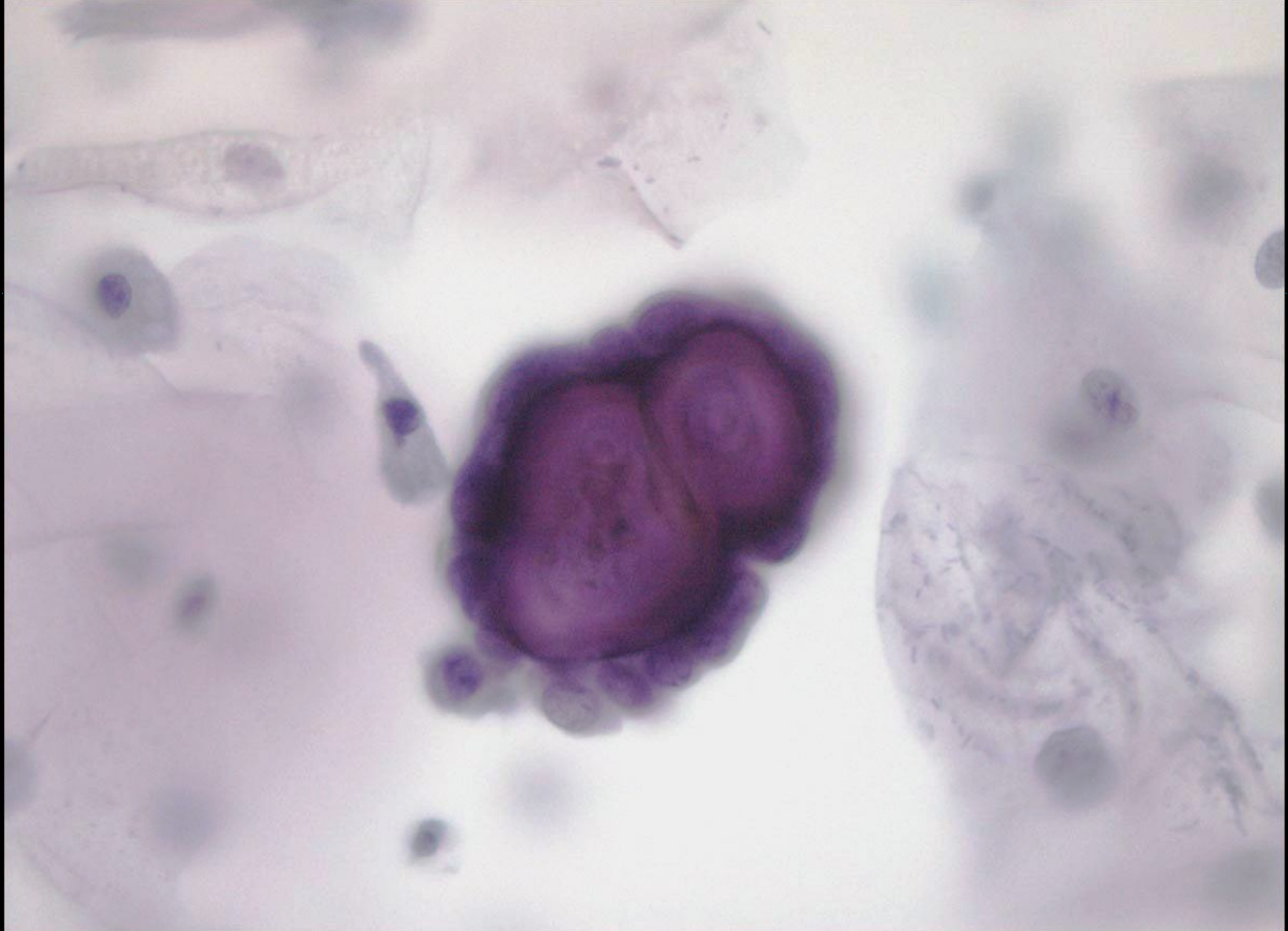
Cervix com aspecto normal à visualização.











Diagnóstico?
