



# CASO DO MÊS

---

SOCIEDADE BRASILEIRA  
DE PATOLOGIA



# História clínica

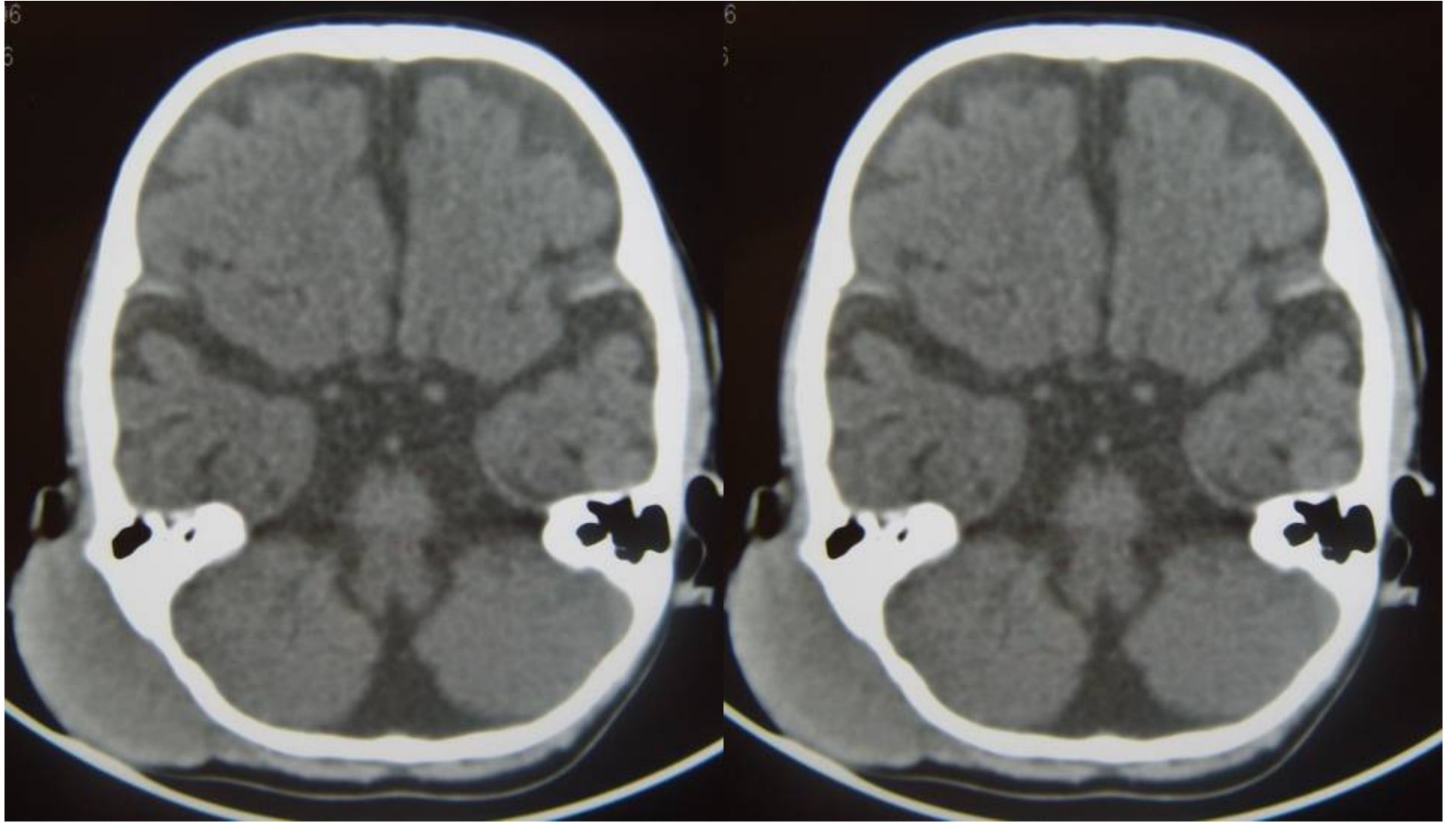
---

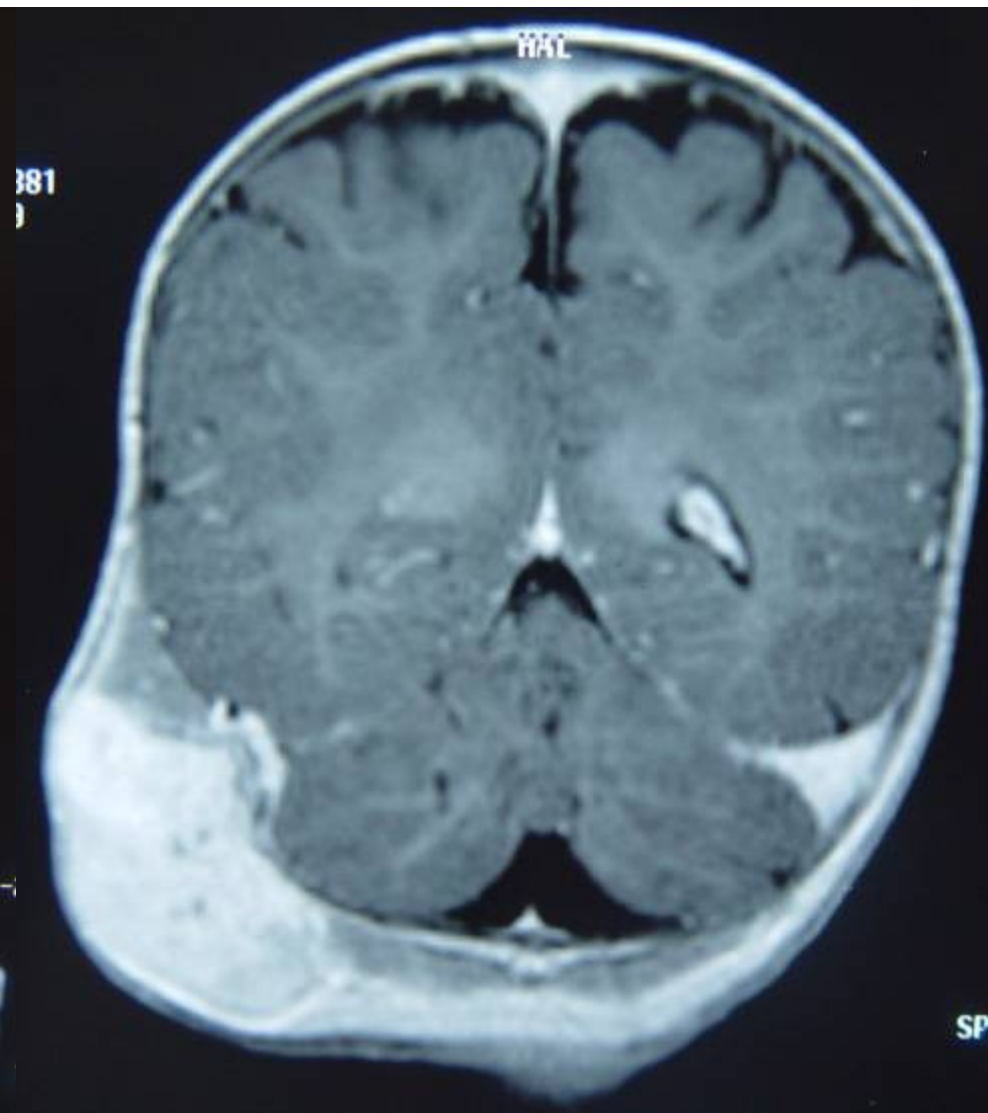
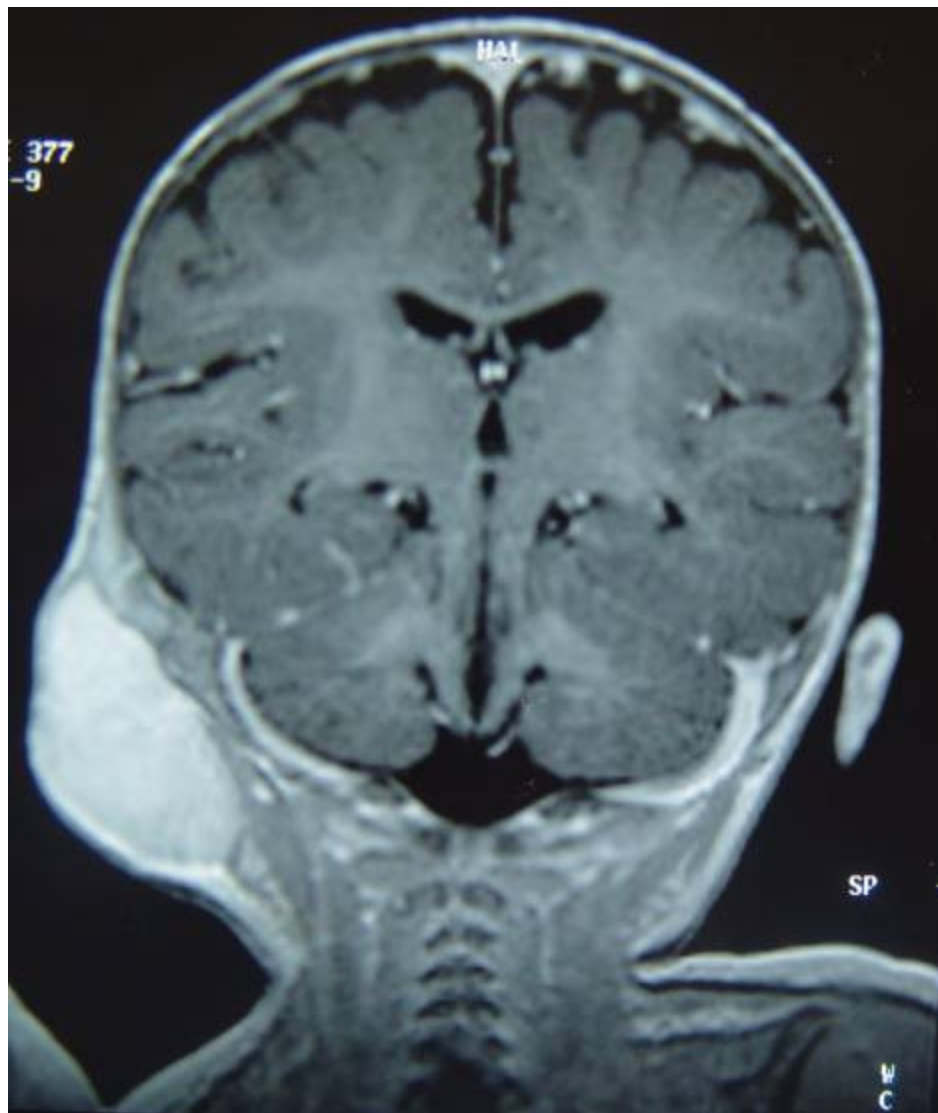
- G.A.N.R., masculino, 5 meses.
- Massa retroauricular direita há 3 meses, deslocando a orelha externa, sem sinais inflamatórios.
- DNPM normal. Ausência de sintomas otorrinolaringológicos.



---

# **EXAMES DE IMAGEM**



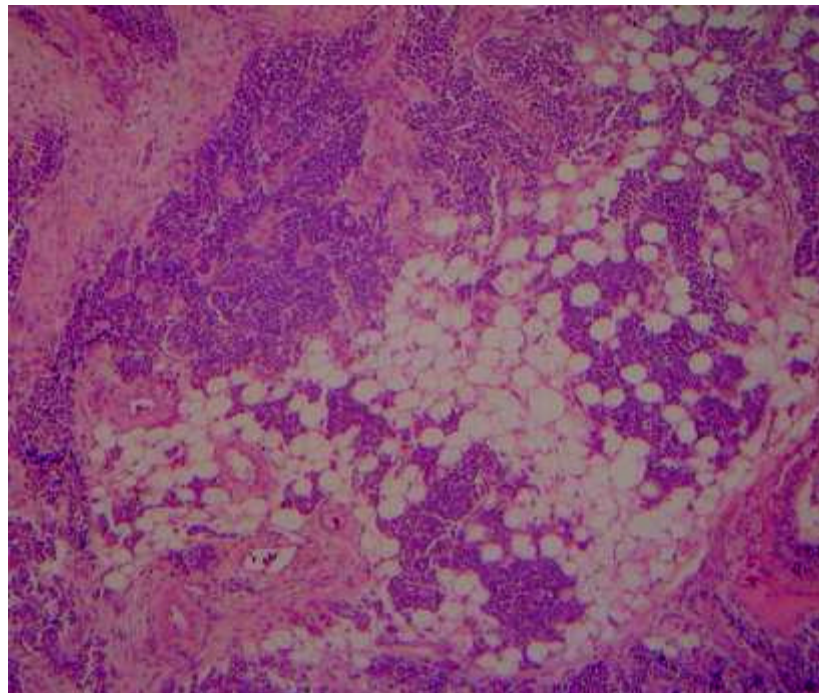
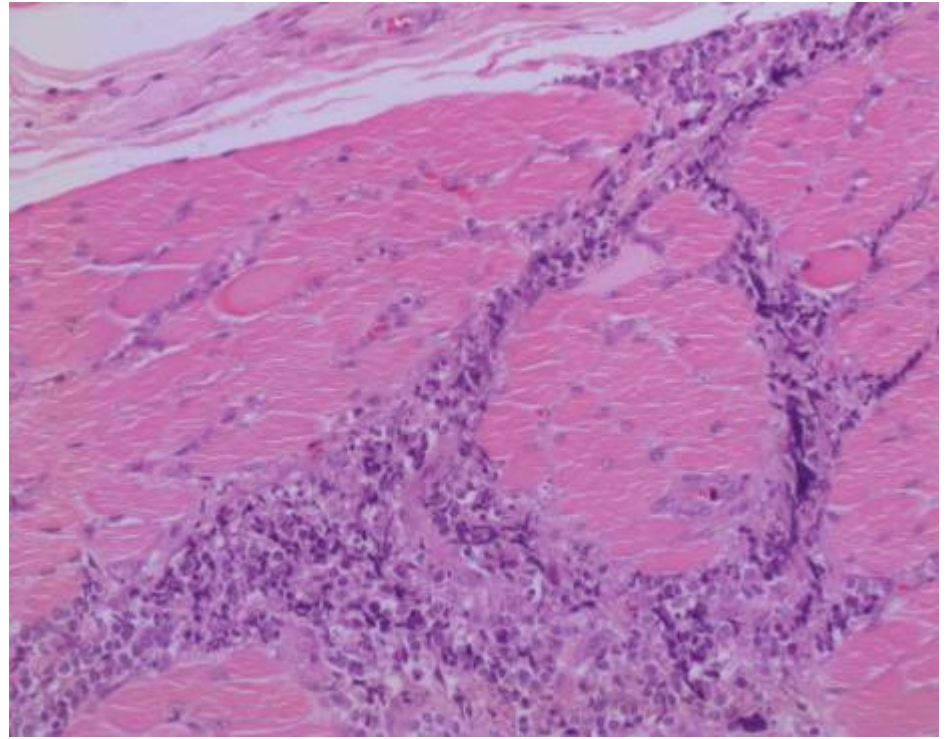
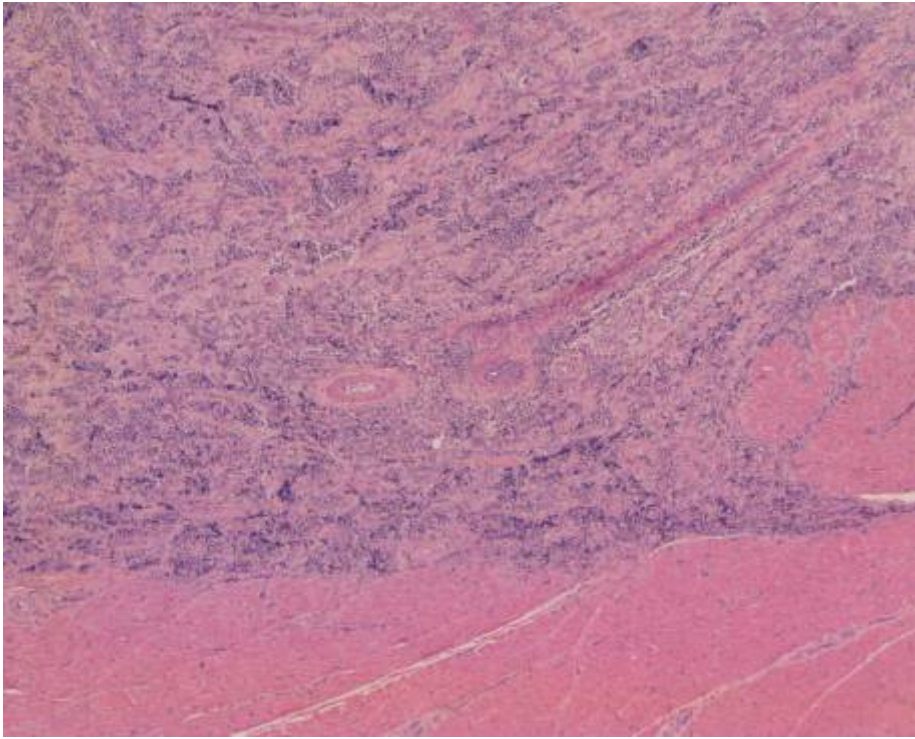




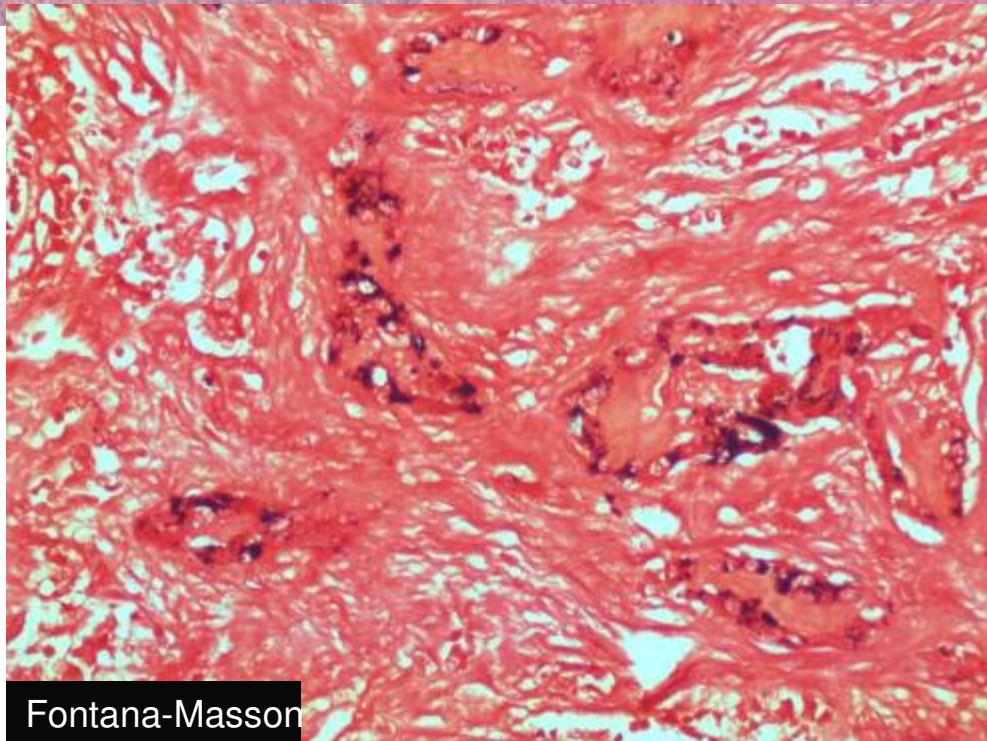
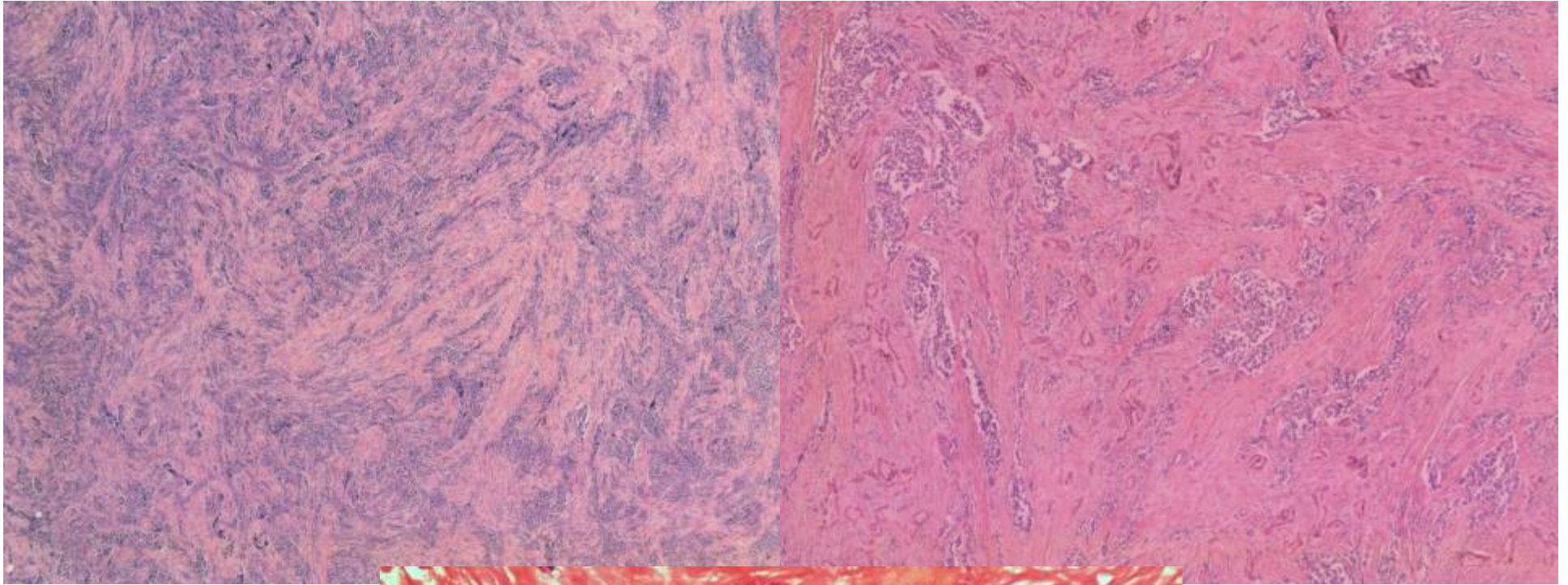
---

# **ACHADOS HISTOPATOLÓGICOS**



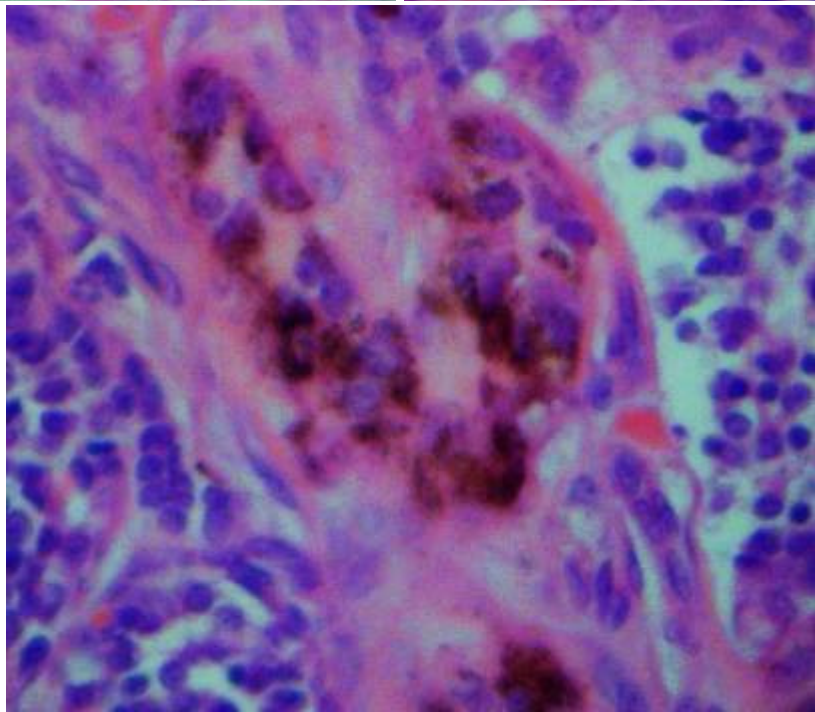
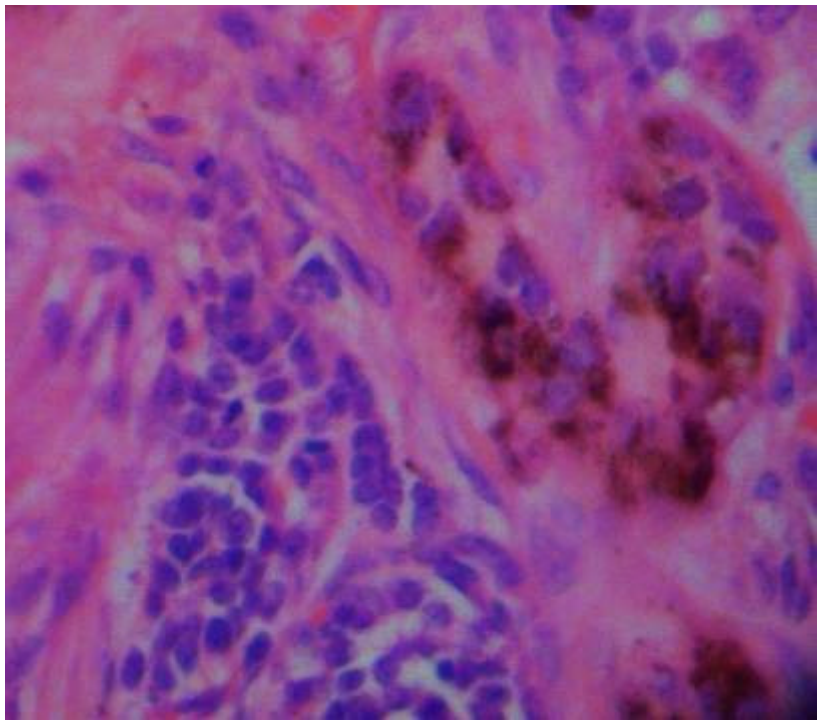
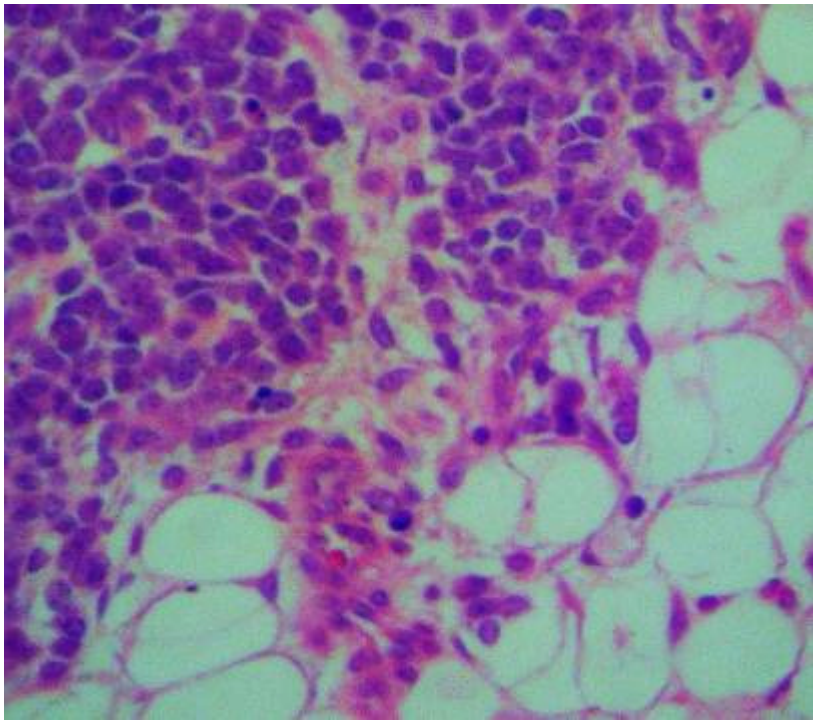


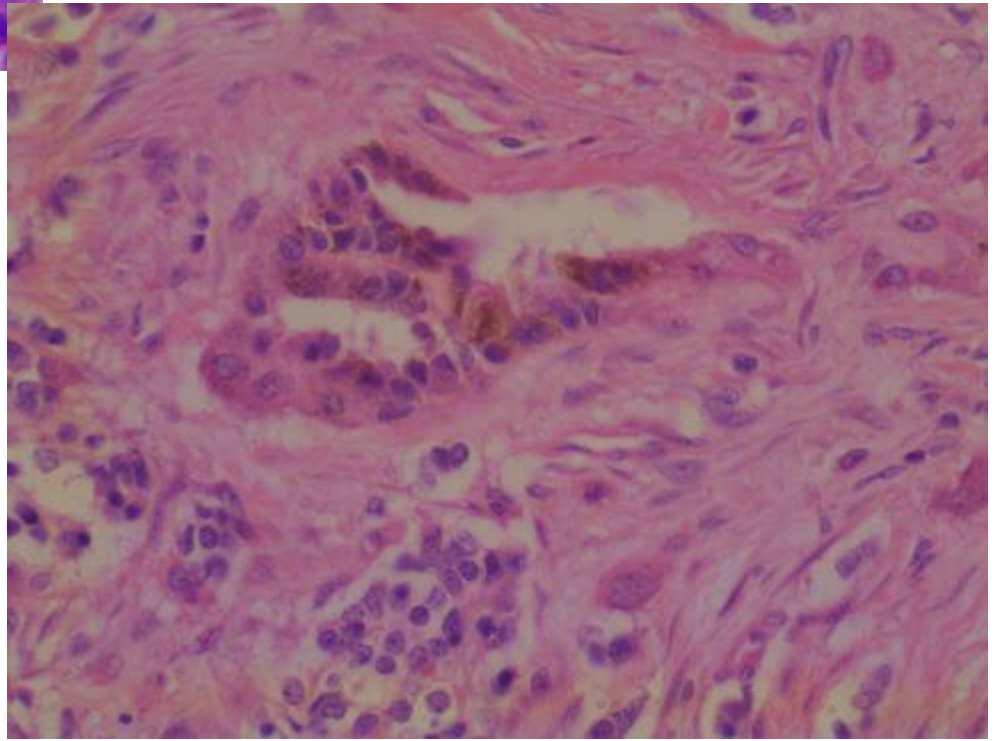
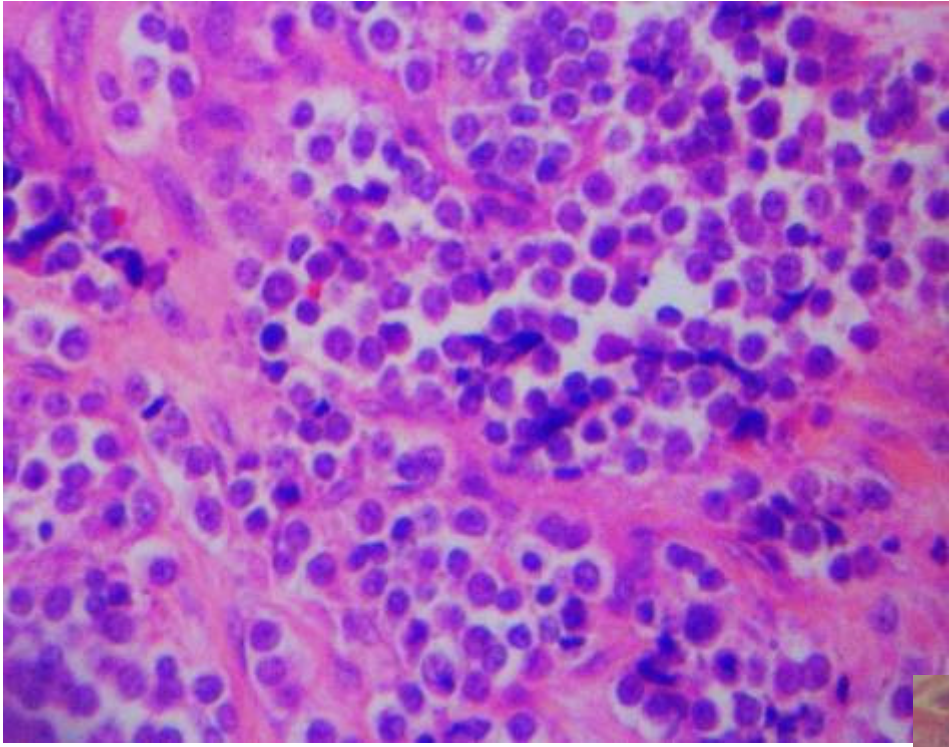




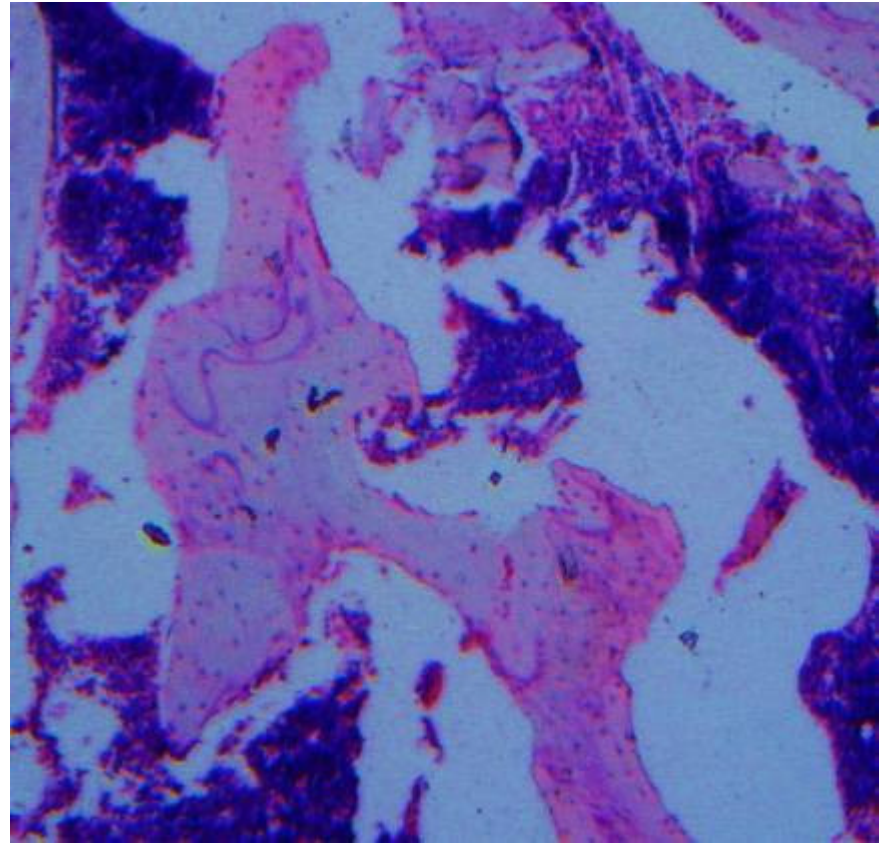
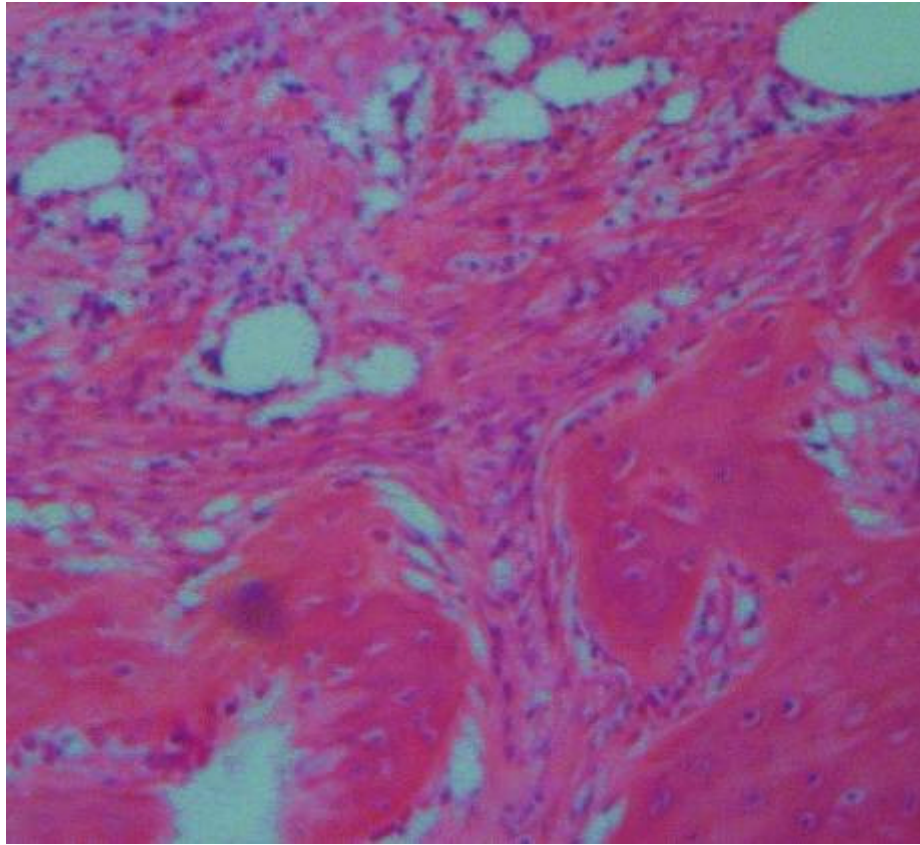
Fontana-Masson

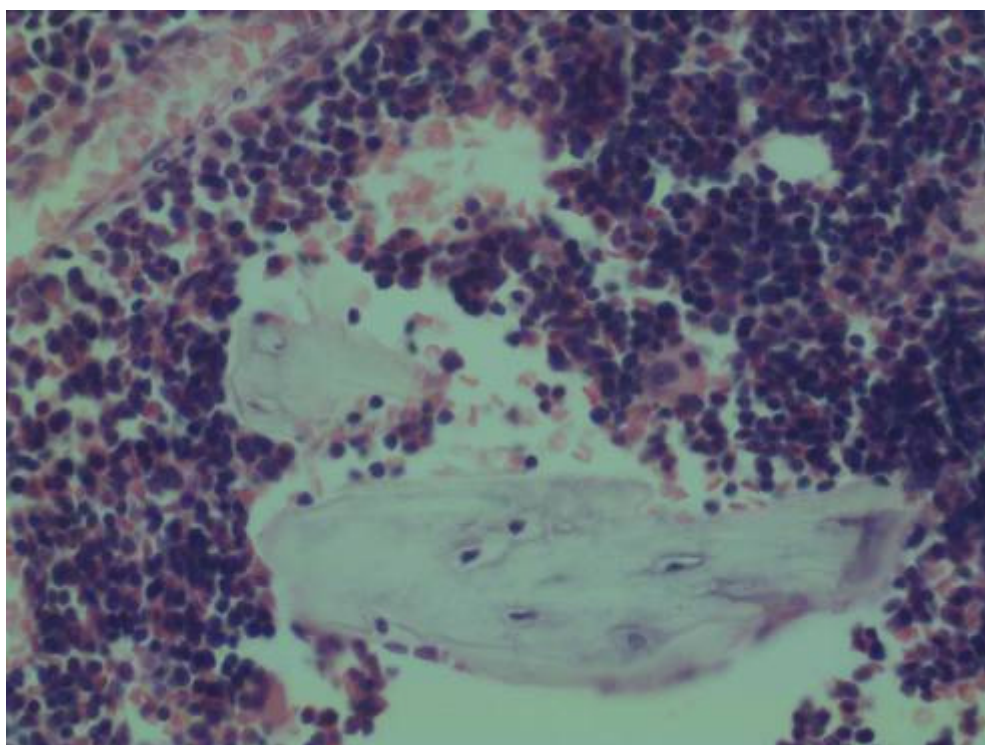










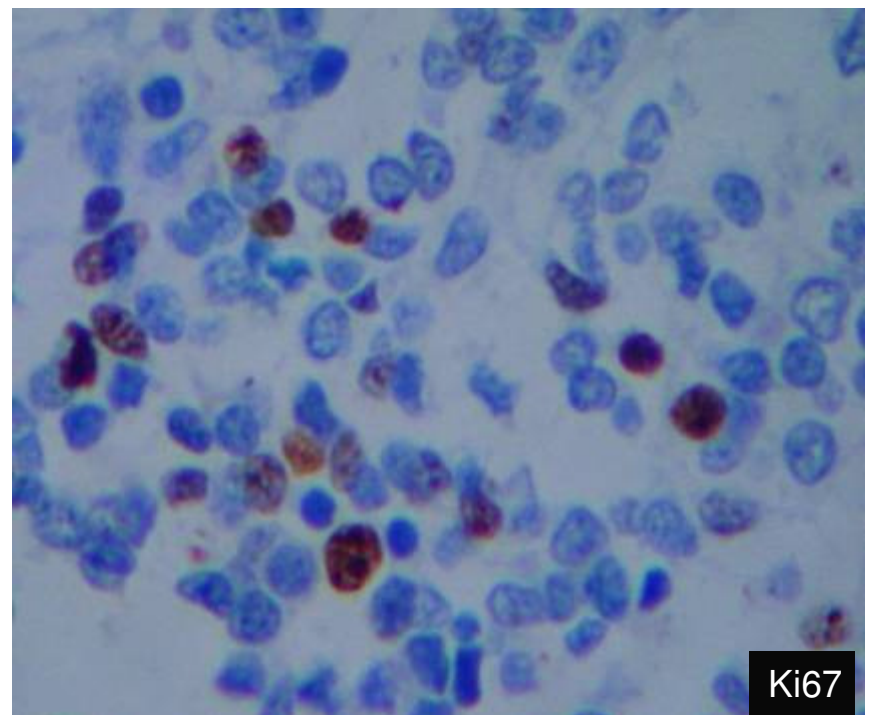
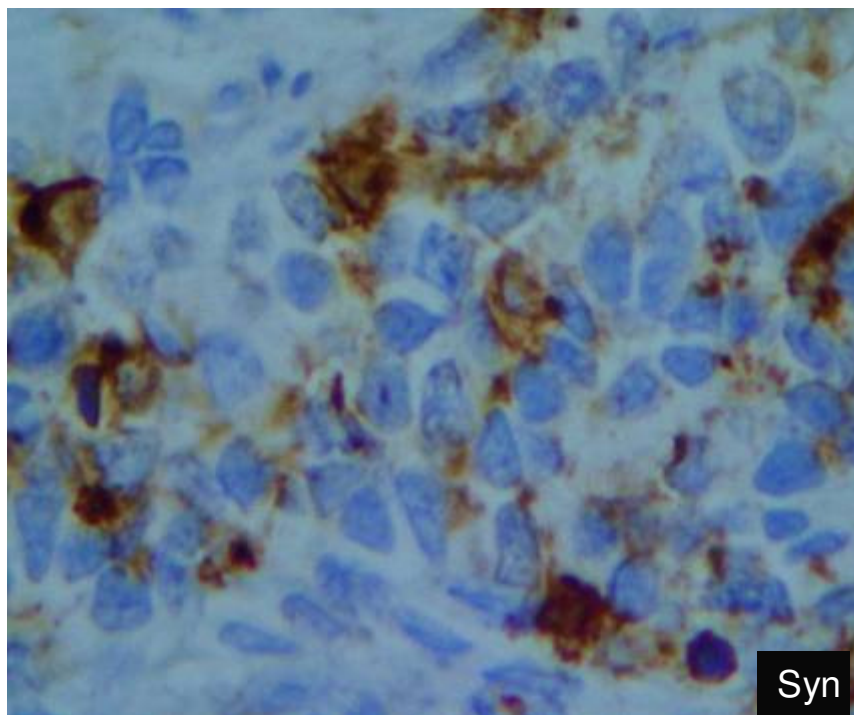
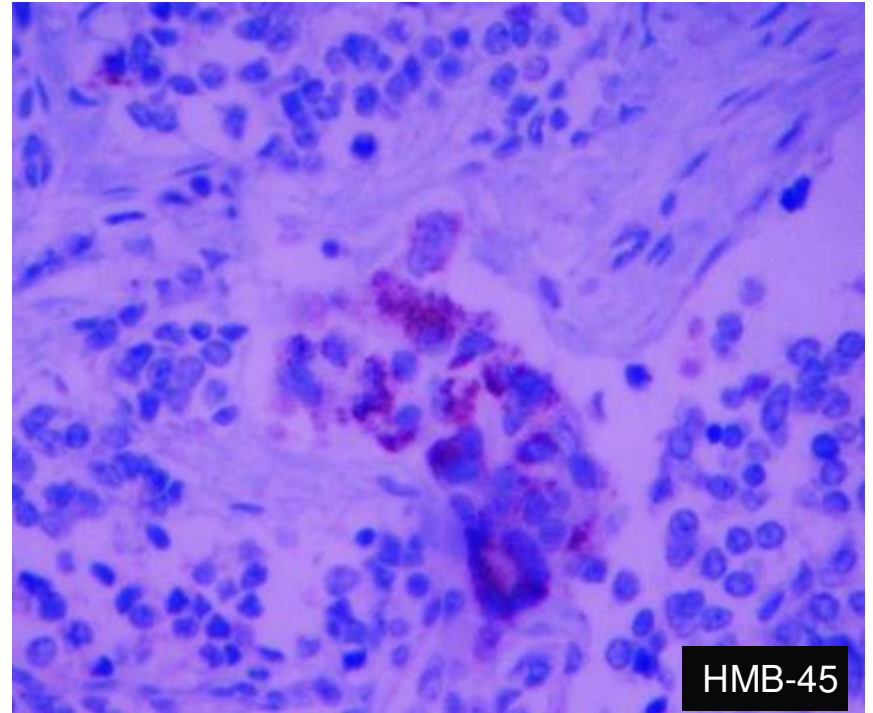
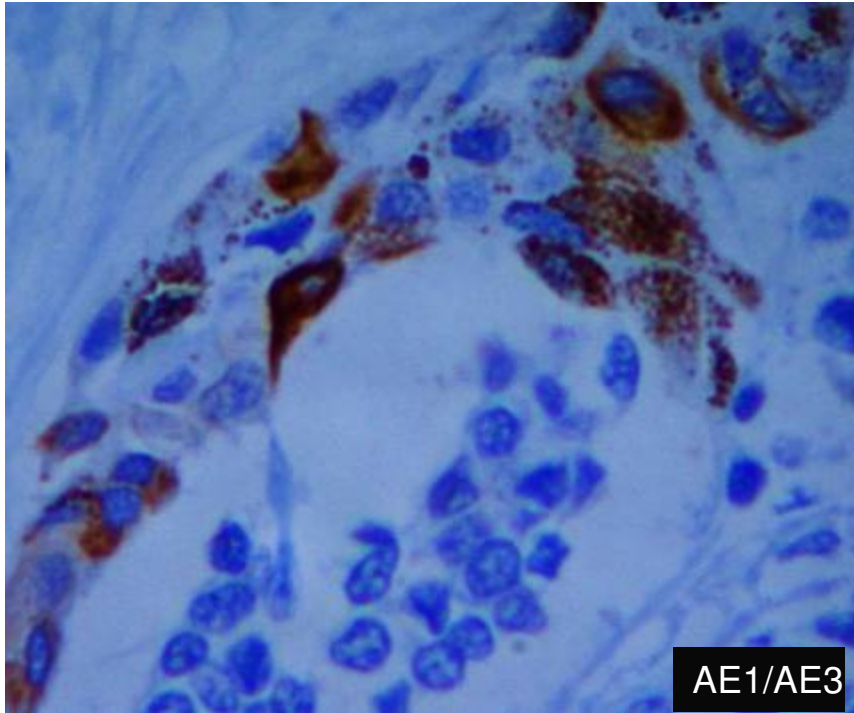






---

# IMUNO-HISTOQUÍMICA





---

Qual é o diagnóstico?