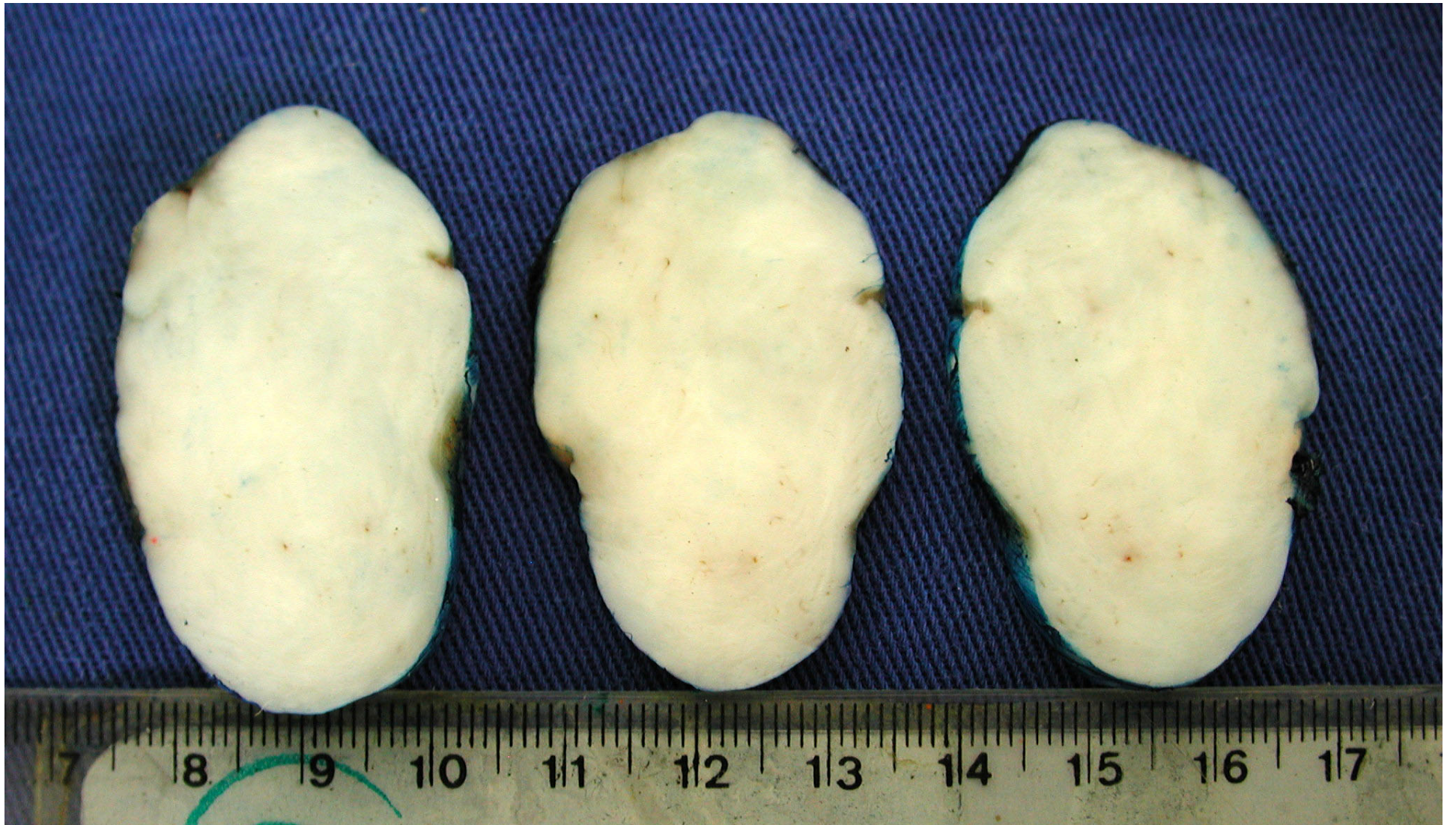

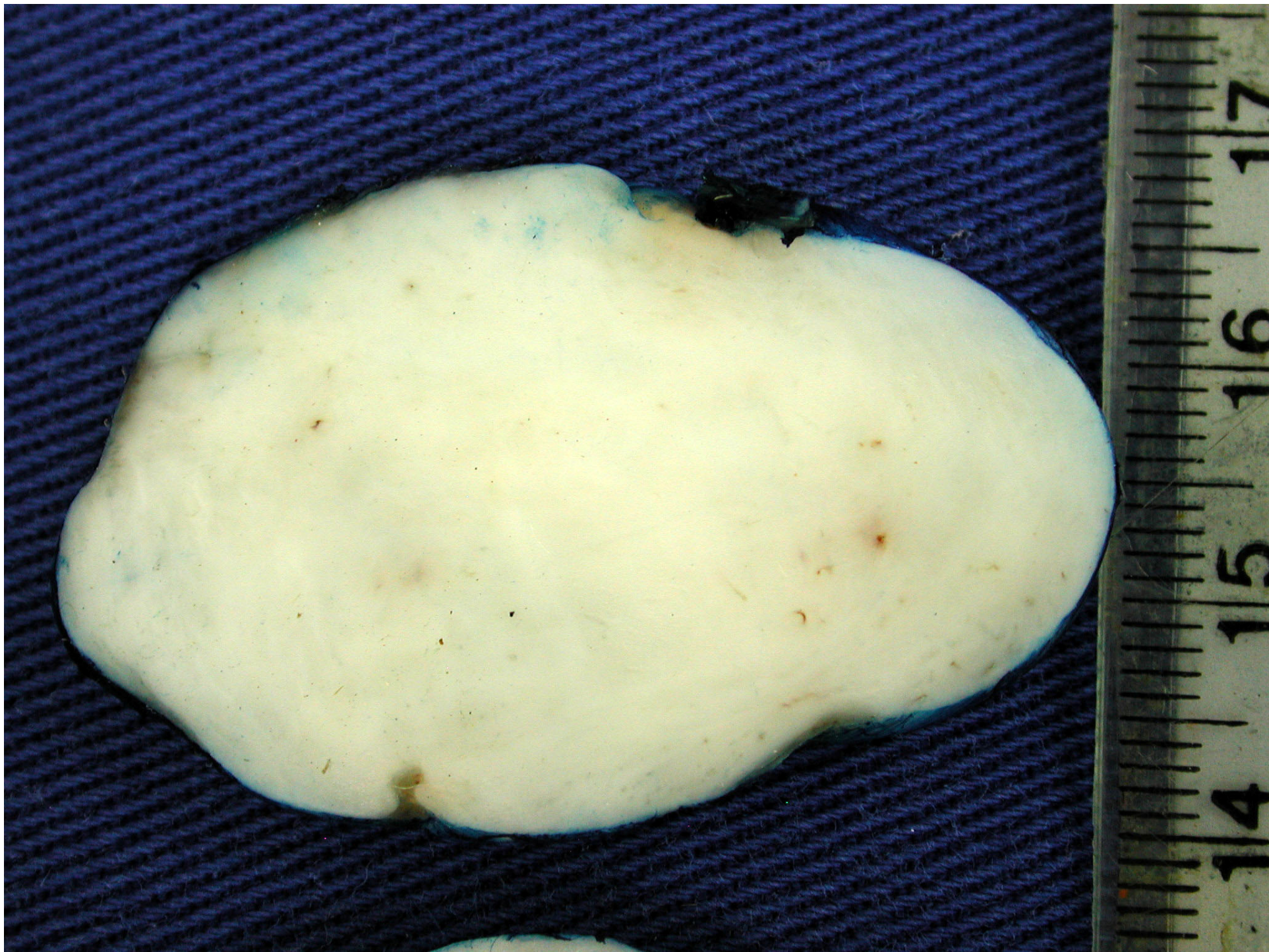
CASO DO MÊS

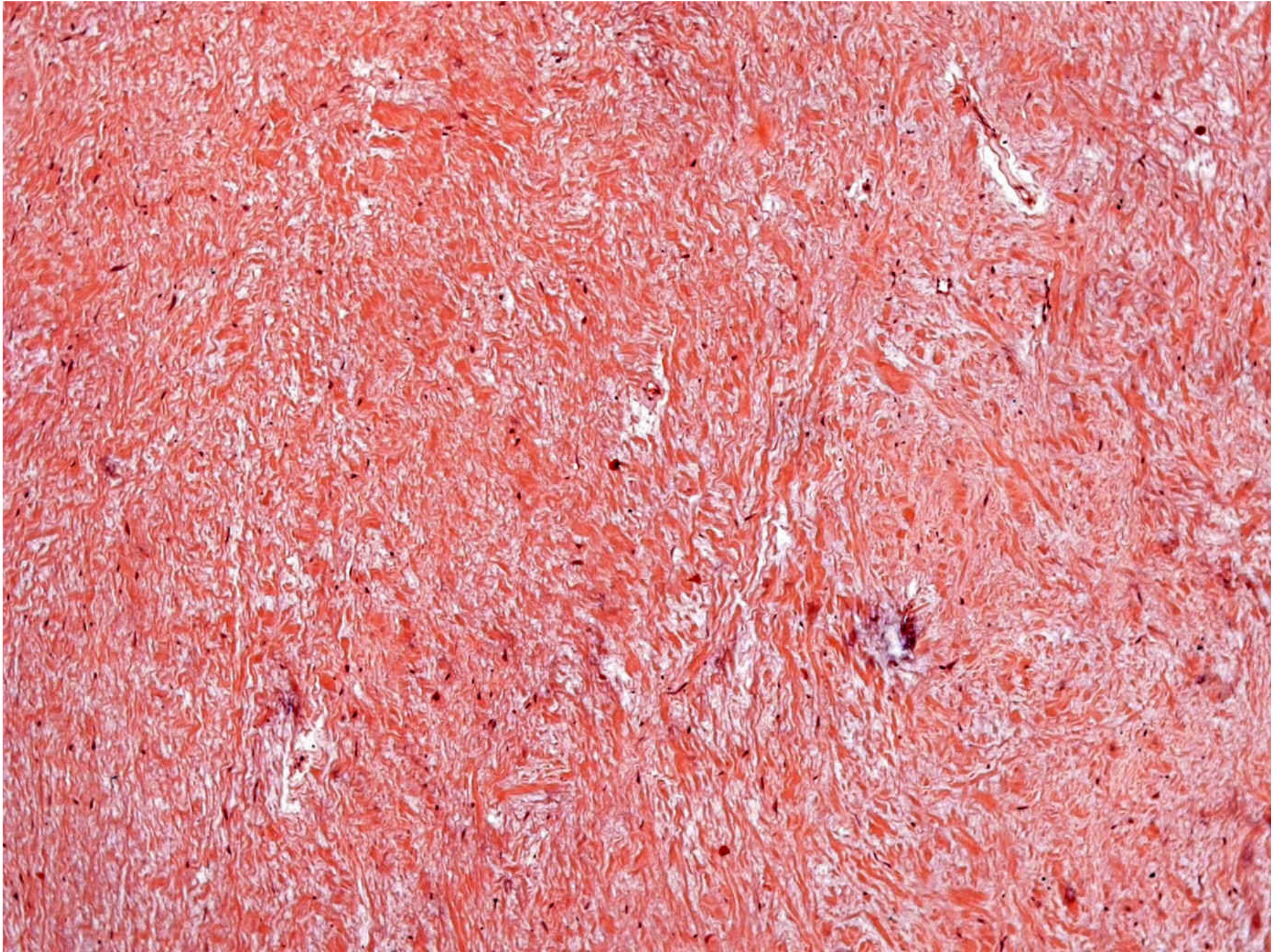
João Henrique do Amaral e Silva

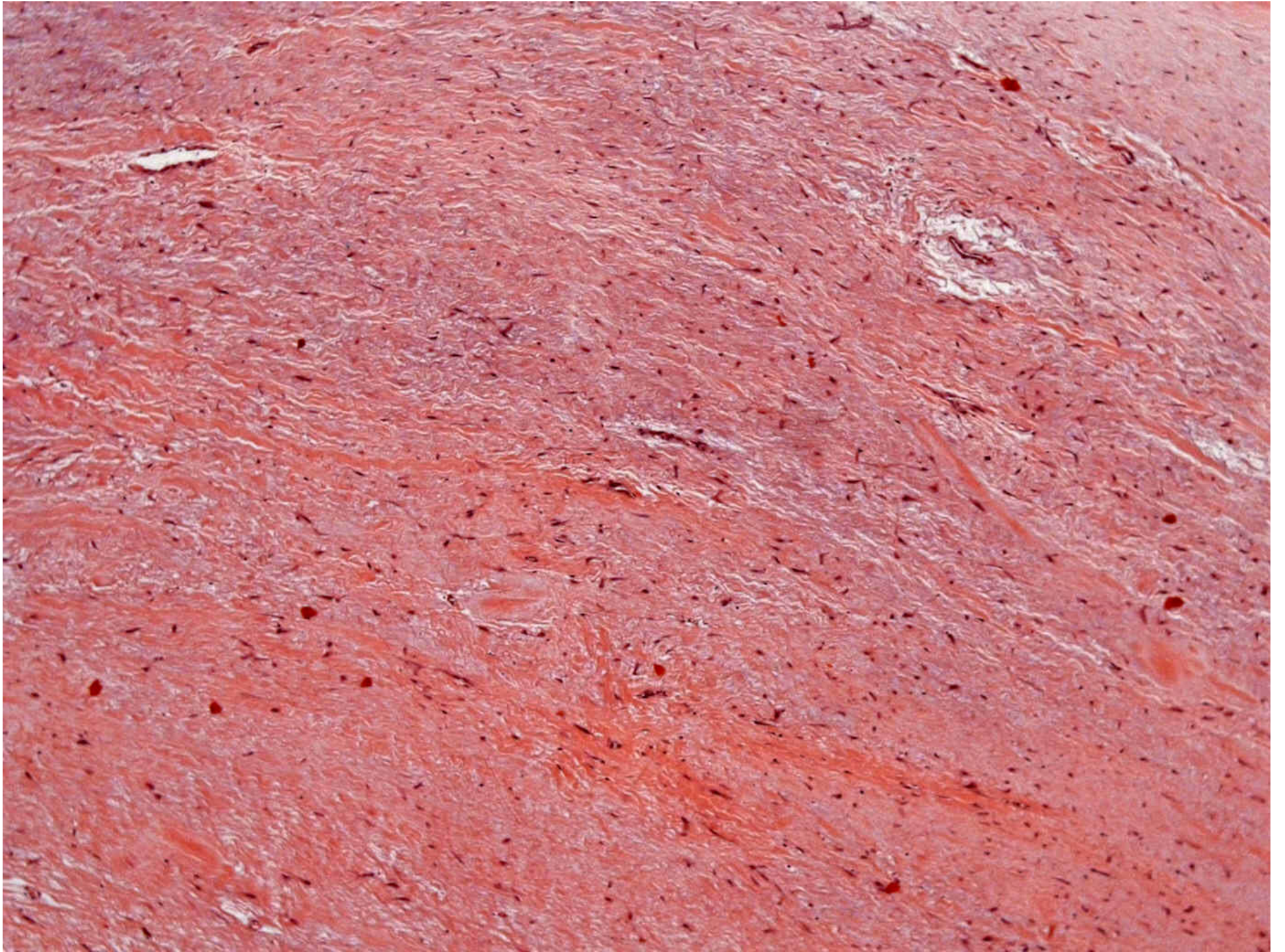
Paciente do sexo masculino,
61 anos.

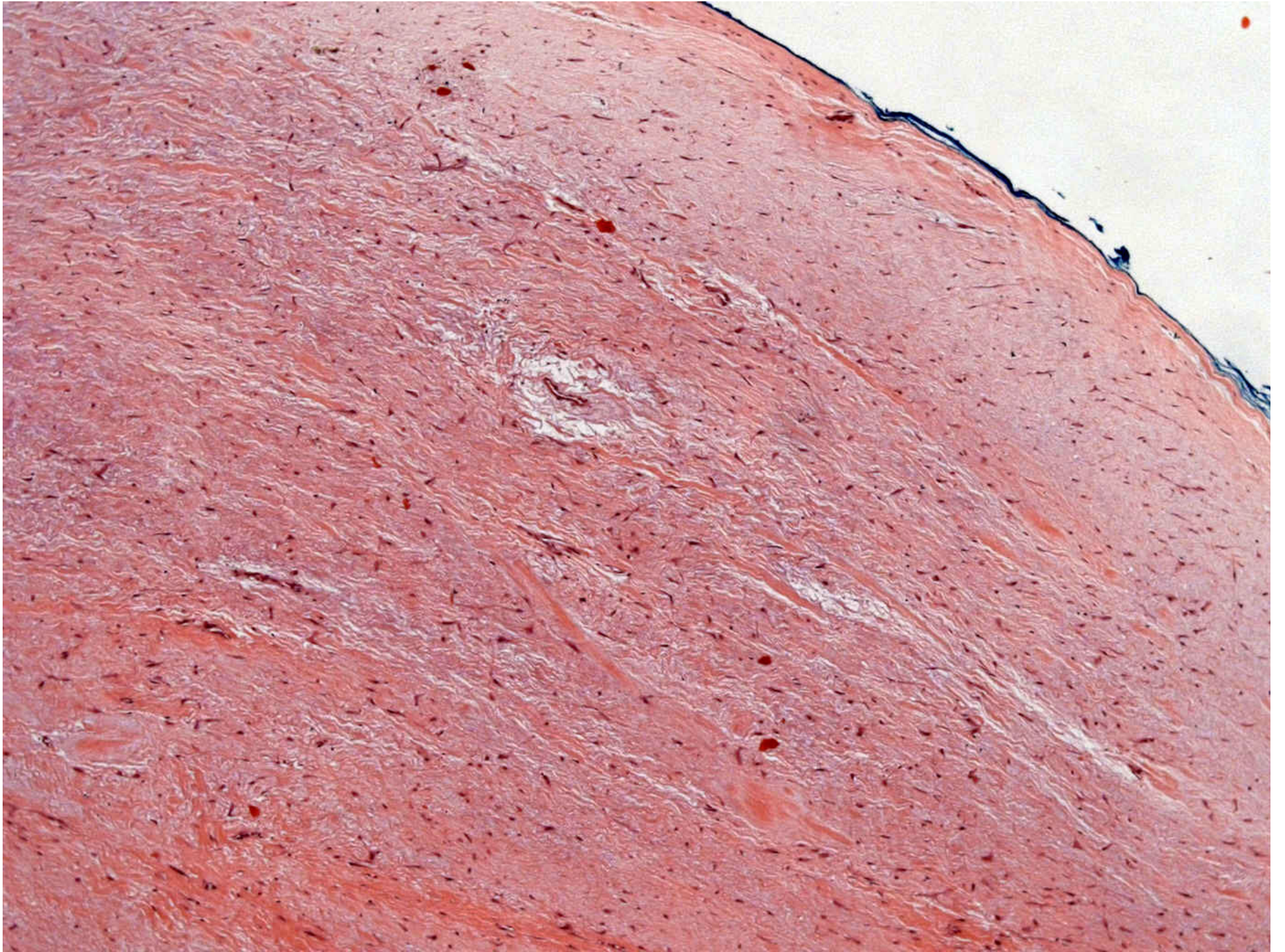
Tumor de partes moles em
região torácica.

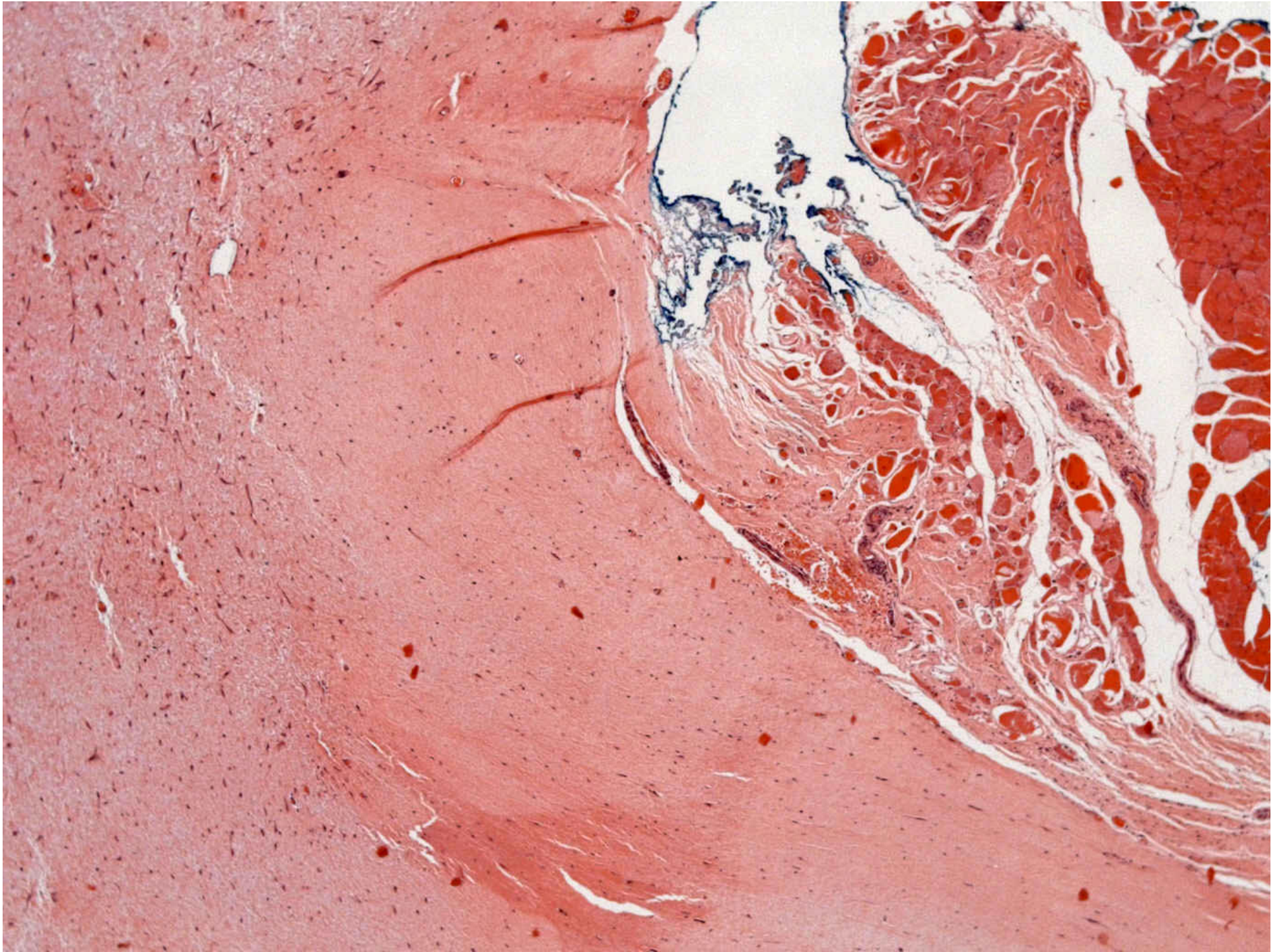


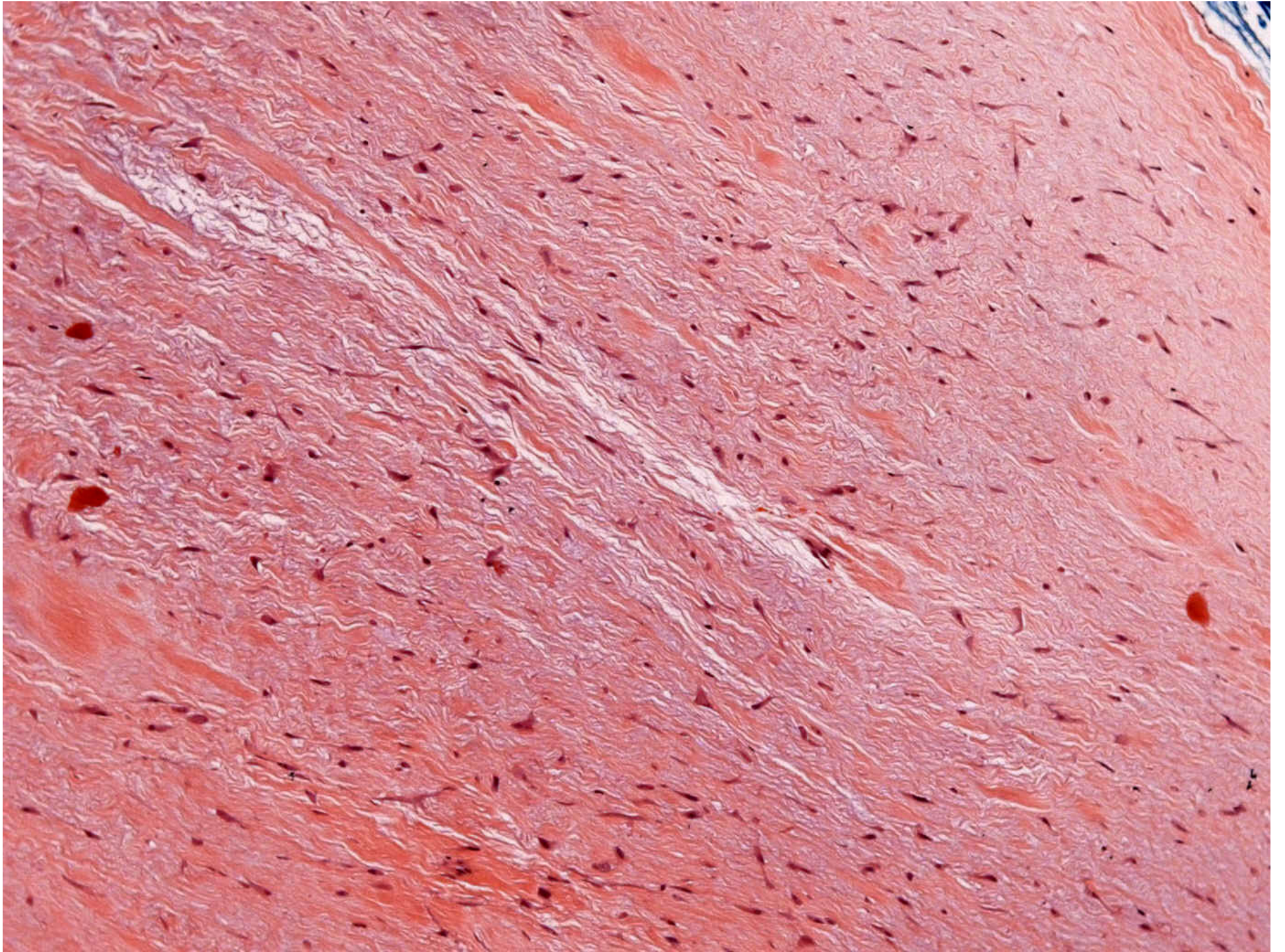


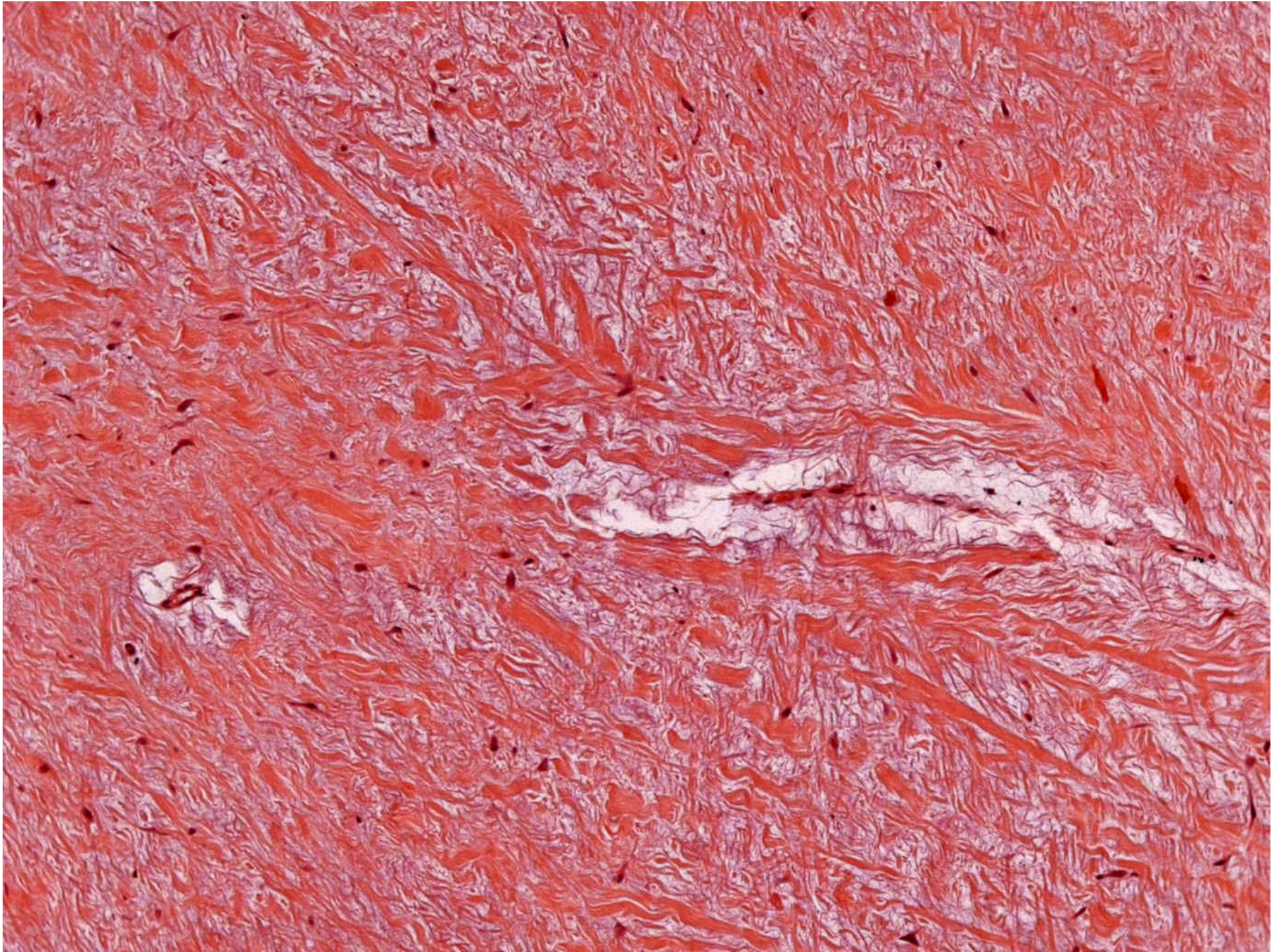


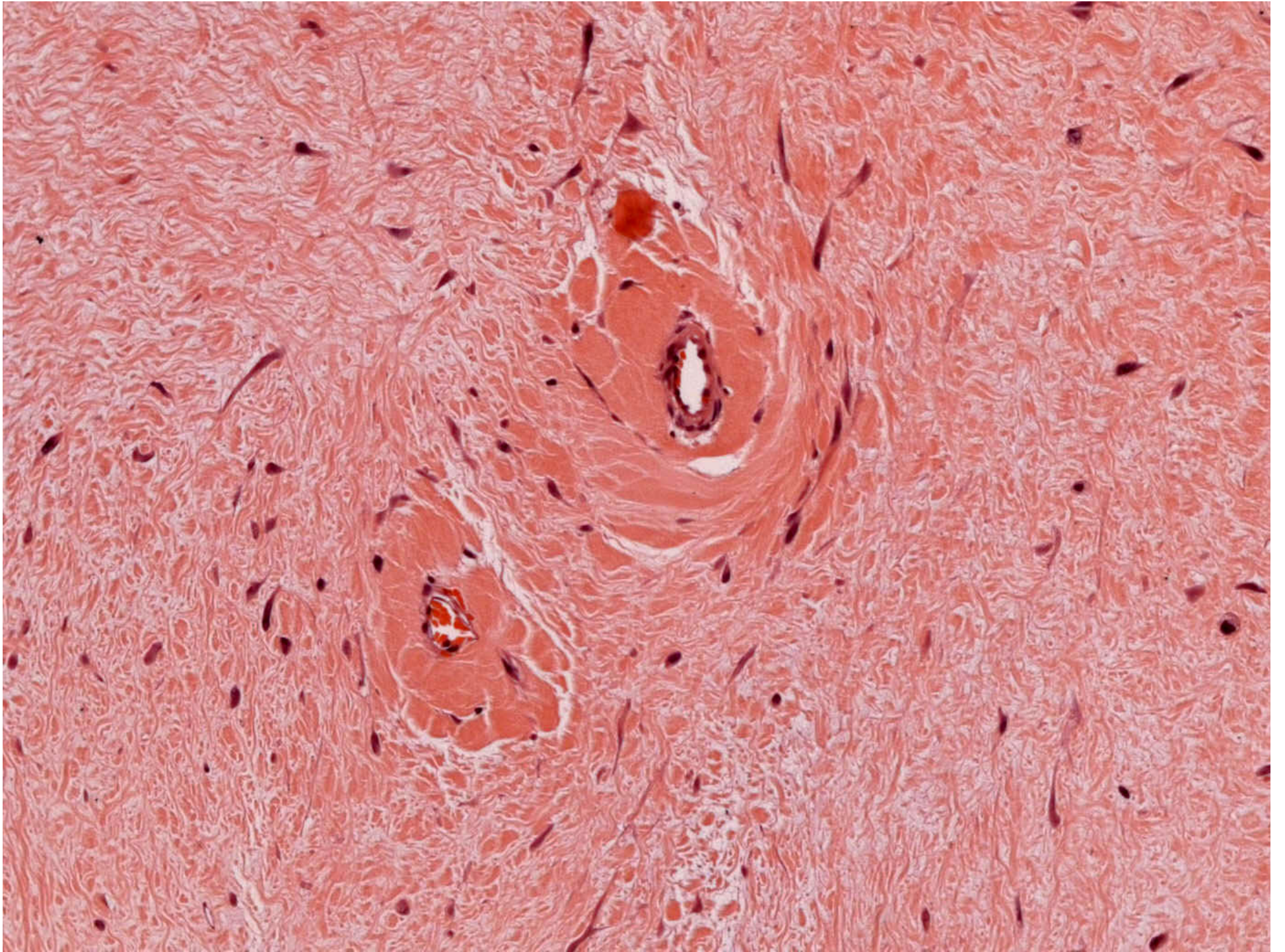


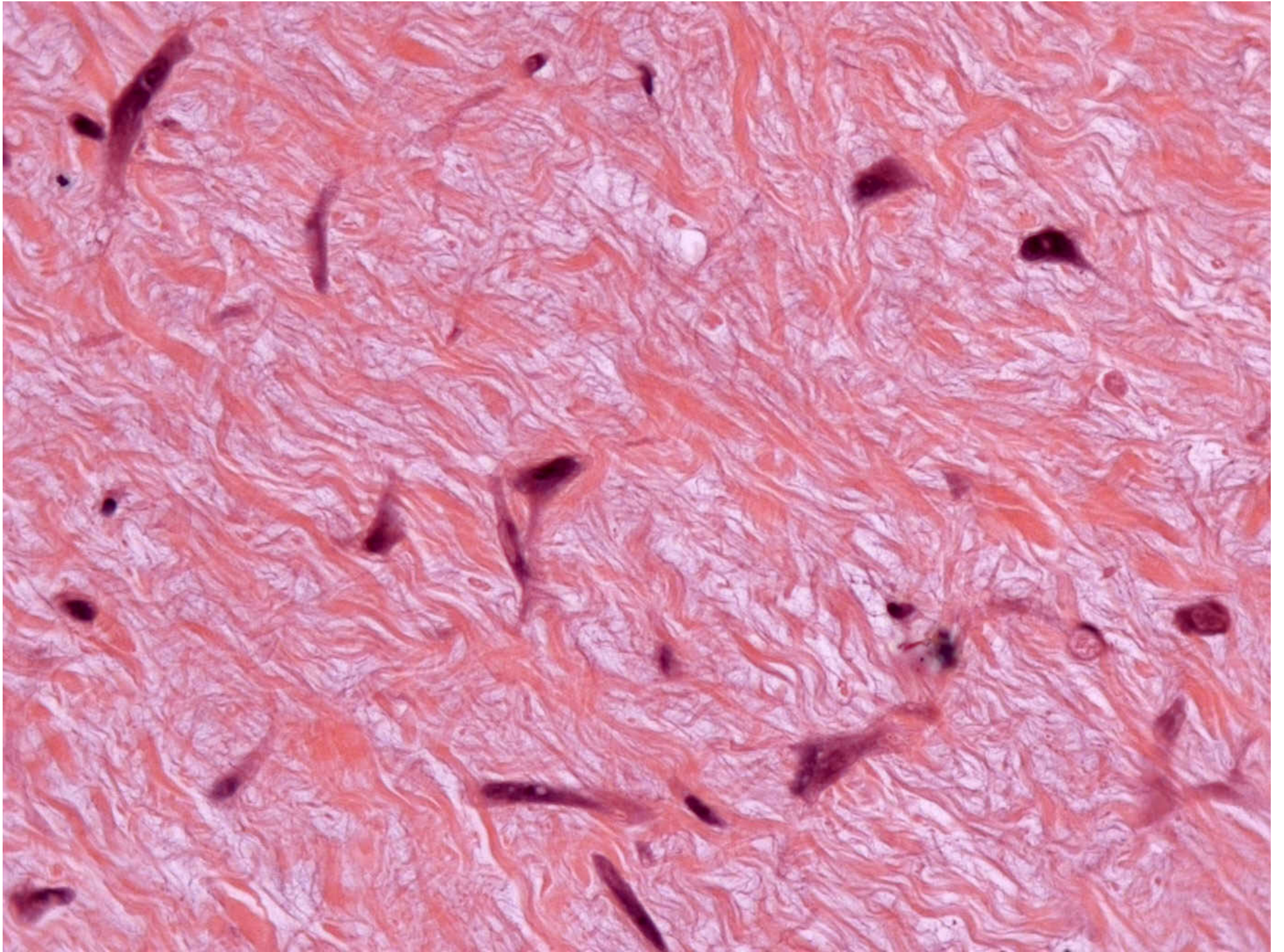


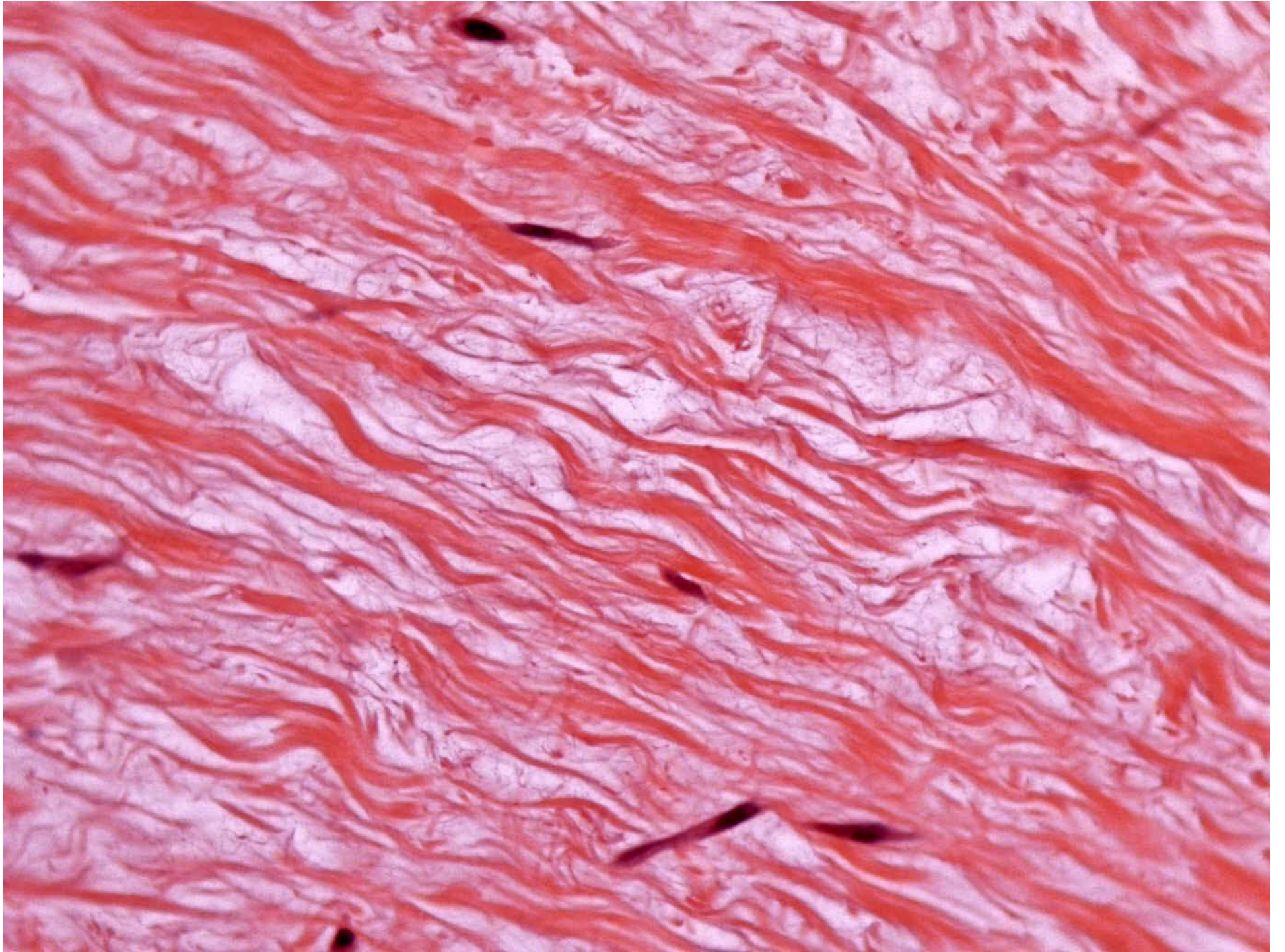


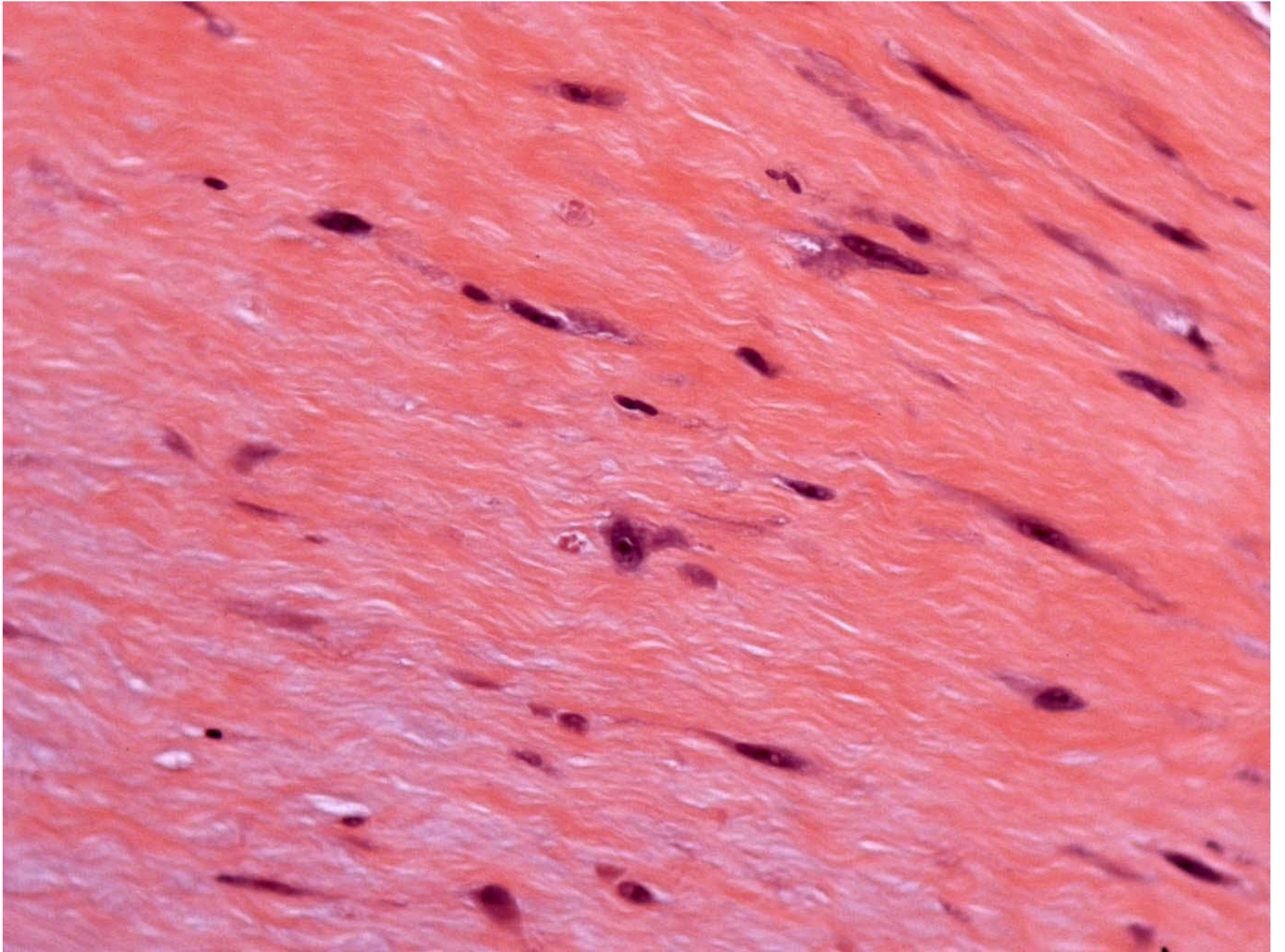


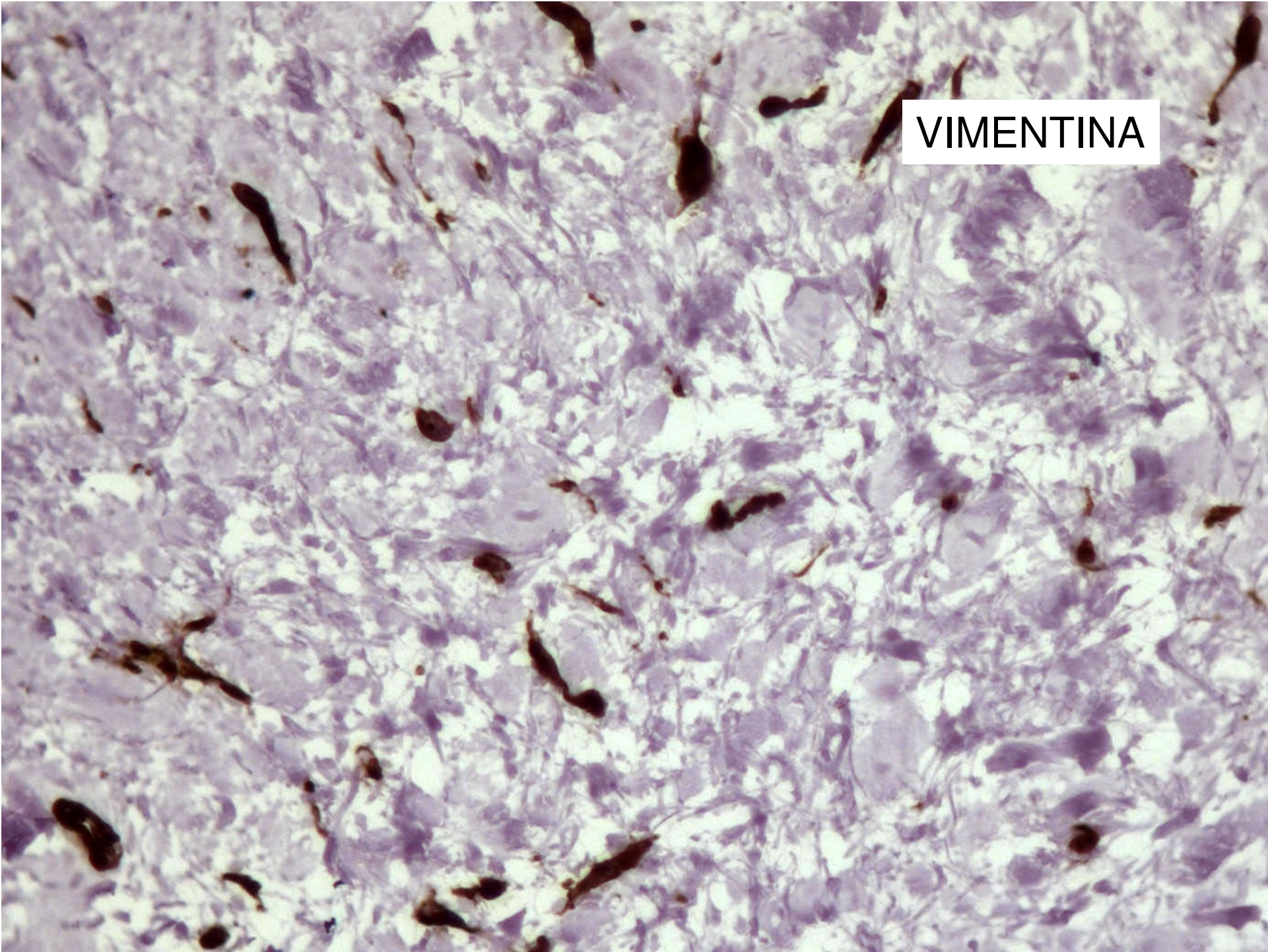






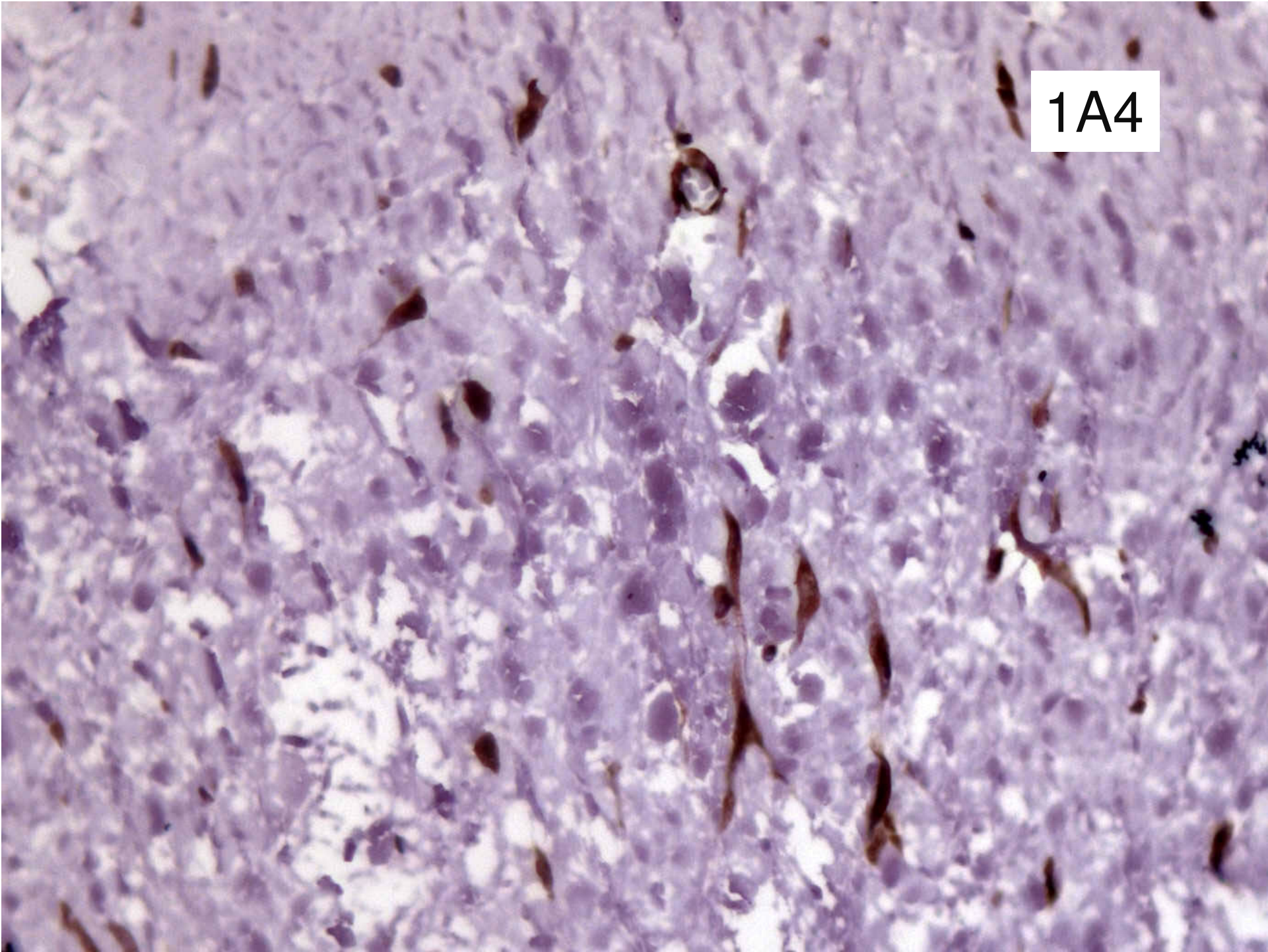






VIMENTINA

1A4



Outros marcadores

- ◆ Proteína S-100 neg.
- ◆ CD 34 neg.
- ◆ HHF-35 neg.
- ◆ HMB-45 neg.

DIAGNÓSTICO ?

DIAGNÓSTICO

FIBROBLASTOMA DESMOPLÁSICO
(fibroma colagênico)

1: [Hum Pathol](#). 1998 Jul;29(7):676-82.

Collagenous fibroma (desmoplastic fibroblastoma): a clinicopathologic analysis of 63 cases of a distinctive soft tissue lesion with stellate-shaped fibroblasts.

[Miettinen M](#), [Fetsch JF](#).

Armed Forces Institute of Pathology, Department of Soft Tissue Pathology, Washington, DC 20306-6000, USA.

Faixa Etária e Gênero

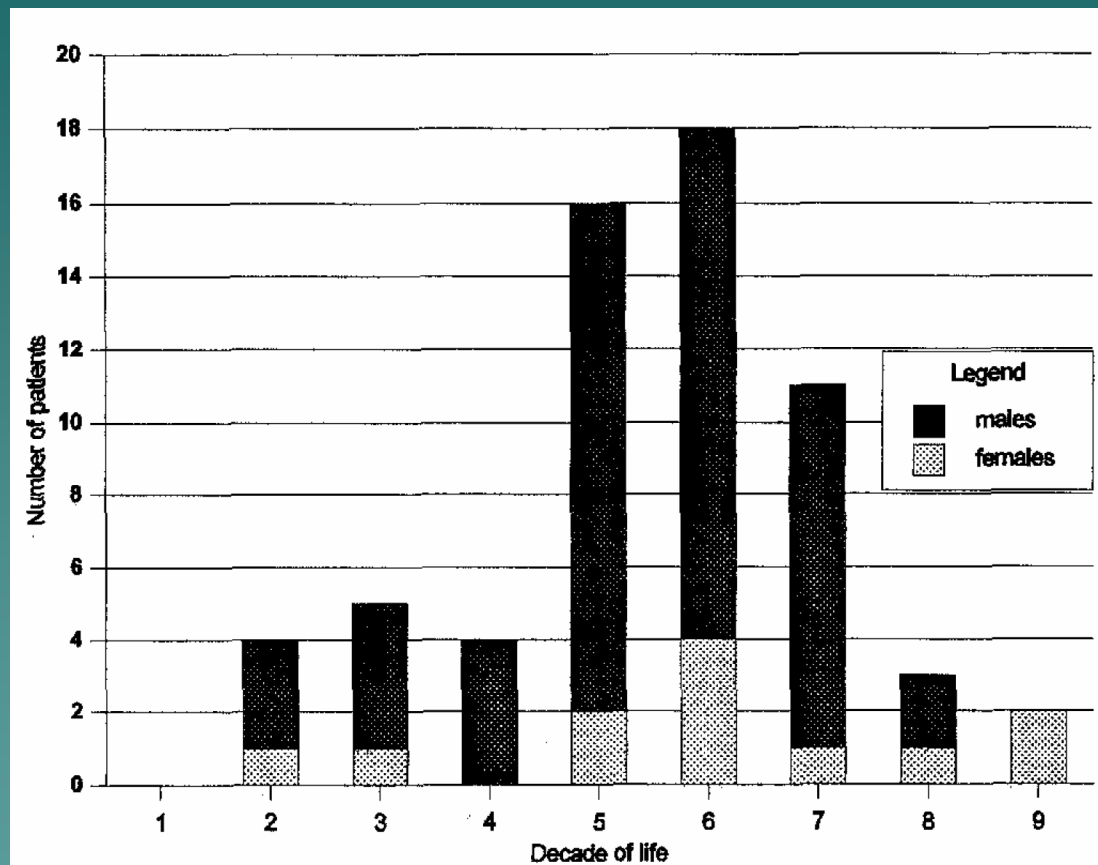
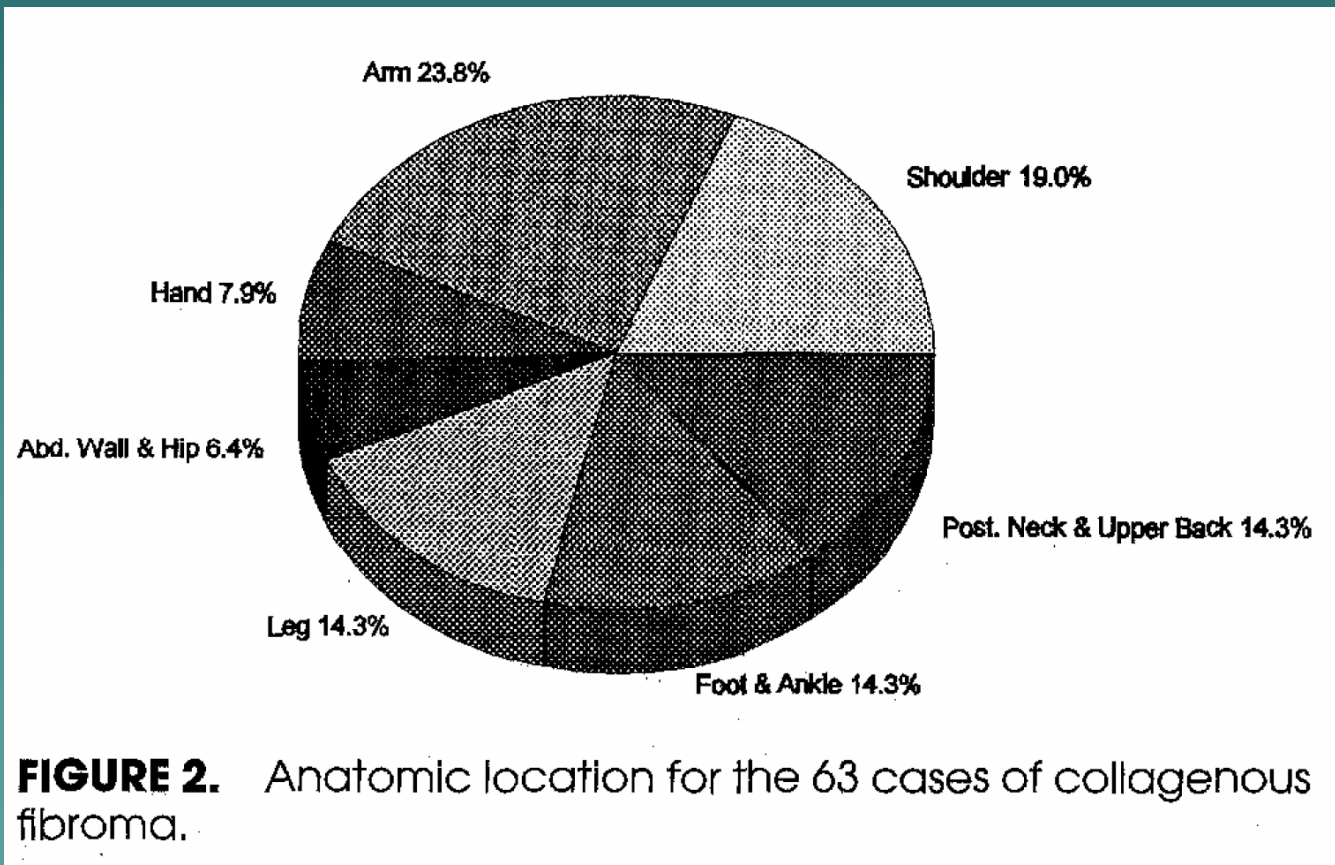


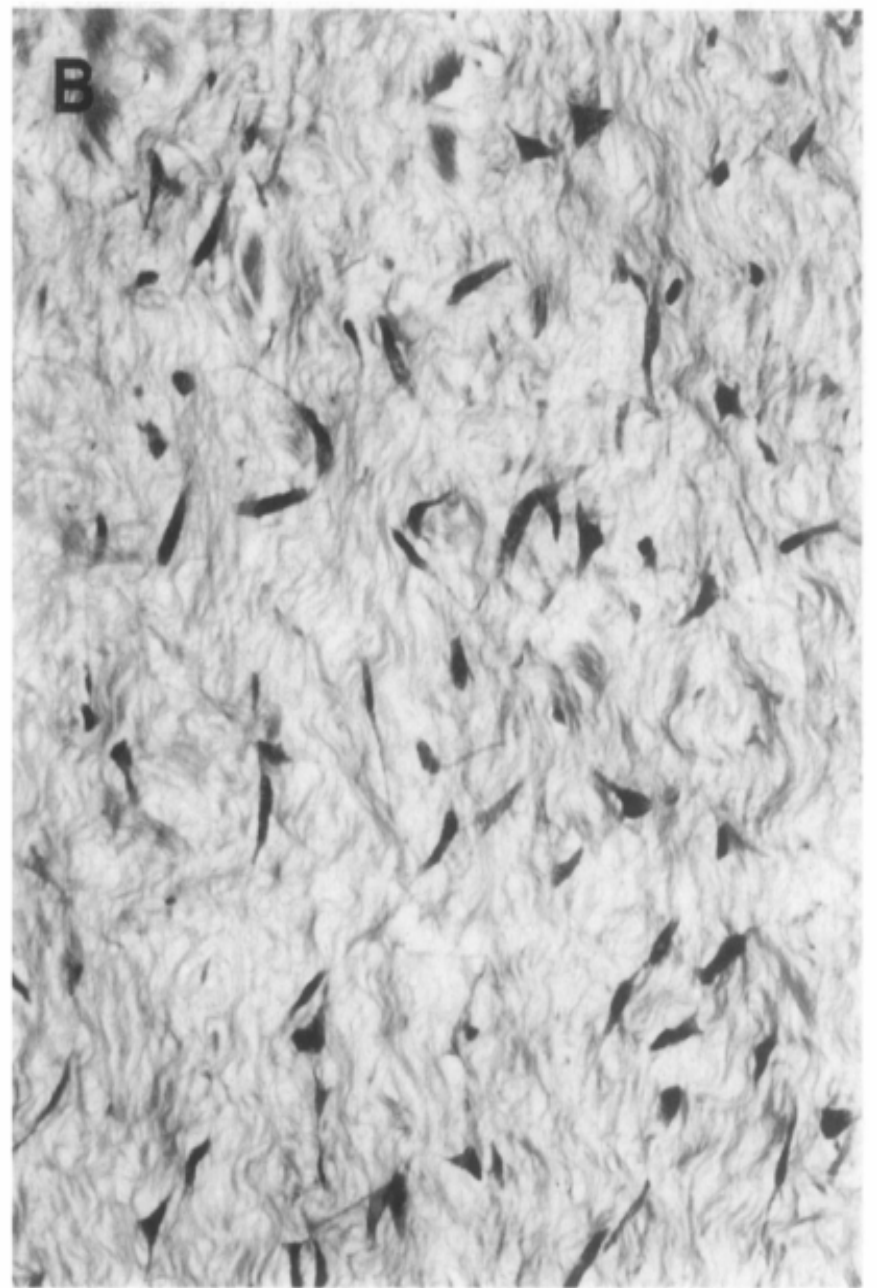
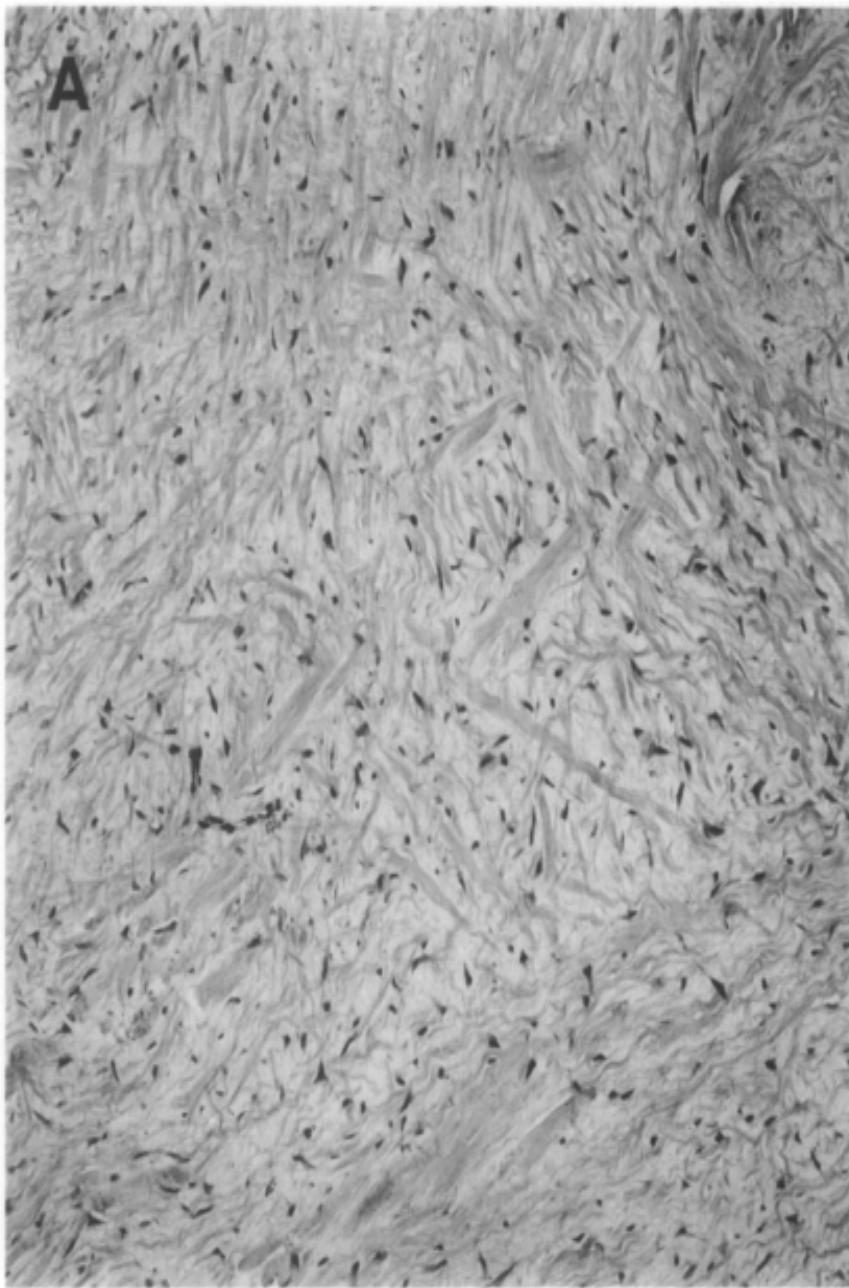FIGURE 1. Age and sex distribution of 63 patients with collagenous fibroma.

Localização Anatômica



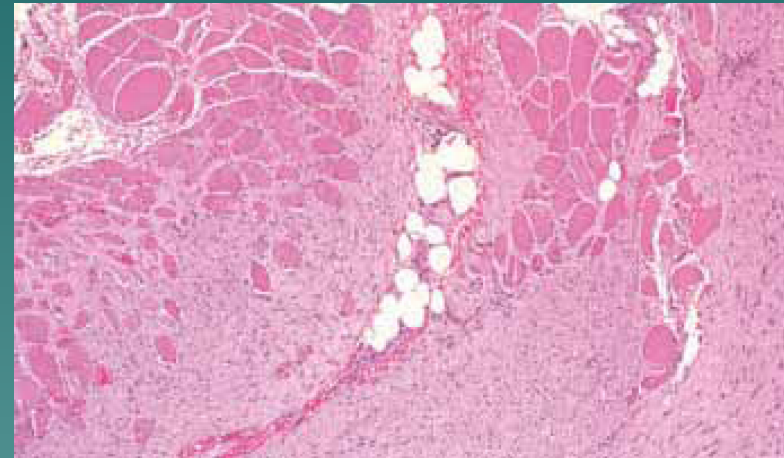
Macroscopia

- ◆ Tamanho: 1 a 20 cm (2/3 entre 2 e 4 cm).
- ◆ Fusiforme, oval, discóide.
- ◆ Subcutâneo.
- ◆ Tecido branco, "perolado", firme (consistência de cartilagem).

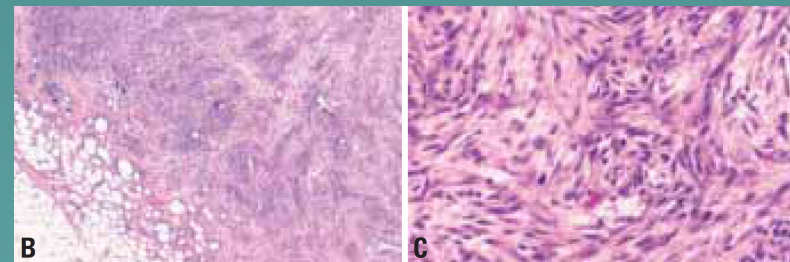


Diagnósticos Diferenciais

- ◆ Fibromatose desmóide



- ◆ Fasciíte nodular



Diagnósticos Diferenciais

- ◆ Fibroma do tendão
- ◆ Fibroma nocal
- ◆ Neurofibroma
- ◆ Mixoma

1: [J Oral Pathol Med](#). 1999 Nov;28(10):465-8.

Collagenous fibroma (desmoplastic fibroblastoma) presenting as a parotid mass.

[Ide F](#), [Shimoyama T](#), [Horie N](#), [Tanaka H](#).

Department of Oral Surgery, Saitama Medical Center, Saitama Medical School, Kawagoe, Japan.

1: [Oral Surg Oral Med Oral Pathol Oral Radiol Endod](#). 2001 Jan;91(1):80-4.

Collagenous fibroma (desmoplastic fibroblastoma) of the palate: a case report.

[Mesquita RA](#), [Okuda E](#), [Jorge WA](#), [de Araújo VC](#).

Department of Oral Pathology, São Paulo University, Brazil.

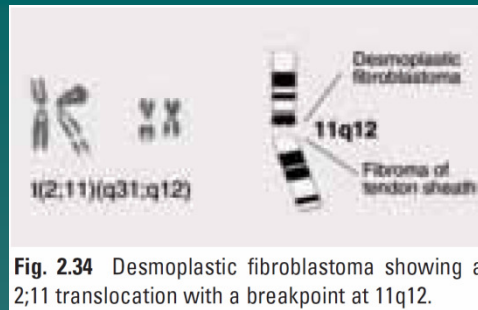


Fig. 2.34 Desmoplastic fibroblastoma showing a 2;11 translocation with a breakpoint at 11q12.

1: [Mod Pathol.](#) 1999 Jun;12(6):565-8.

Collagenous fibroma (desmoplastic fibroblastoma): genetic link with fibroma of tendon sheath?

[Sciot R](#), [Samson I](#), [van den Berghe H](#), [Van Damme B](#), [Dal Cin P](#).

Department of Pathology, University of Leuven, Belgium. raf.sciot@uz.kuleuven.ac.be

1: [Cancer Genet Cytogenet.](#) 2004 Mar;149(2):161-3.

Translocation (2;11)(q31;q12) is recurrent in collagenous fibroma (desmoplastic fibroblastoma).

[Bernal K](#), [Nelson M](#), [Neff JR](#), [Nielsen SM](#), [Bridge JA](#).

Department of Pathology and Microbiology, University of Nebraska Medical Center, Omaha, NE 68198-3135, USA.

1: [Histopathology.](#) 2007 Dec;51(6):859-60. Epub 2007 Sep 25.

Desmoplastic fibroblastoma (collagenous fibroma) with a specific breakpoint of 11q12.

[Sakamoto A](#), [Yamamoto H](#), [Yoshida T](#), [Tanaka K](#), [Matsuda S](#), [Oda Y](#), [Tsuneyoshi M](#), [Iwamoto Y](#).

PMID: 17894801 [PubMed - indexed for MEDLINE]

CASO DO MÊS

Agradecemos a sua participação.

