

# CASO DO MÊS SBP

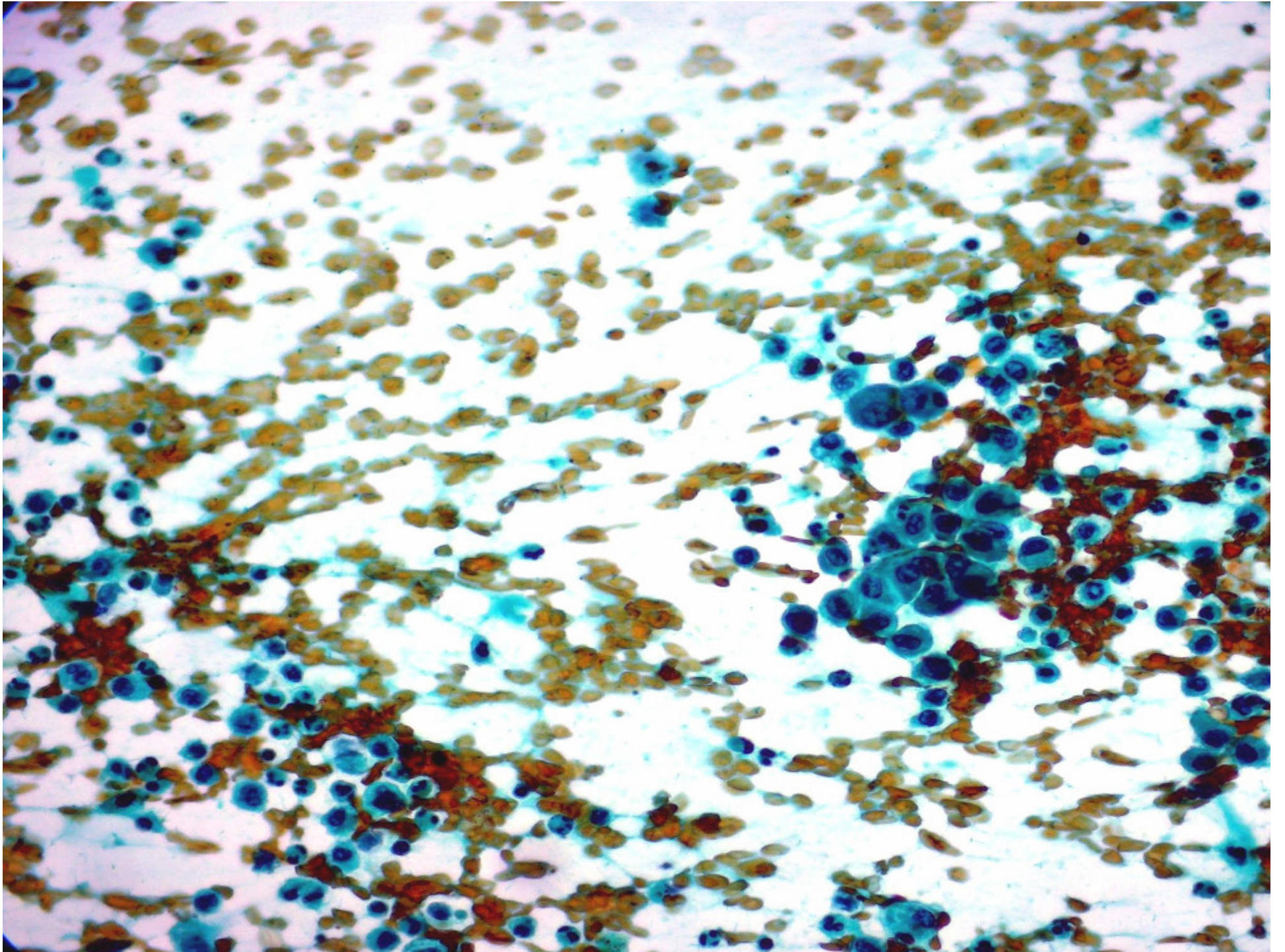


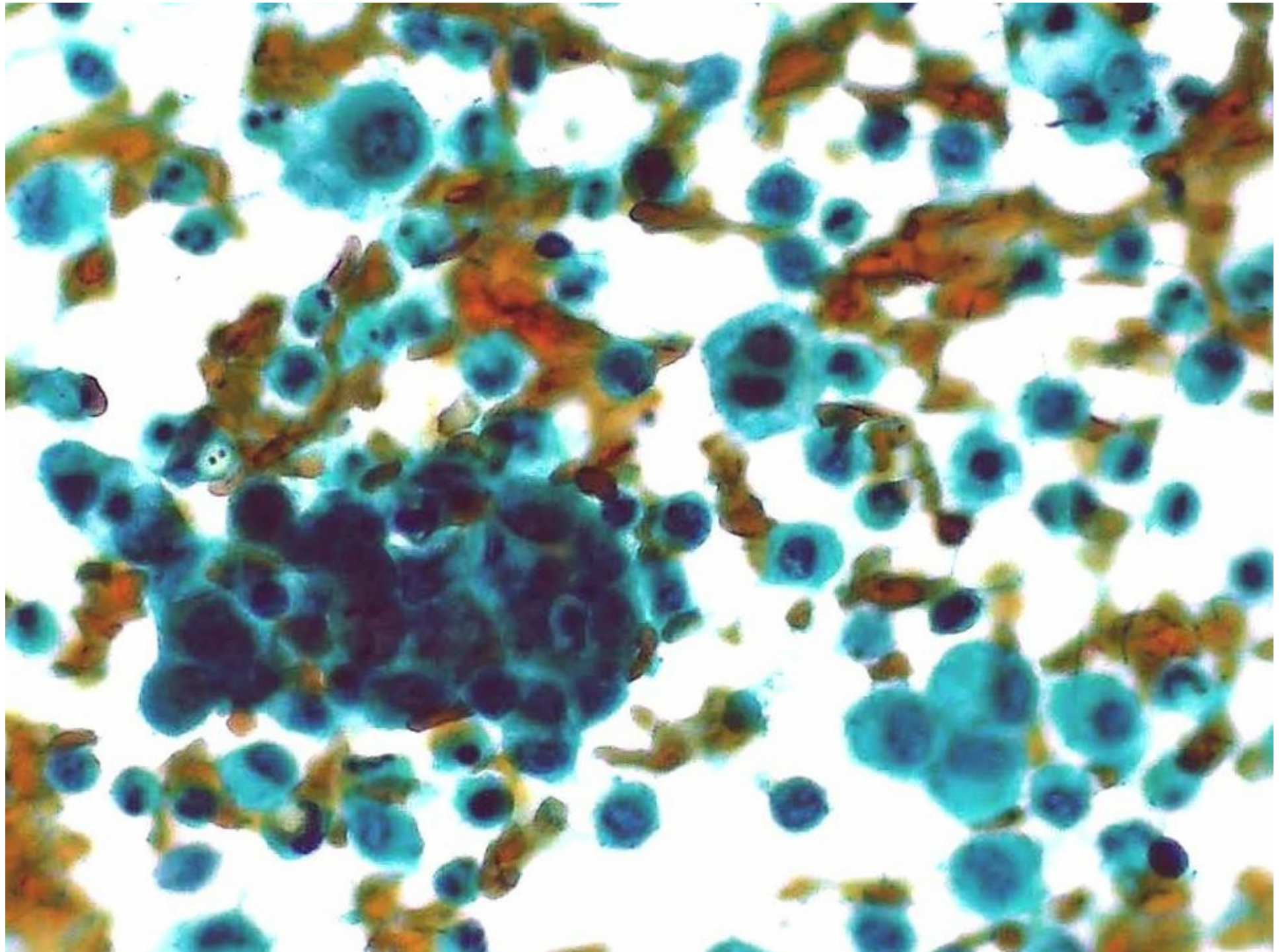
Dr. Altino Luiz S. Therezo

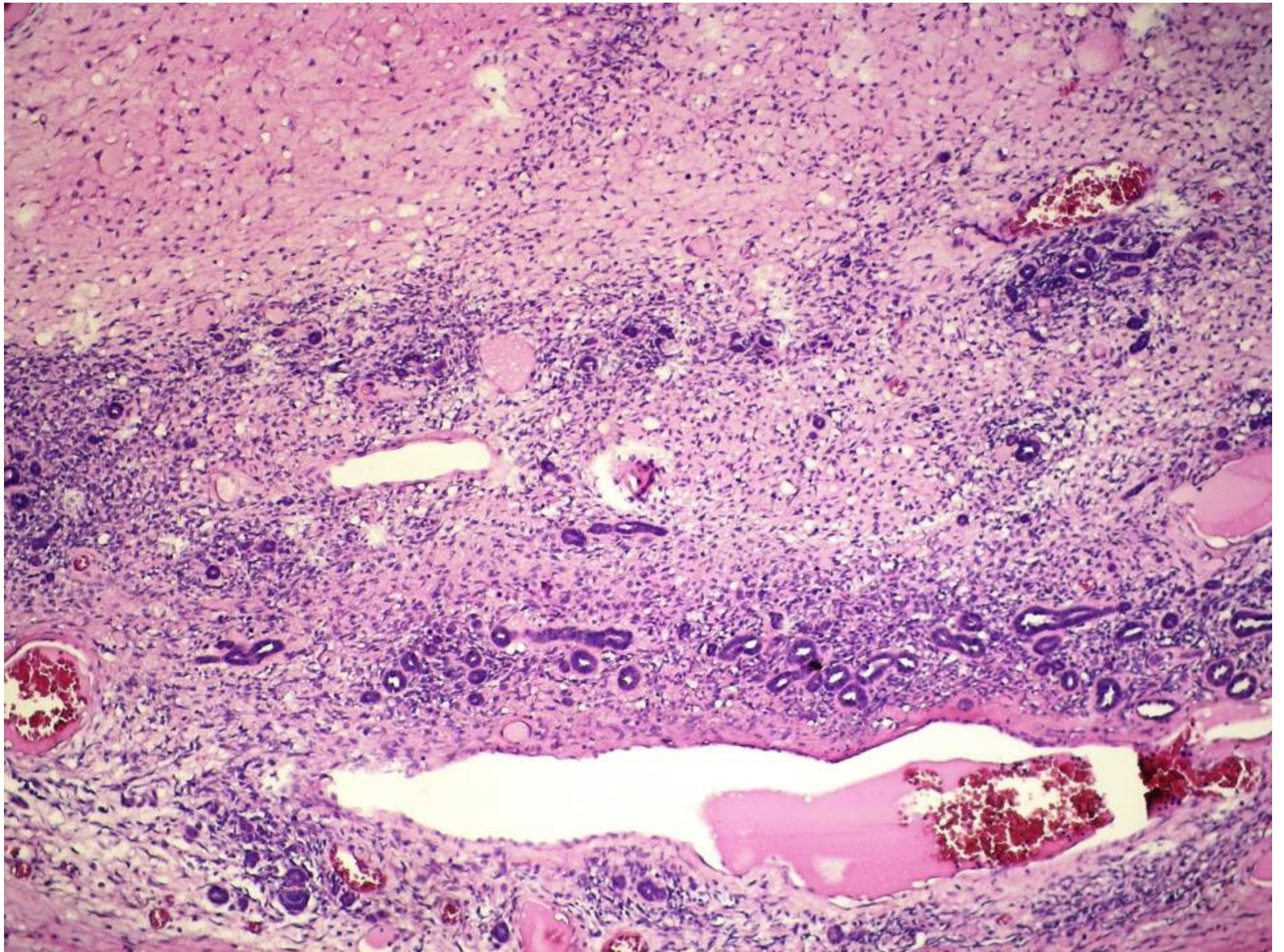
Dr. Luis Carlos da Silva

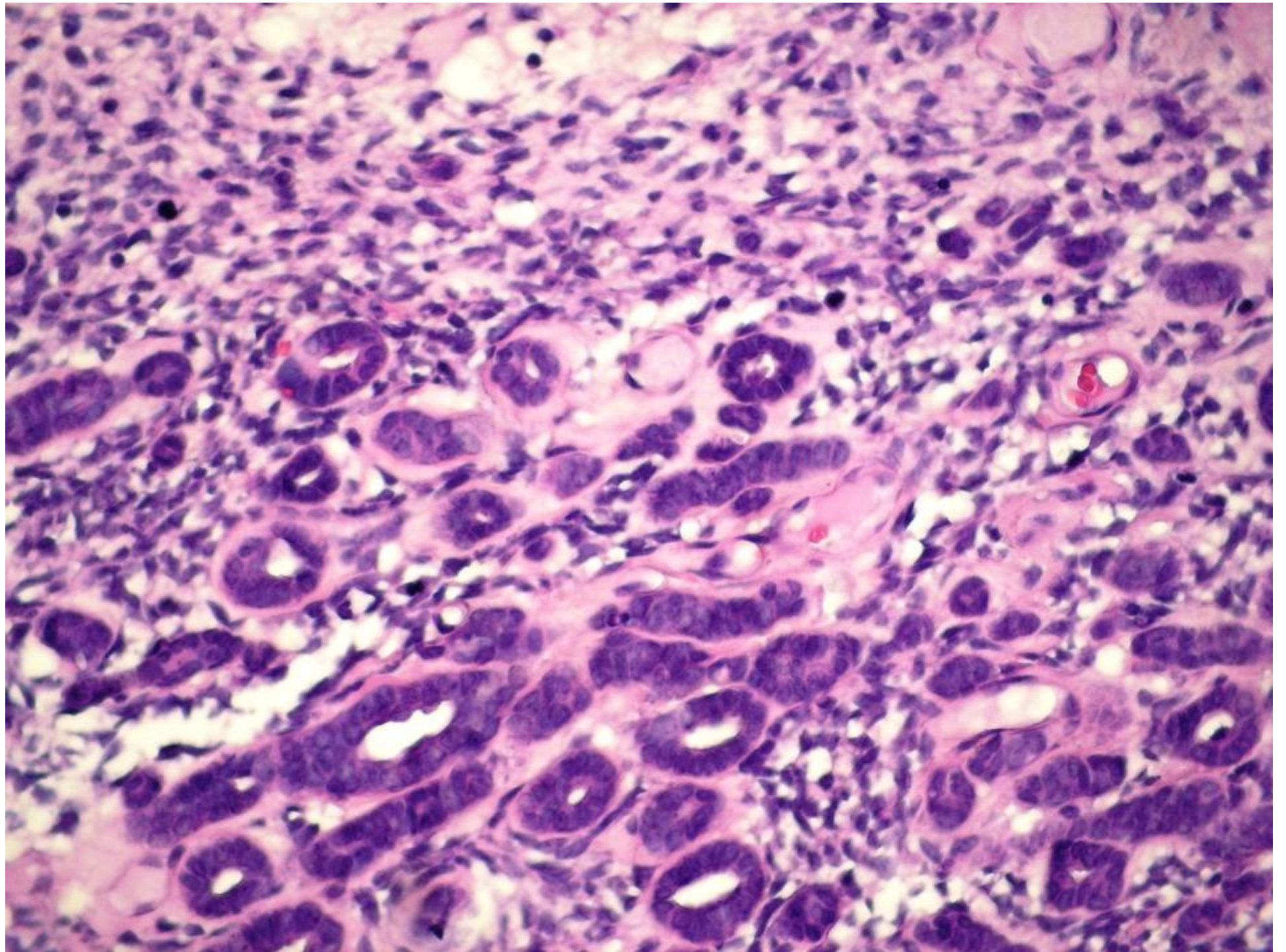
# Dados clínicos

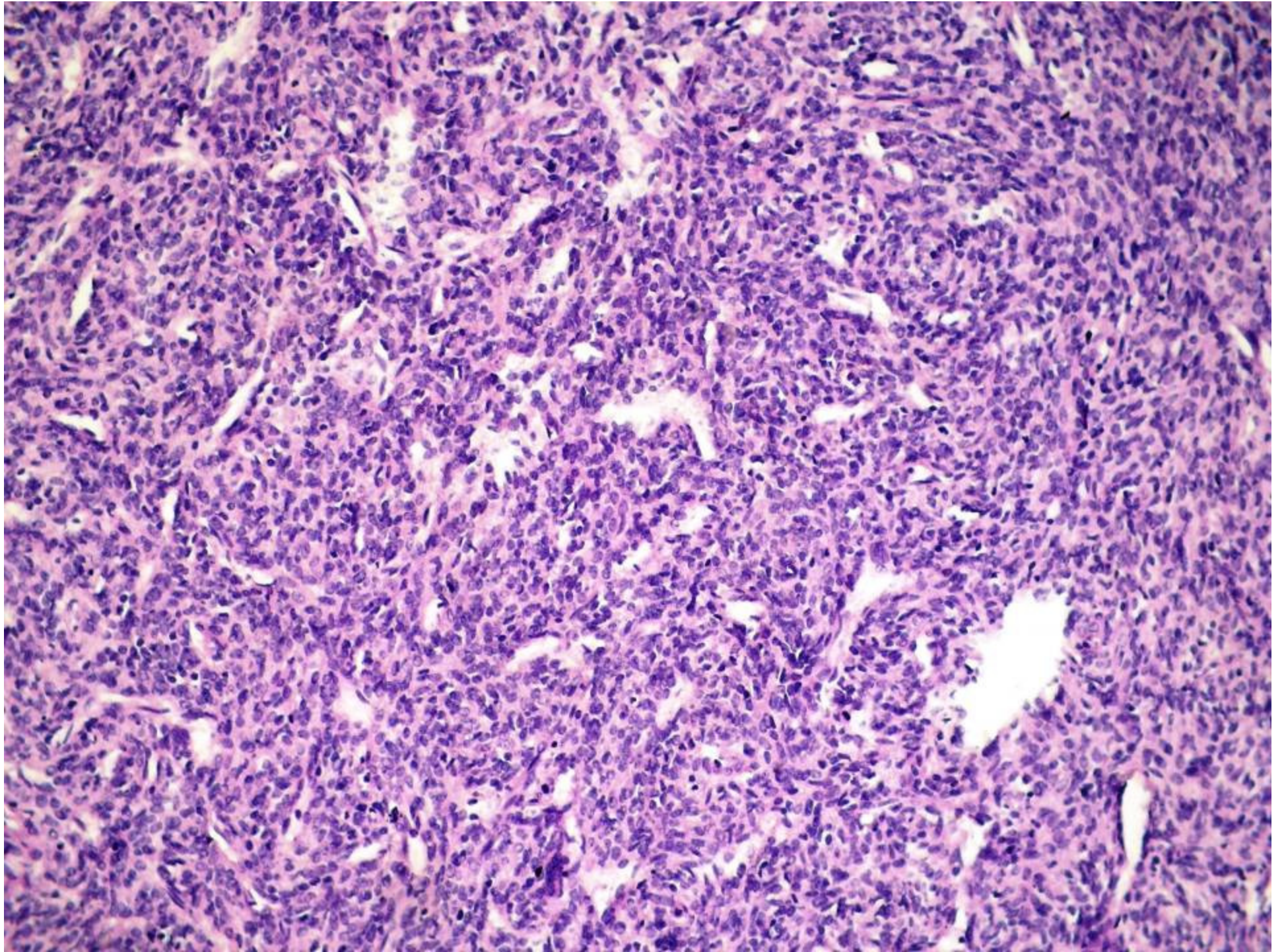
- Paciente feminina, de 12 anos de idade, com sinais de virilização.
- Emagrecimento.
- Líquido peritoneal: malignidade.
- Recidiva tumoral. Passado de massa ovariana

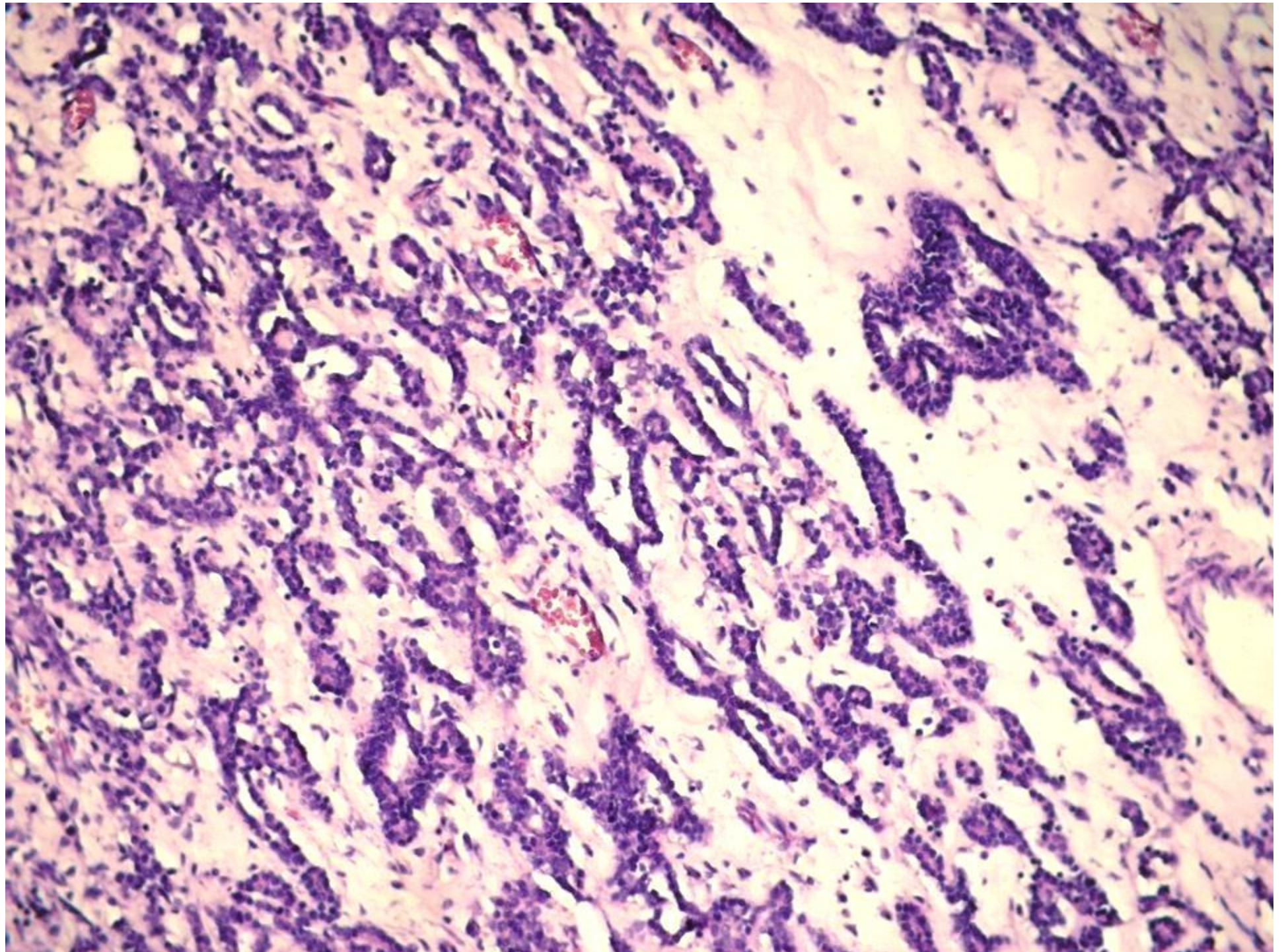




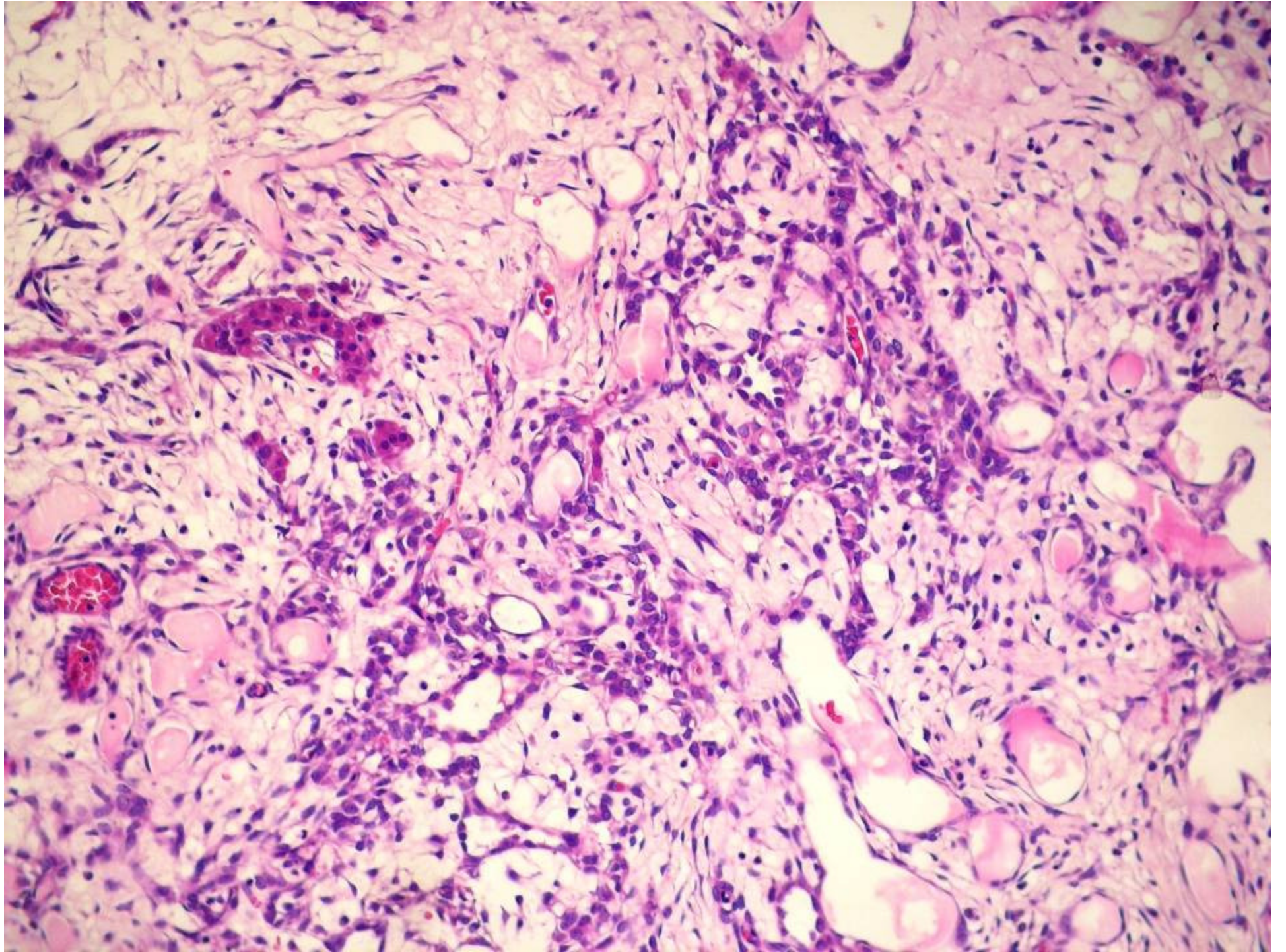


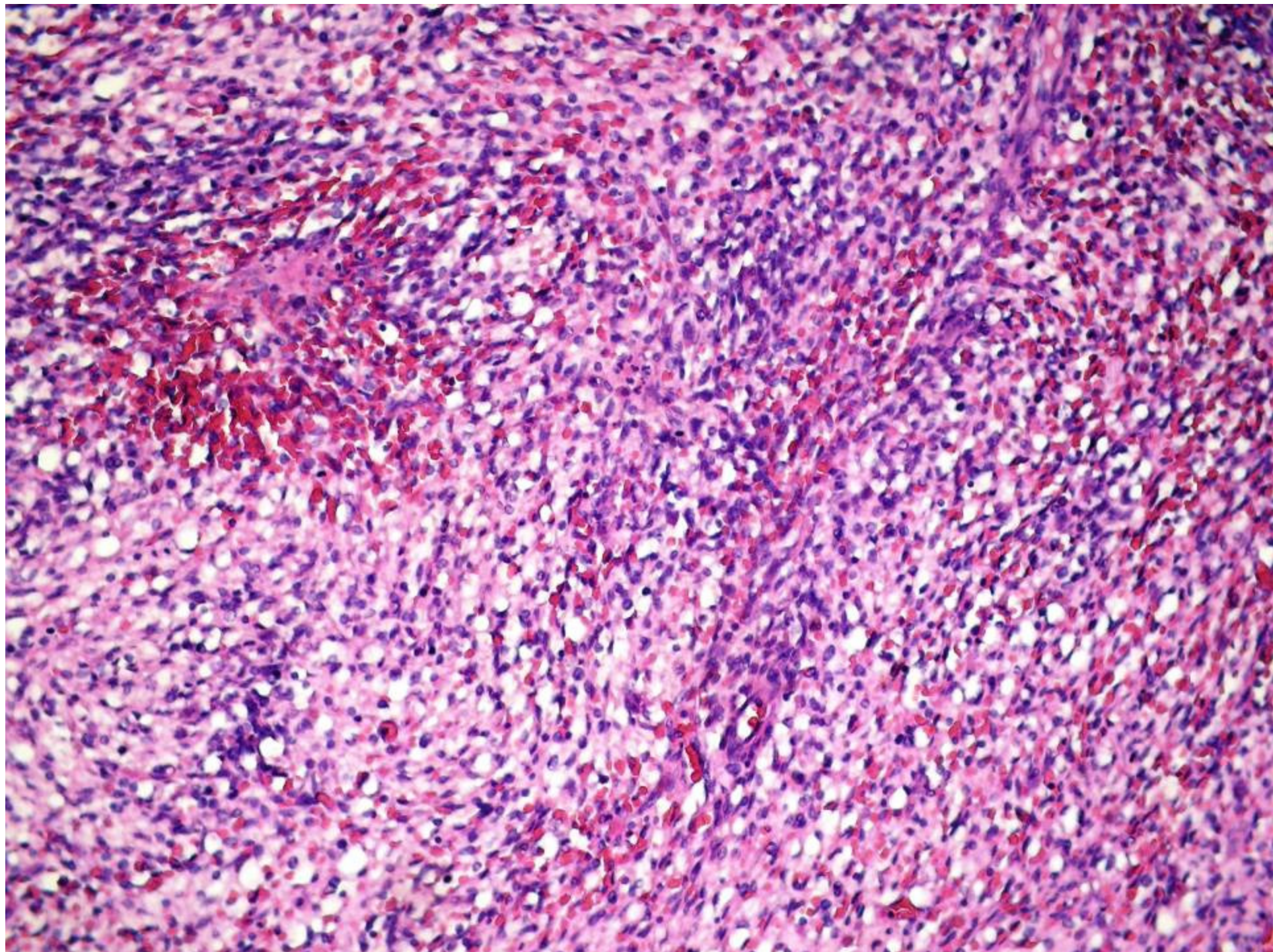


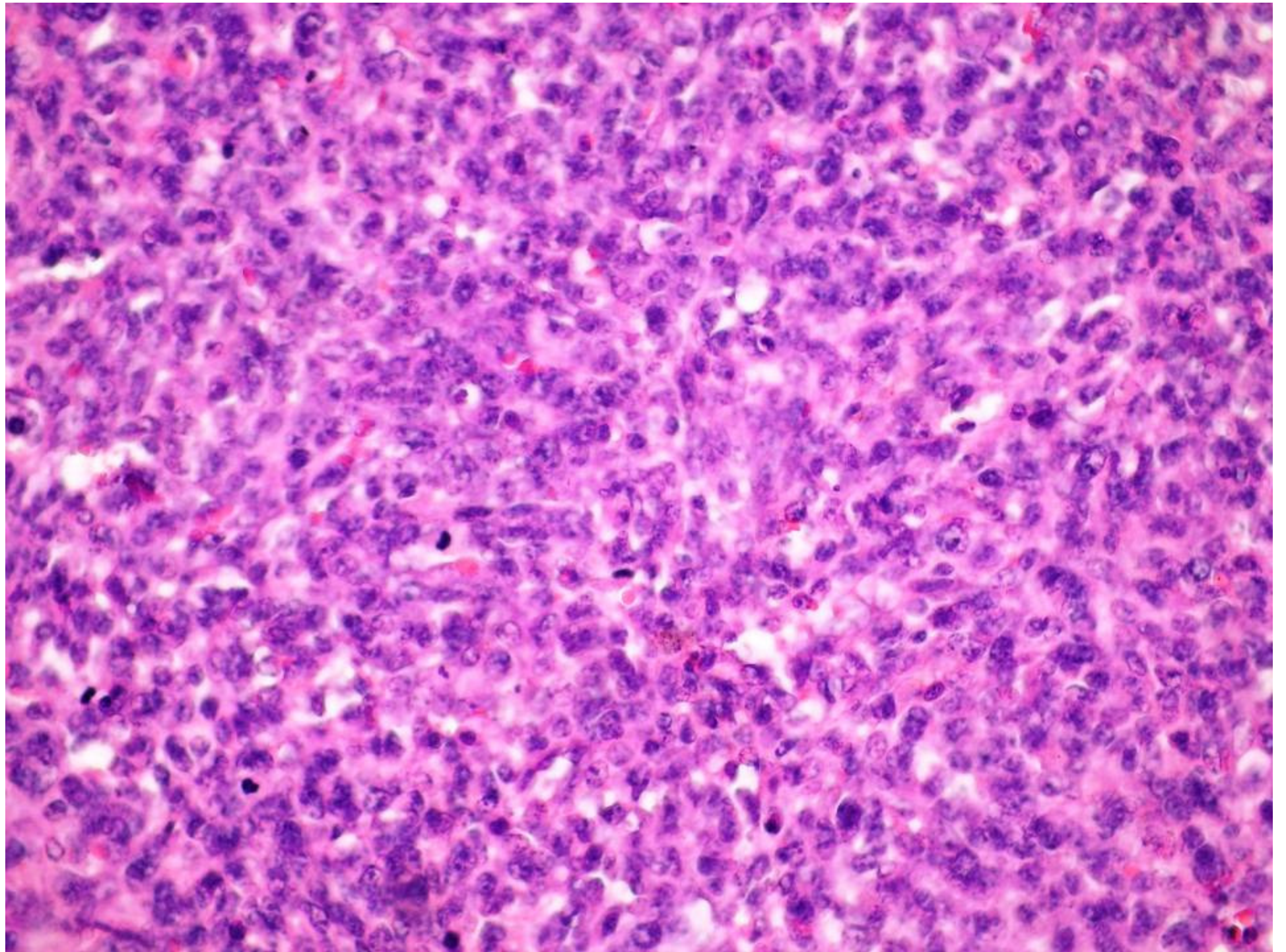


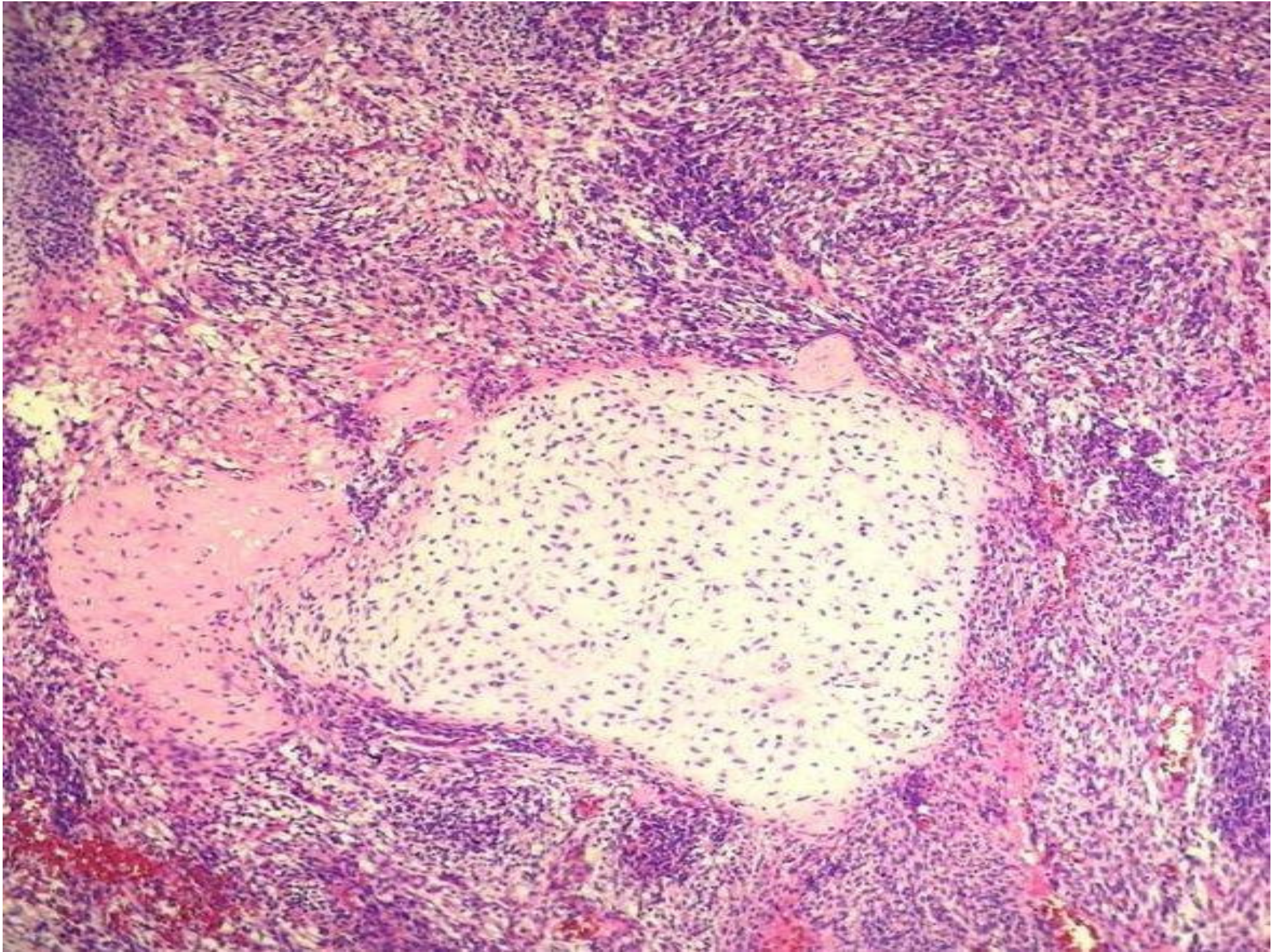


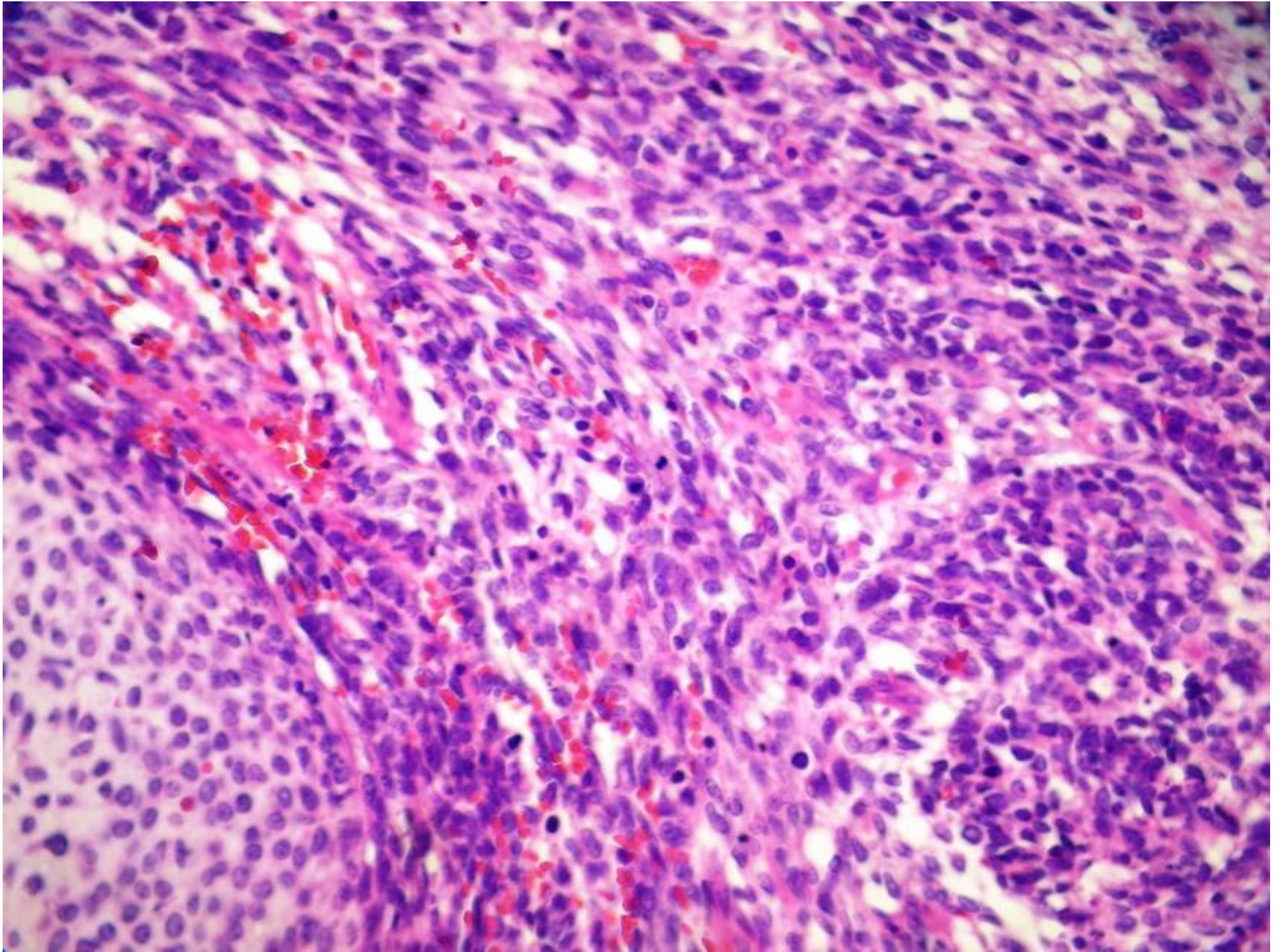












# ESCOLHA O MELHOR DIAGNÓSTICO

- Tumor misto de células germinativas com teratoma imaturo e Yolk sac
- Teratoma imaturo
- Tumor de células de Sertoli-Leydig recidivado, indiferenciado, com componente estromal heterólogo (cartilagem) e áreas sarcomatosas indiferenciadas
- Carcinossarcoma (tumor Mulleriano misto maligno)

# CASO DO MÊS SBP

*Contamos sempre com a  
sua participação.*