



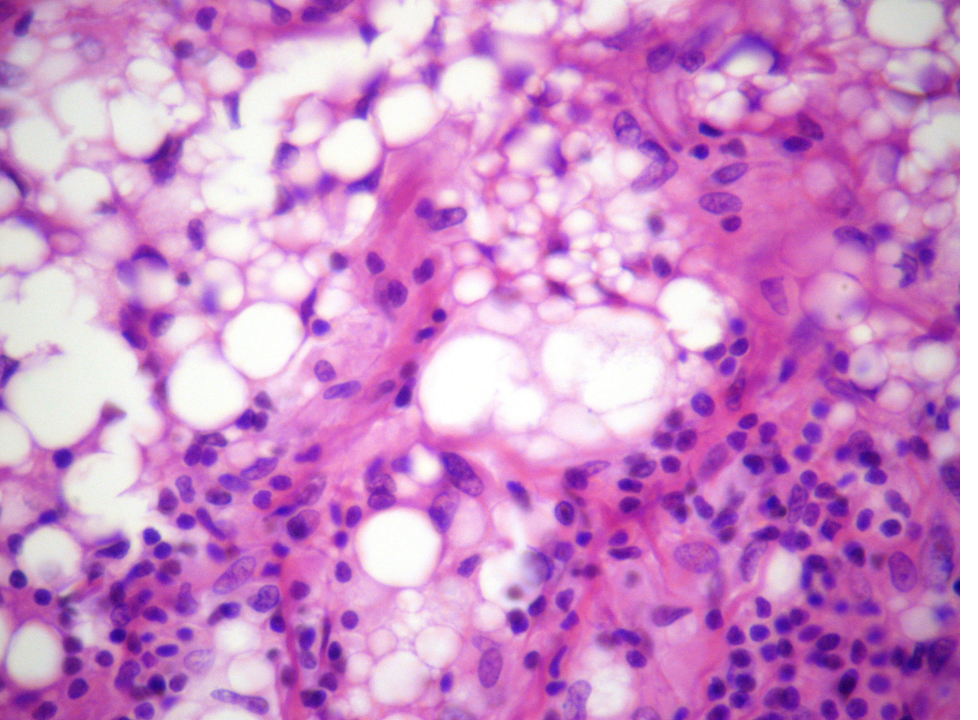
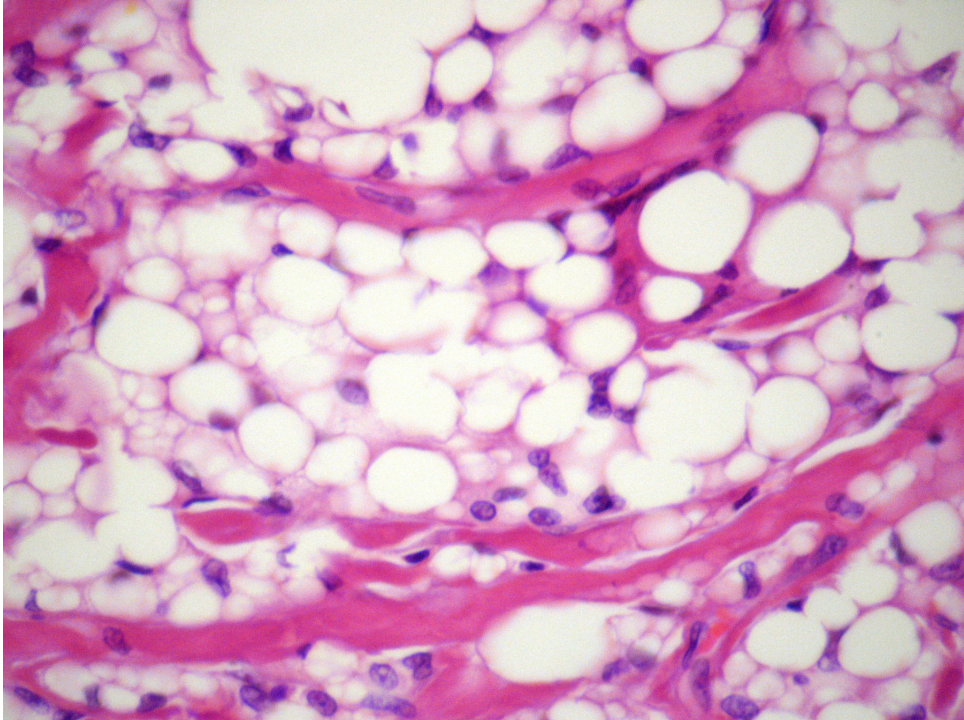
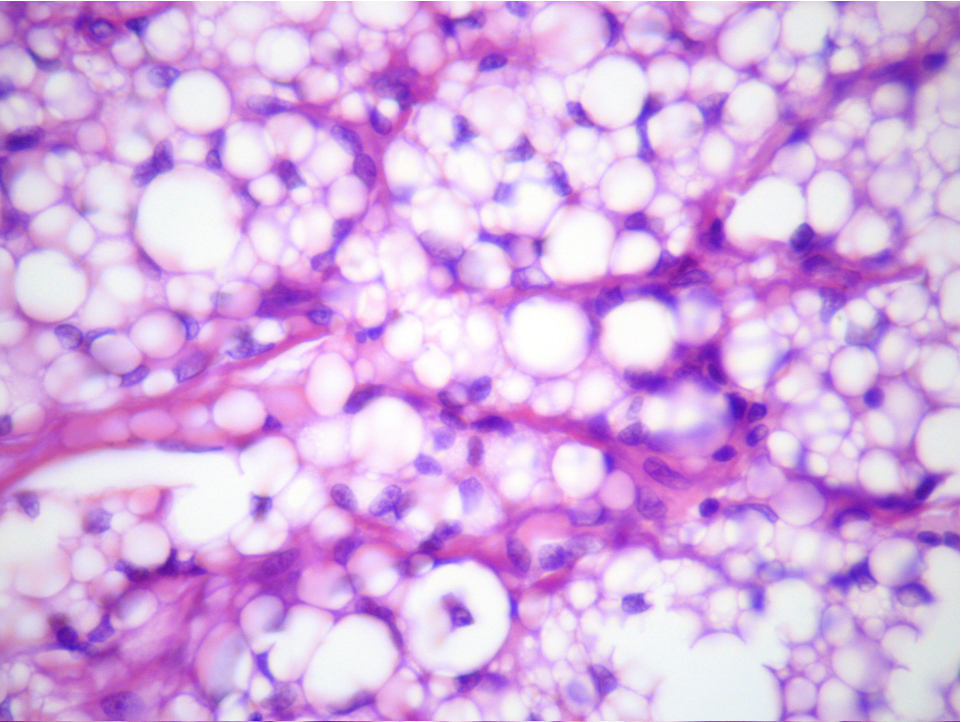
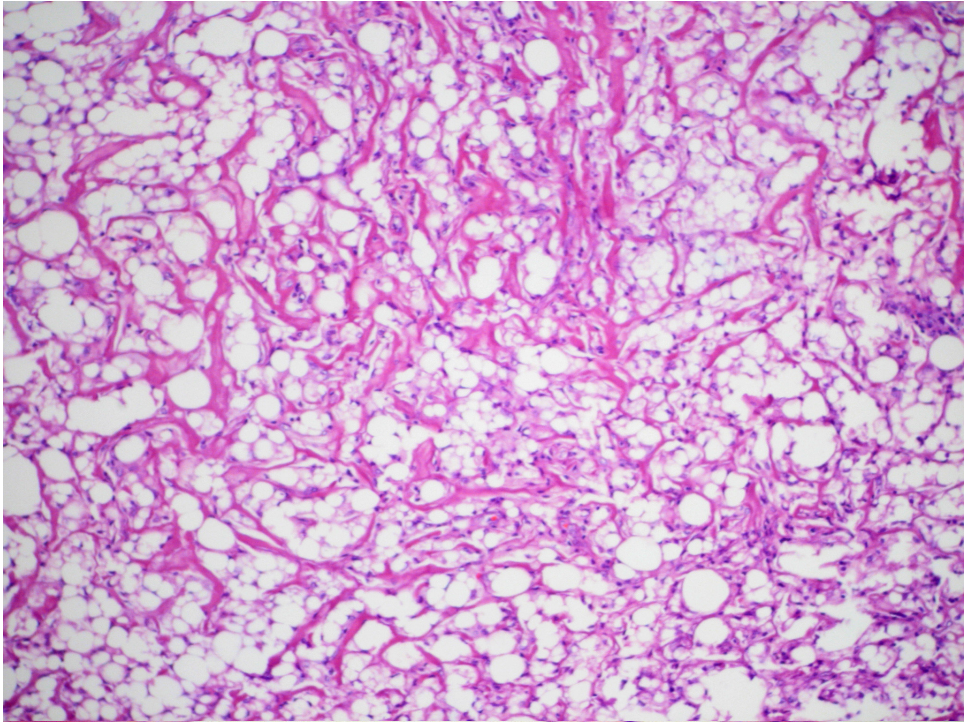
CASO DO MÊS SBP

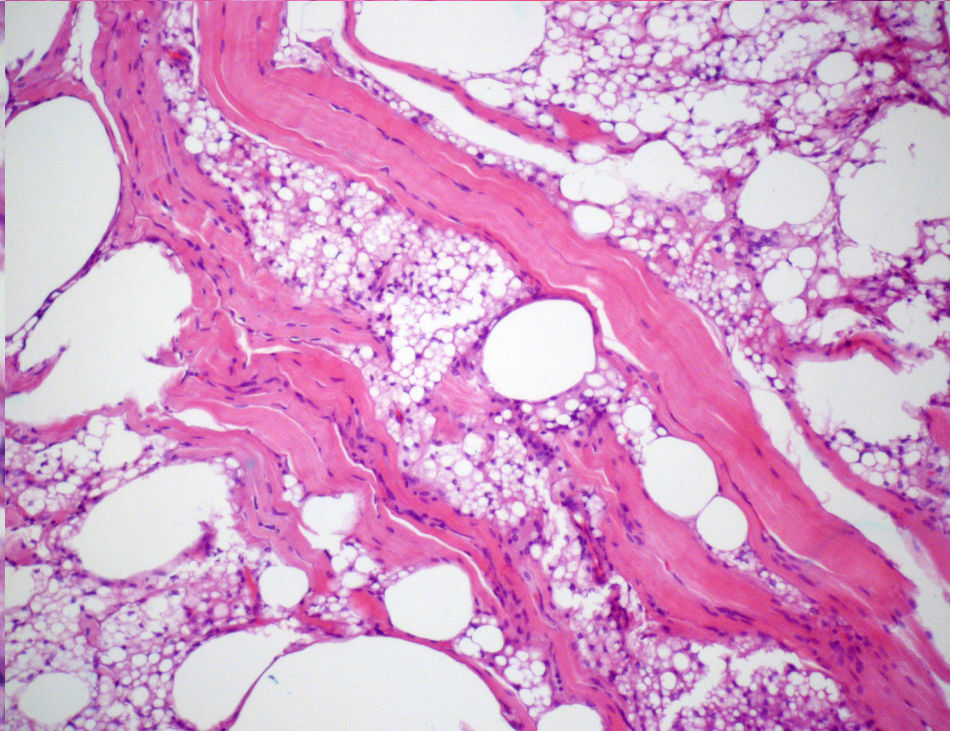
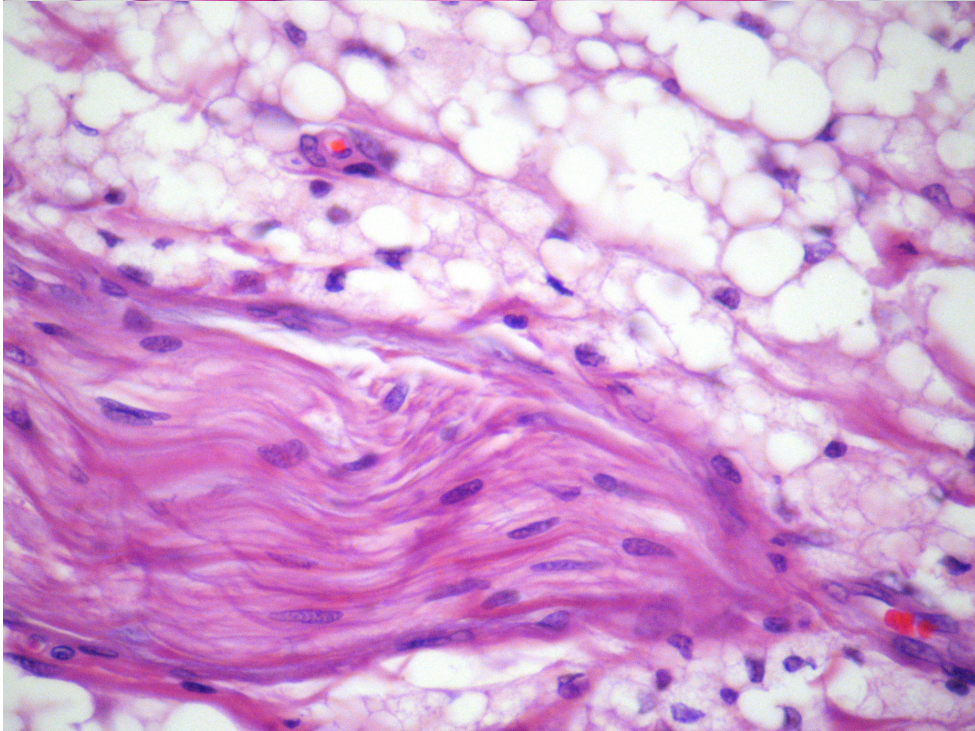
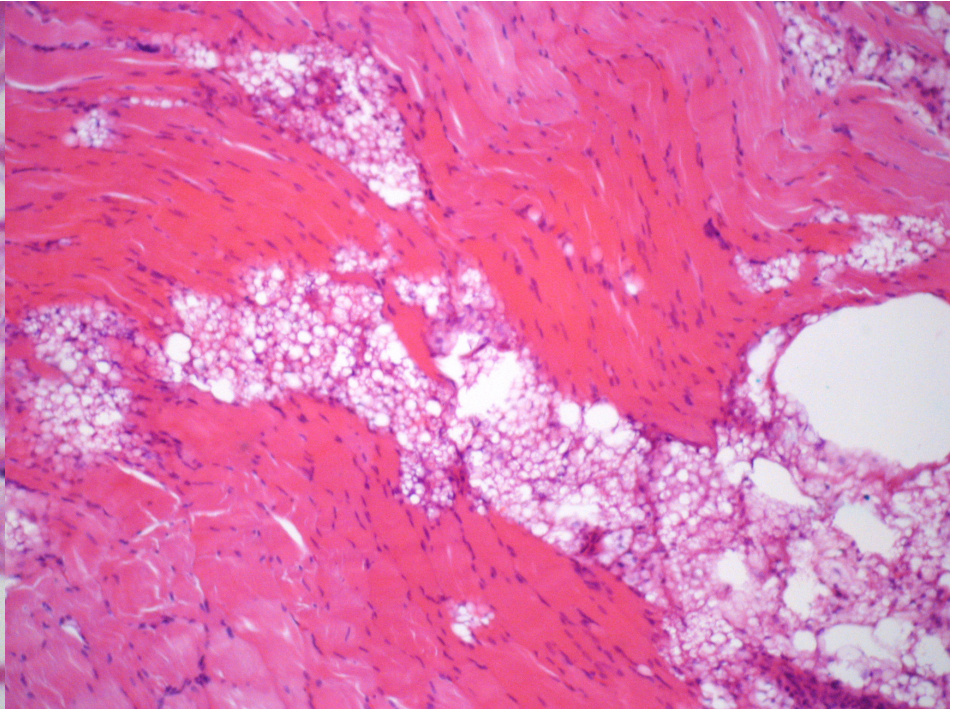
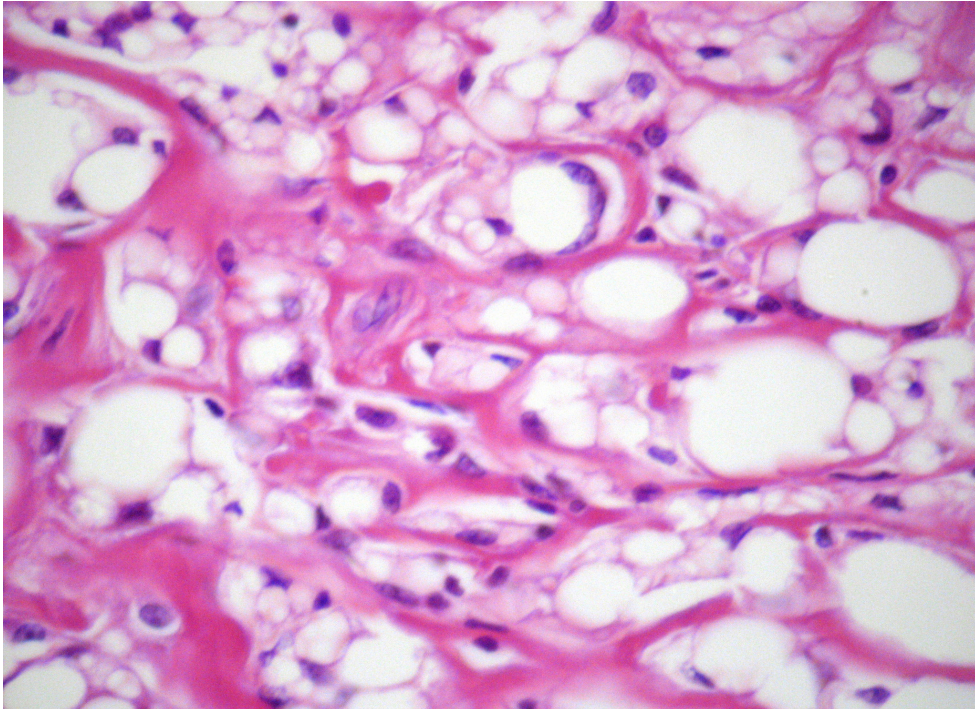
Isabela Conde Watanabe
Salomão e Zoppi Medicina Diagnóstica

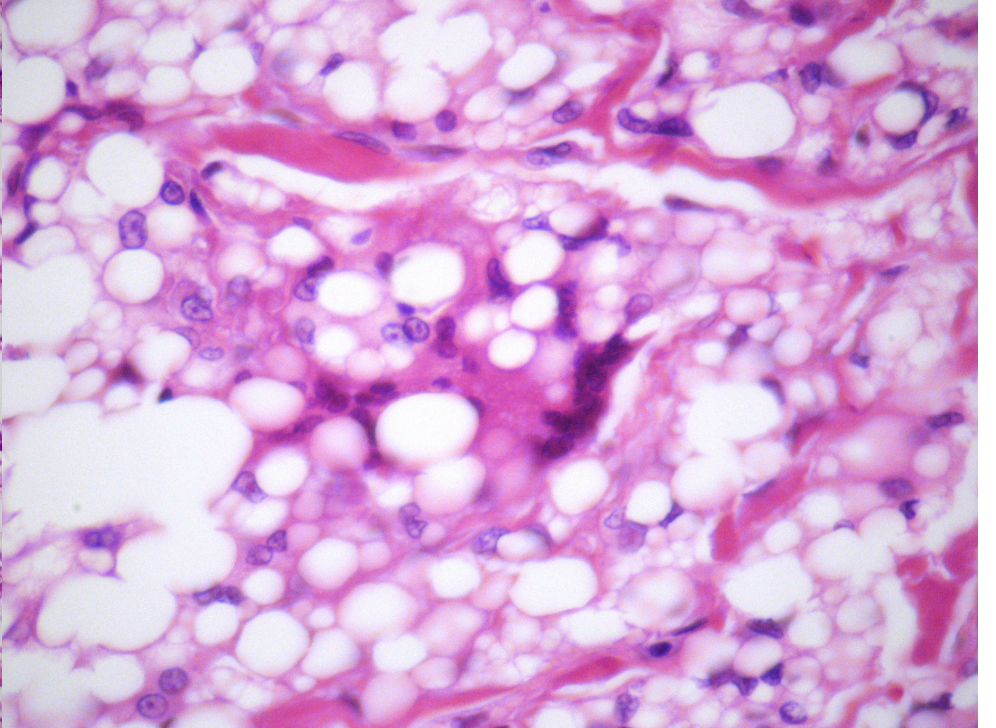
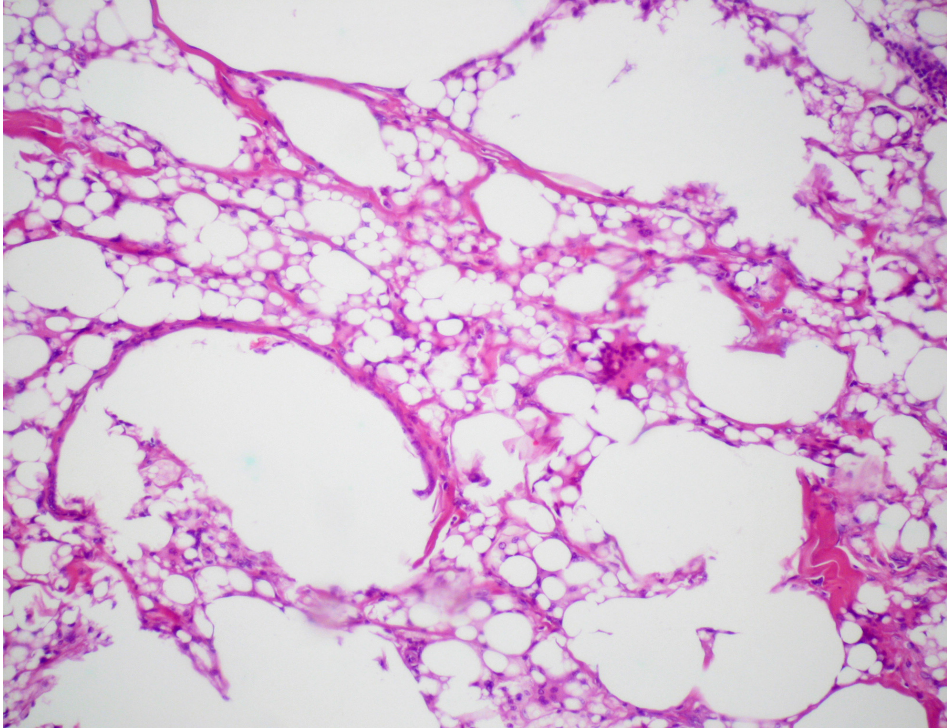
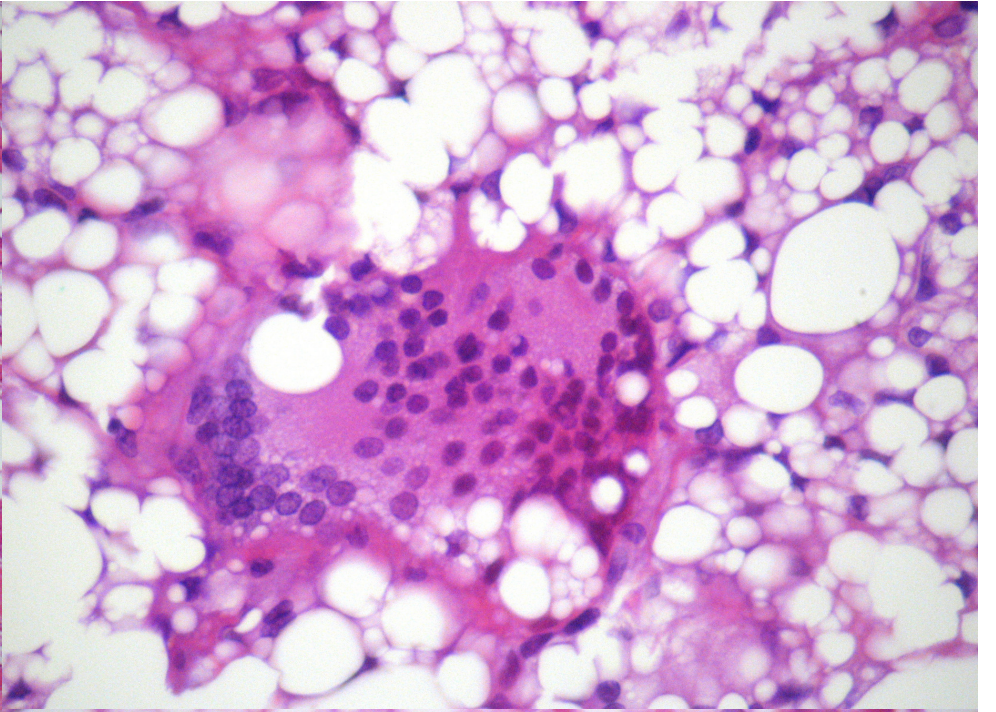
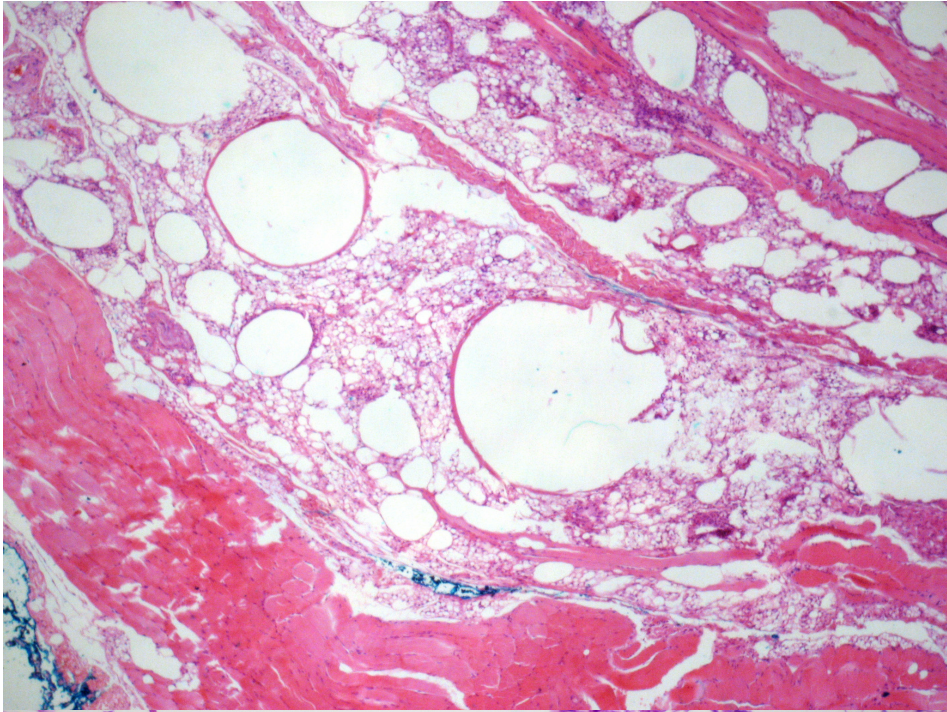


HISTÓRIA CLÍNICA

- Paciente sexo masculino, 51 anos
- Tumoração de partes moles em região glútea esquerda
- Multinodular, consistência firme-elástica









Escolha o melhor diagnóstico

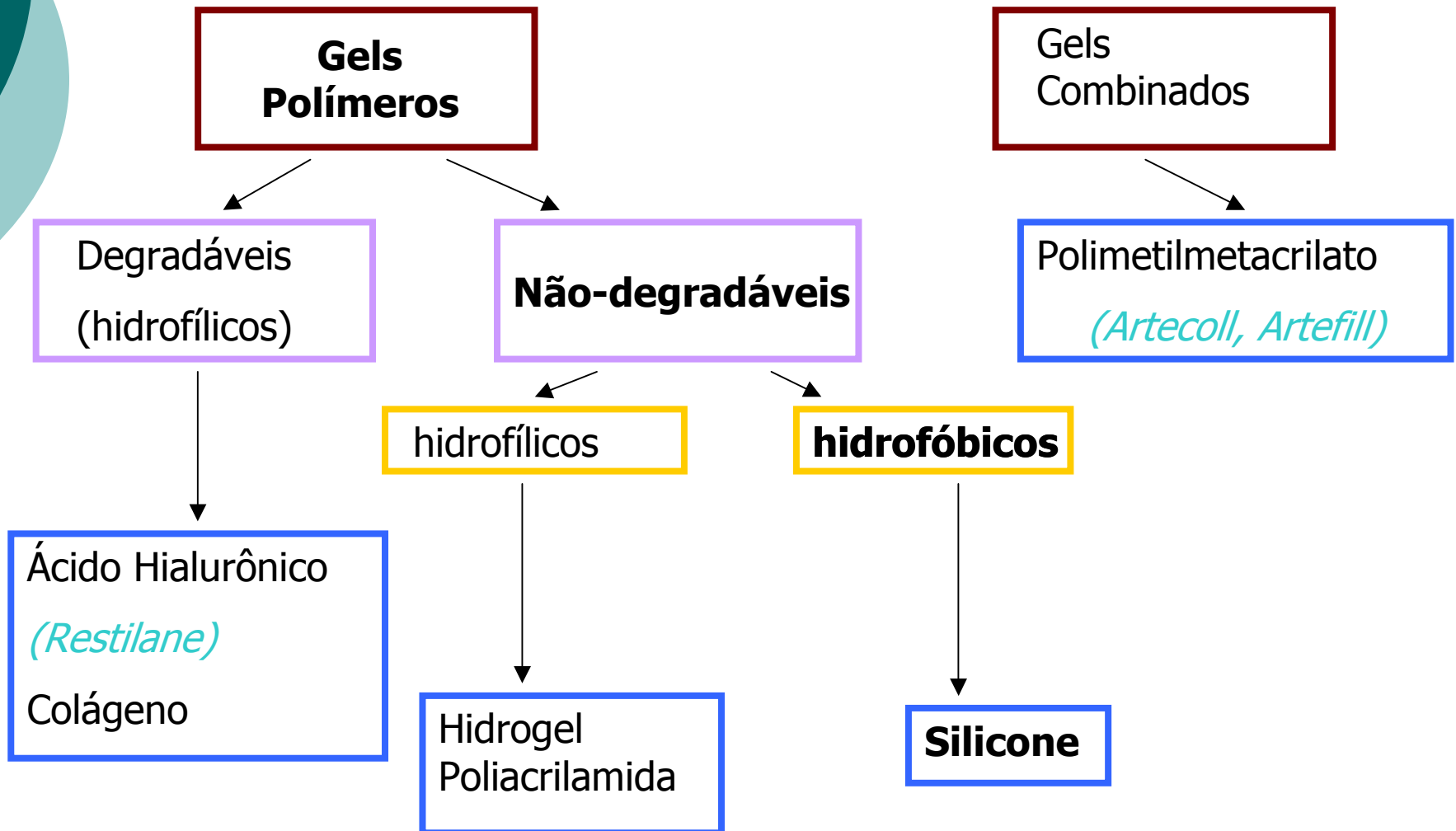
- Lipossarcoma
- Lipoblastoma
- Hibernoma
- Granuloma de silicone



Diagnóstico

Granuloma de Silicone

Implantes Estéticos





Granuloma de Silicone

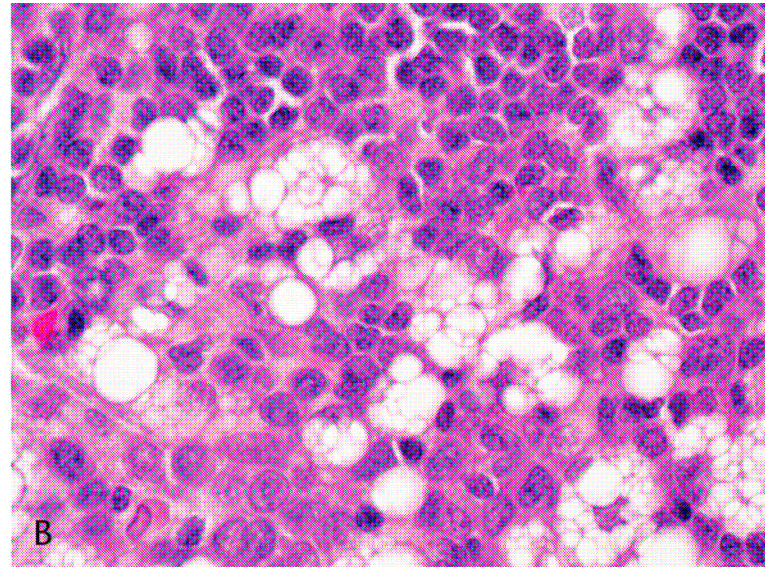
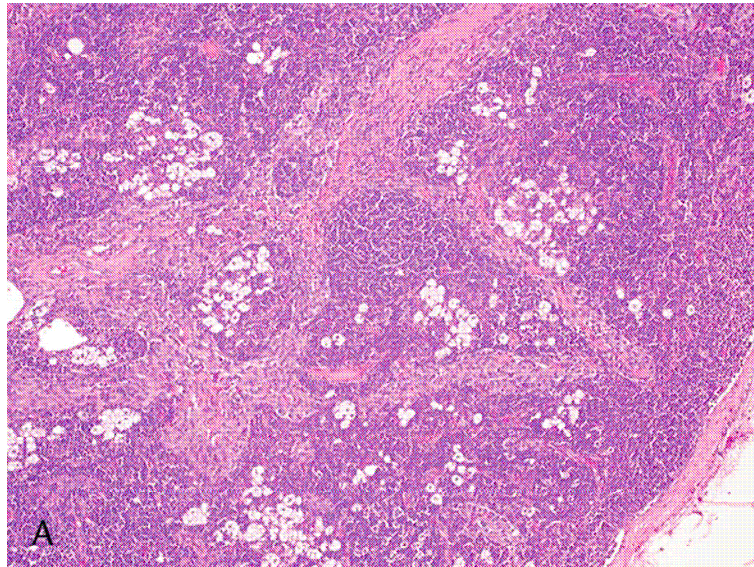
- Silicone

- Polímero não degradável, hidrofóbico
- Líquido ou sólido
- Tratamentos estéticos há mais de 40 anos
- Migração
 - Outros sítios ≠ injeção
 - SRE

Silicone

Incidental Findings in Negative Sentinel Lymph Nodes of Patients With Malignant Melanoma: Report of Three Cases

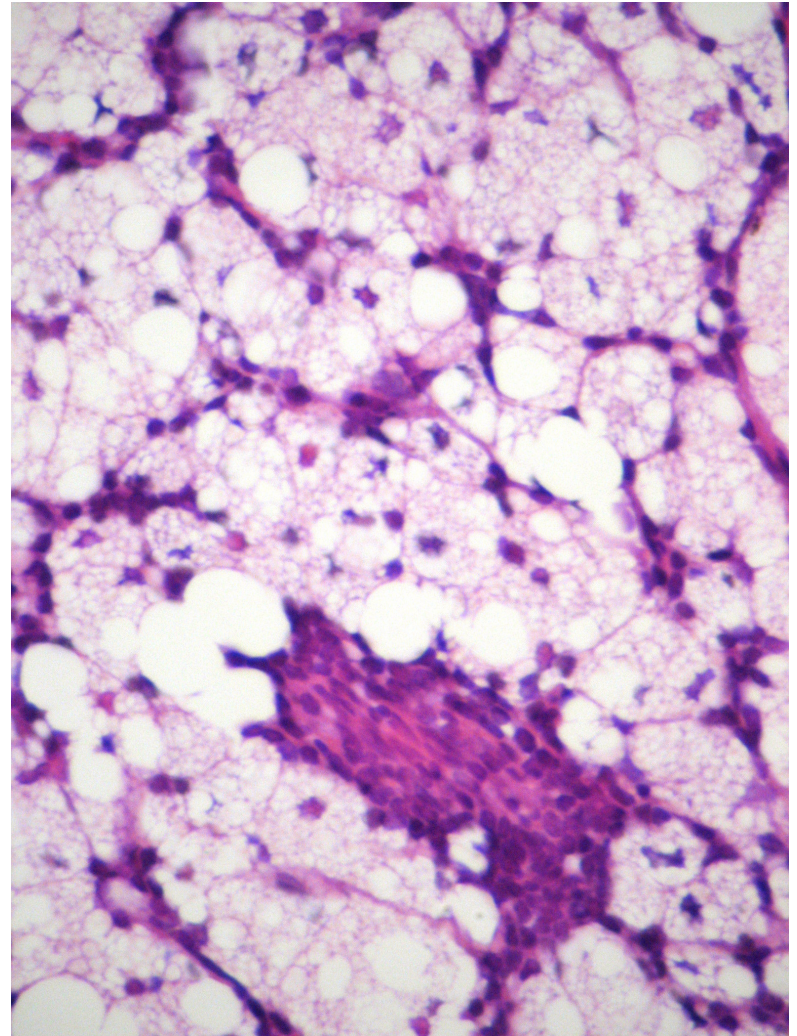
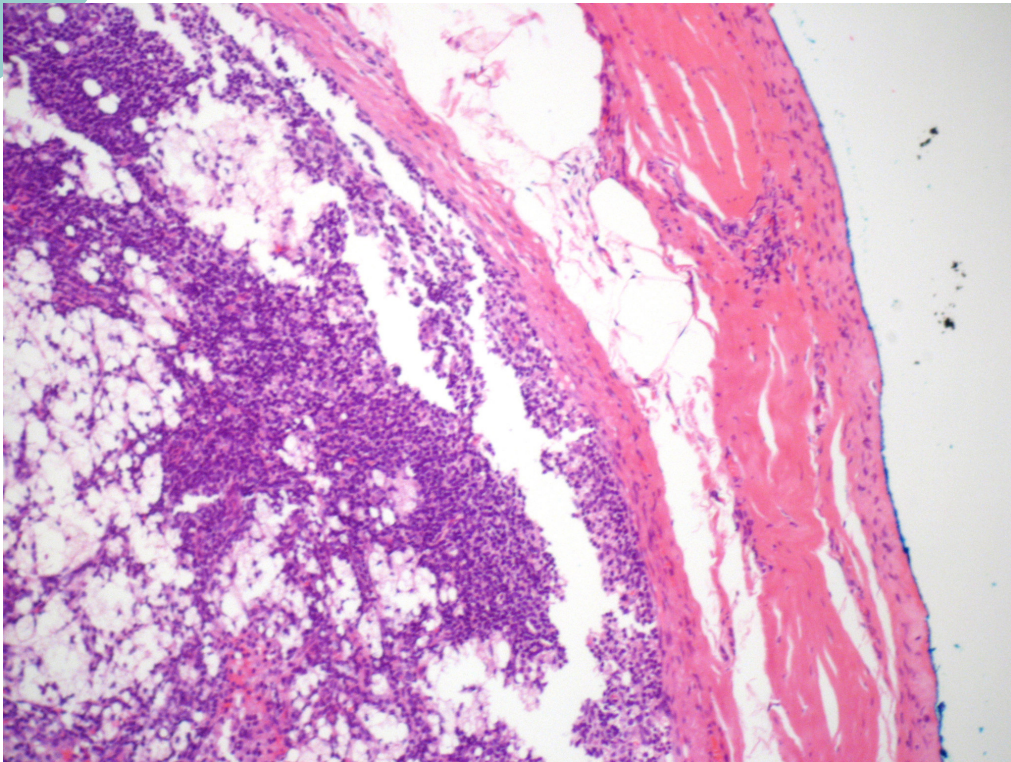
Ana Martinez-Peñuela, MD, Julio Del Olmo, MD,† José Francisco Boán, MD,‡ and Miguel Angel Idoate, MD**



(Am J Dermatopathol 2007;29:104–105)

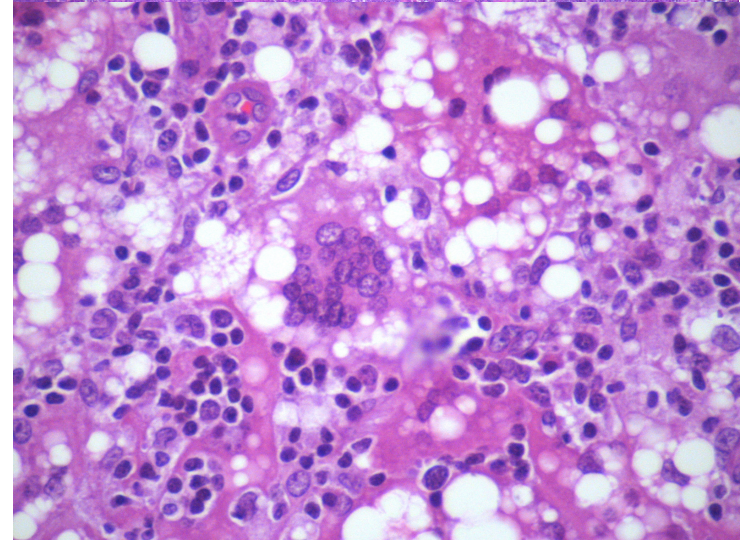
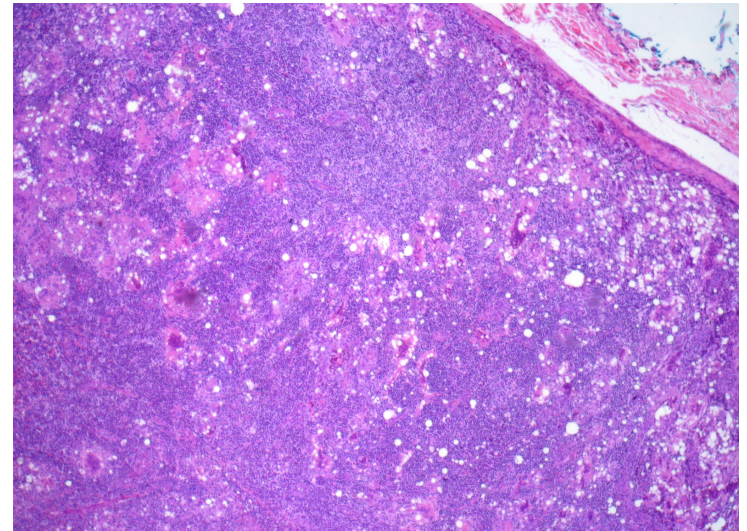
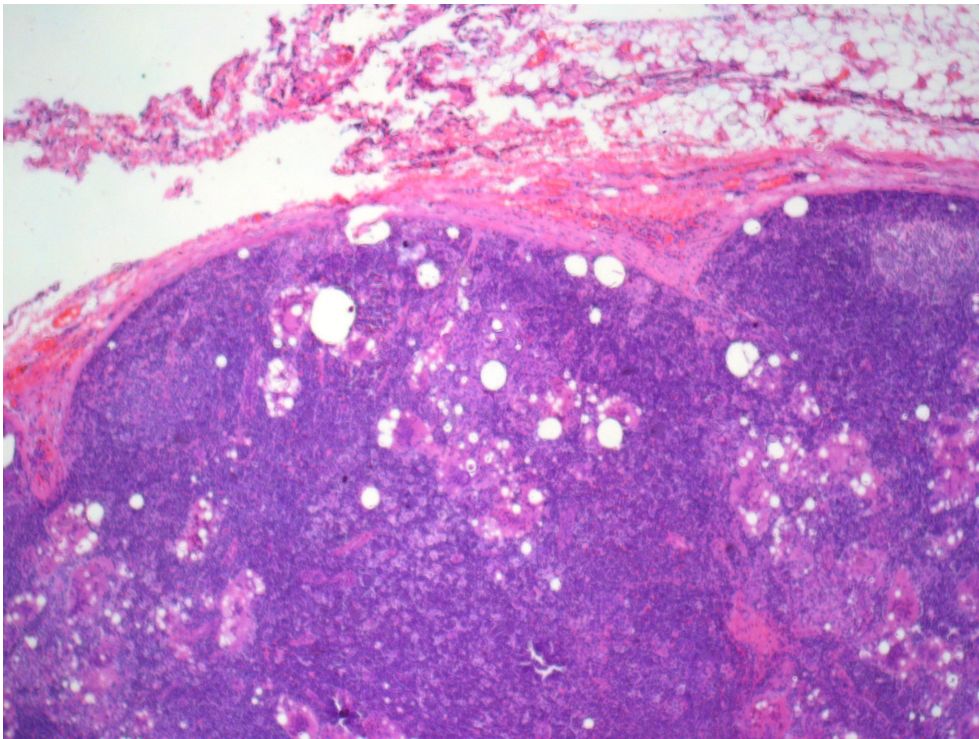
Silicone

- Sexo feminino, 33a, US nódulo em mama direita. Prótese de mama há 3 anos.



Silicone

- Sexo feminino, 32a, US nódulo em prolongamento axilar mama direita. Características Benignas.





Diagnósticos Diferenciais

- Lipossarcoma
- Lipoblastoma
- Hibernoma
- Outros implantes estéticos



Lipossarcoma

CASE REPORT

Tissue reaction to liquid silicone simulating low-grade liposarcoma following lip augmentation

Alexander Maly¹, Eran Regev², Karen Meir¹, Bella Maly¹

Departments of ¹Pathology, and ²Oral and Facial Surgery, Hadassah University Hospital, Jerusalem, Israel

J Oral Pathol Med (2006) 33:314-6

A diagnostic trap for the dermatopathologist: granulomatous reactions from cutaneous microimplants for cosmetic purposes

Vincenzo Mustacchio¹,
D. Cabibi², M. I. Minervini³,
E. Barresi² and S. Amato¹

J Cutan Pathol 2007: 34: 281–283

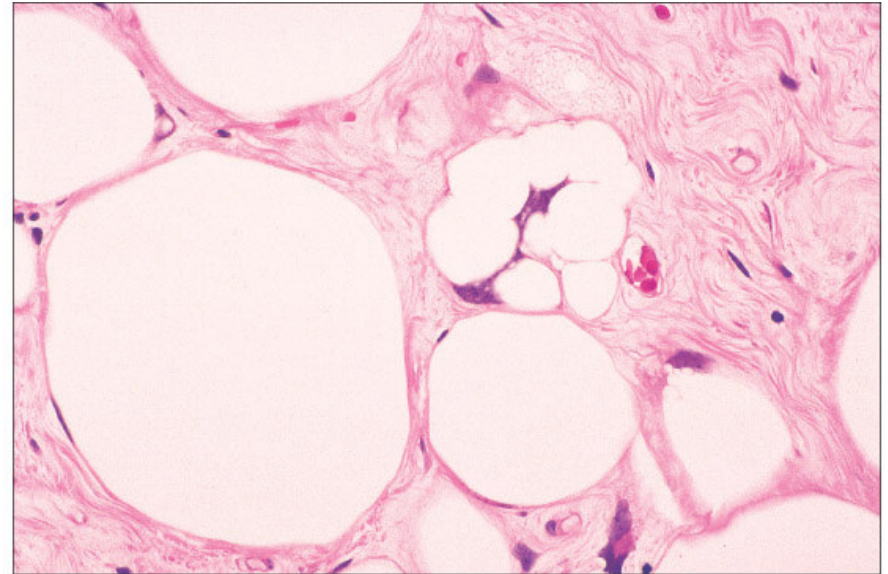
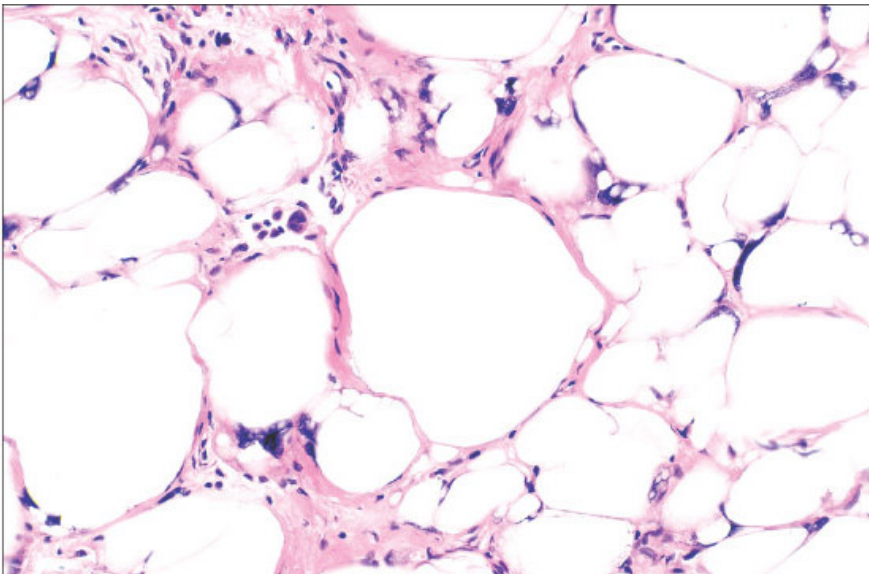
Lipossarcoma

TABLE 16-2 LESIONS SIMULATING ALN/WDL

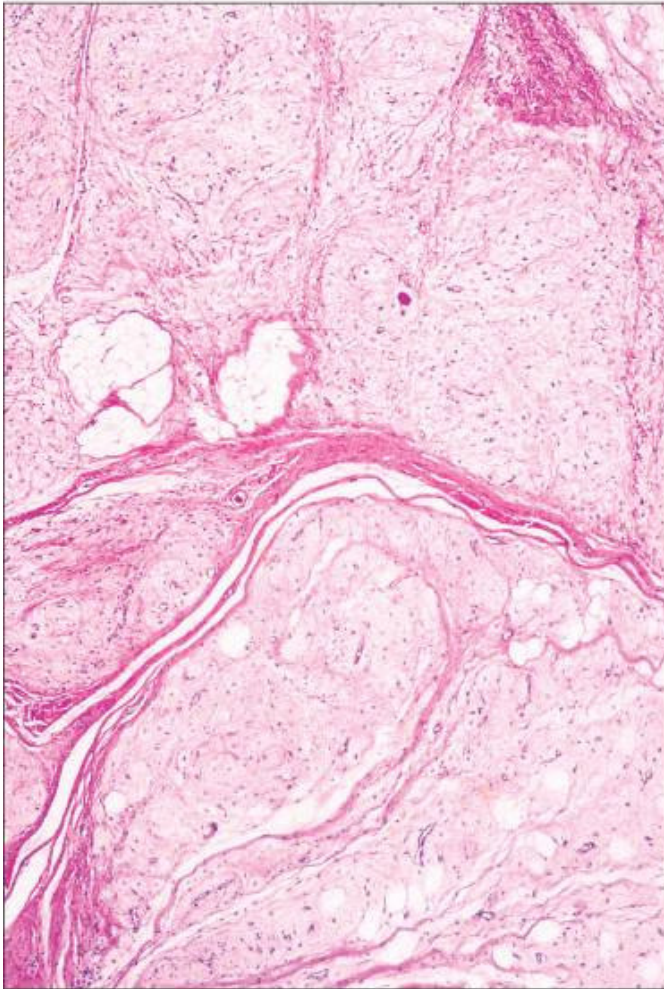
Lipoma with fat necrosis
Lipoma with <i>lochker</i>
Fatty atrophy
Silicone reaction
Diffuse lipomatosis
Spindle cell lipoma / pleomorphic lipoma
Myolipoma
Cellular angiolipoma
Angiomyolipoma
Lipomatous hemangiopericytoma

- Lipossarcoma bem diferenciado/ Tumor Lipomatoso Atípico
- Pico- 6ª década
- Partes moles profundas membros, ppte COXA

© Elsevier, Inc. 2008 Weiss and Goldblum. *Enzinger and Weiss's Soft Tissue Tumors*, 5th edition.

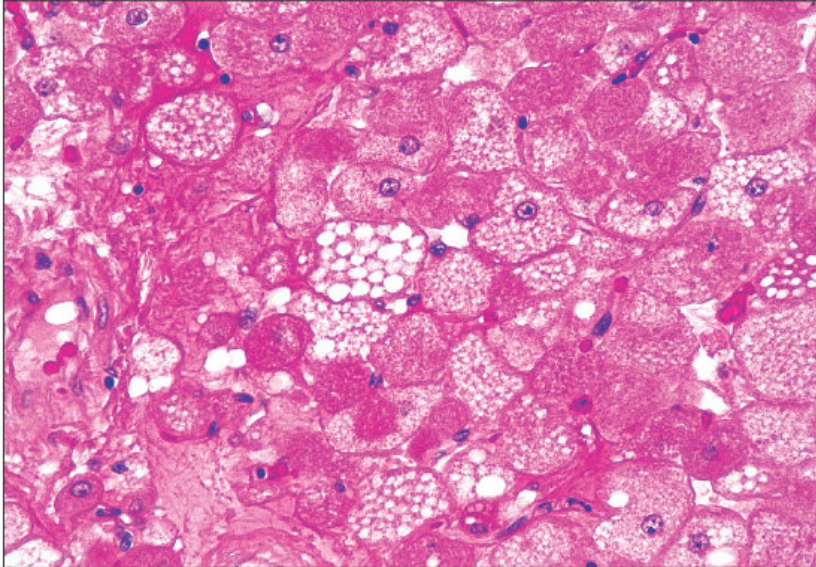


Lipoblastoma

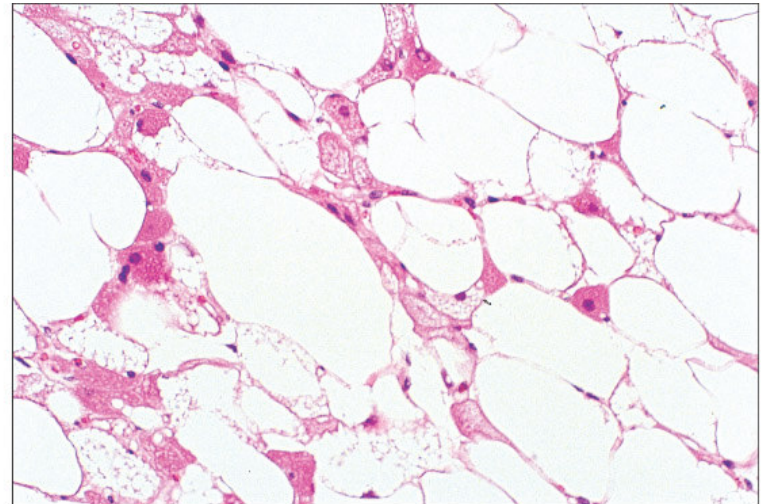


- Benigno
- Lobulado
- Localizado ou Difuso (Lipoblastomatose)
- Extremidades
- 0-3 anos

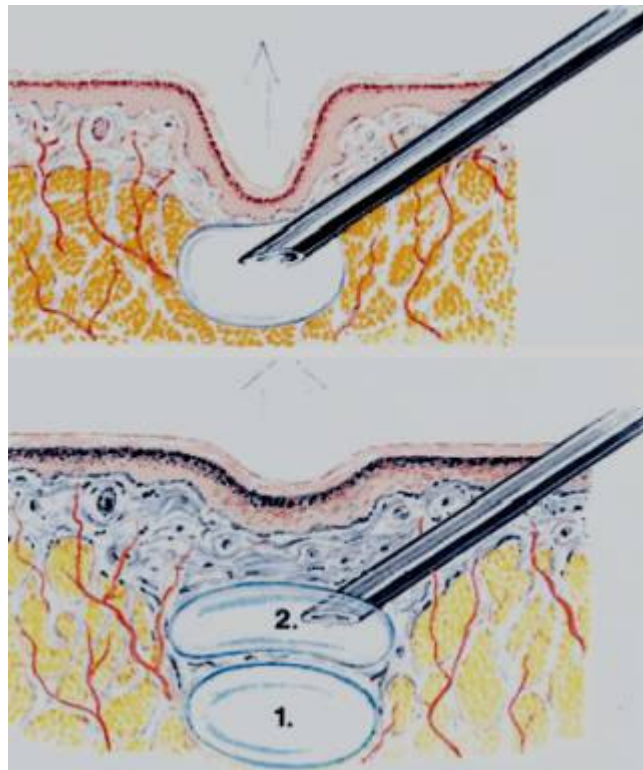
Hibernoma



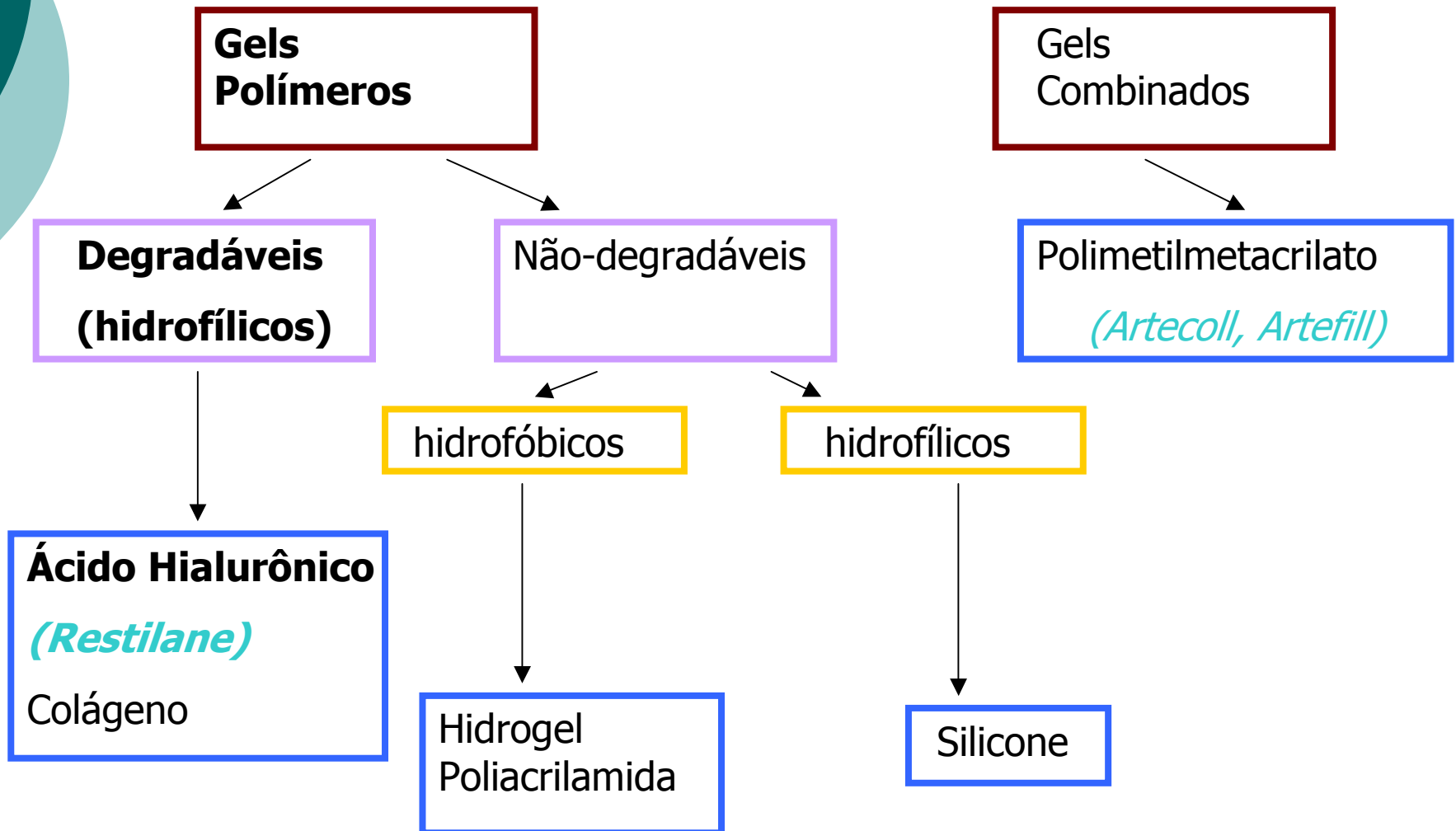
- Benigno
- Adultos jovens (méd. 38 anos)
- Coxa, tronco, MMSS, Cabeça/Pescoço



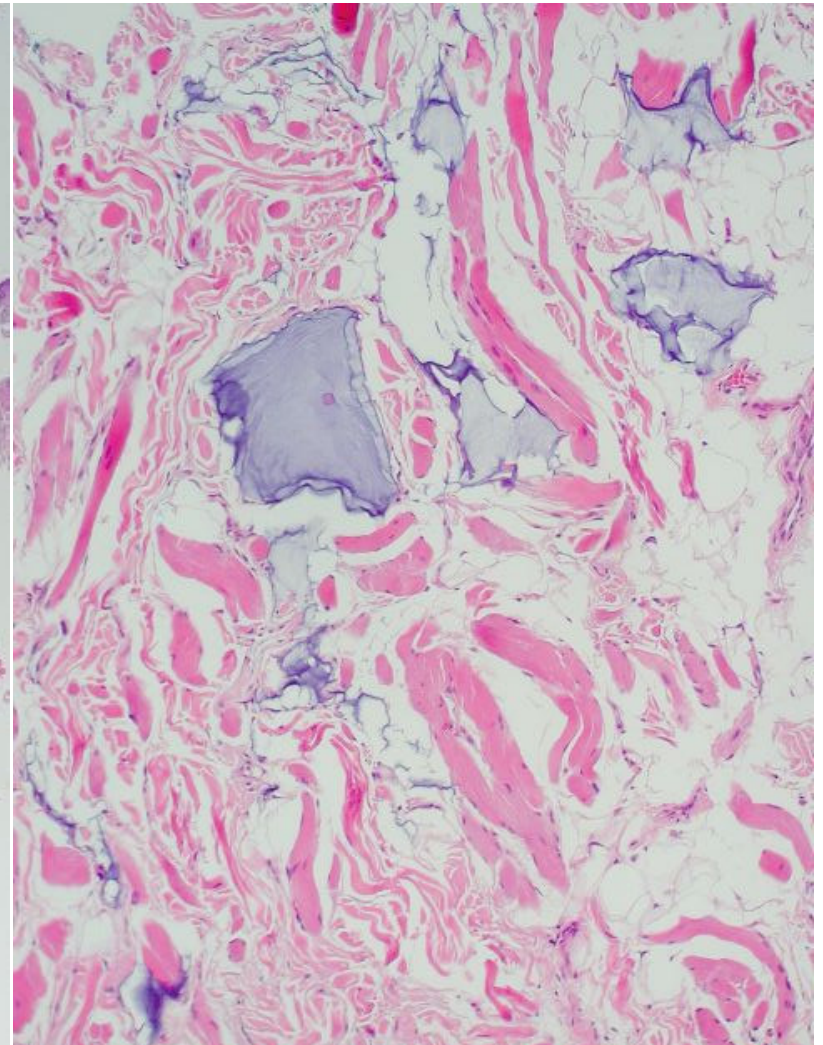
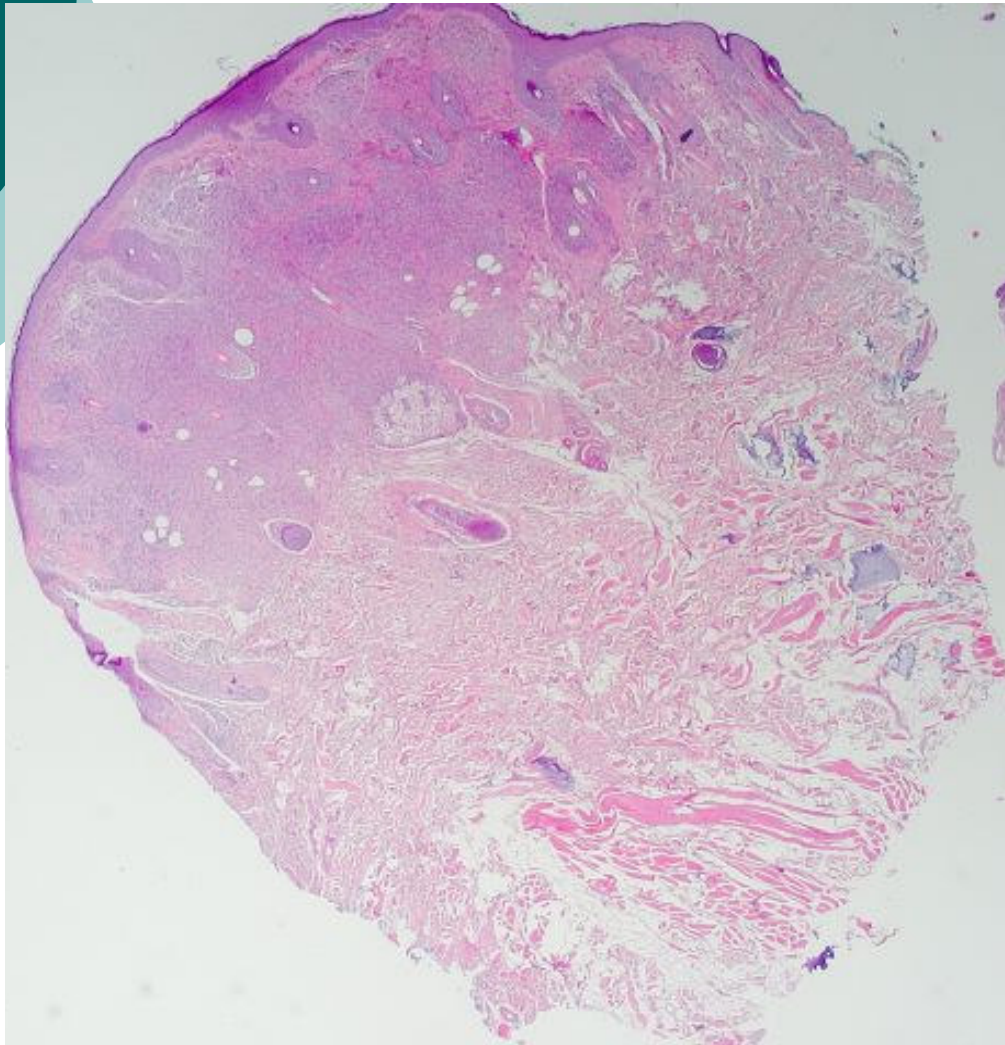
Outros implantes estéticos



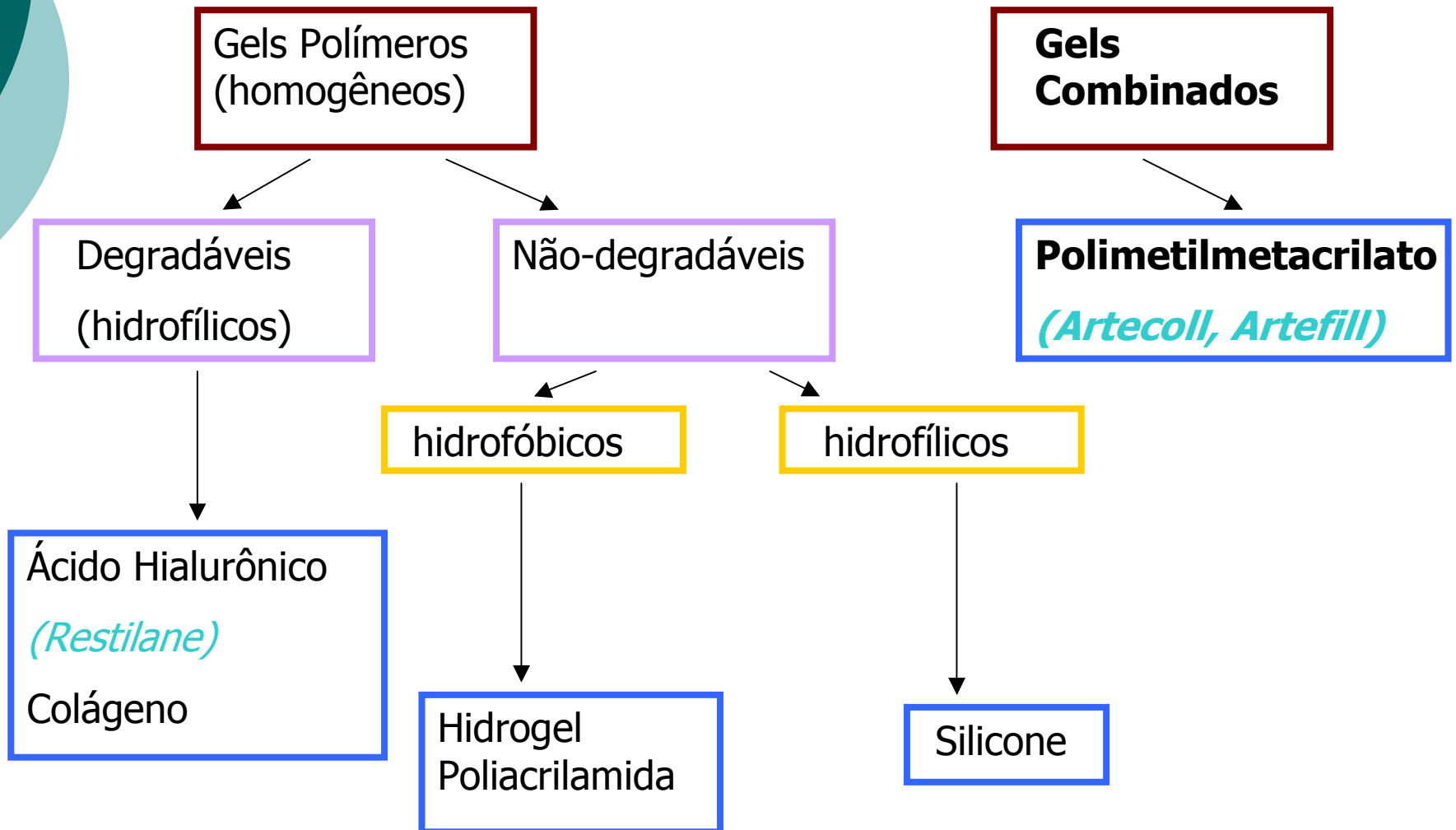
Ácido Hialurônico



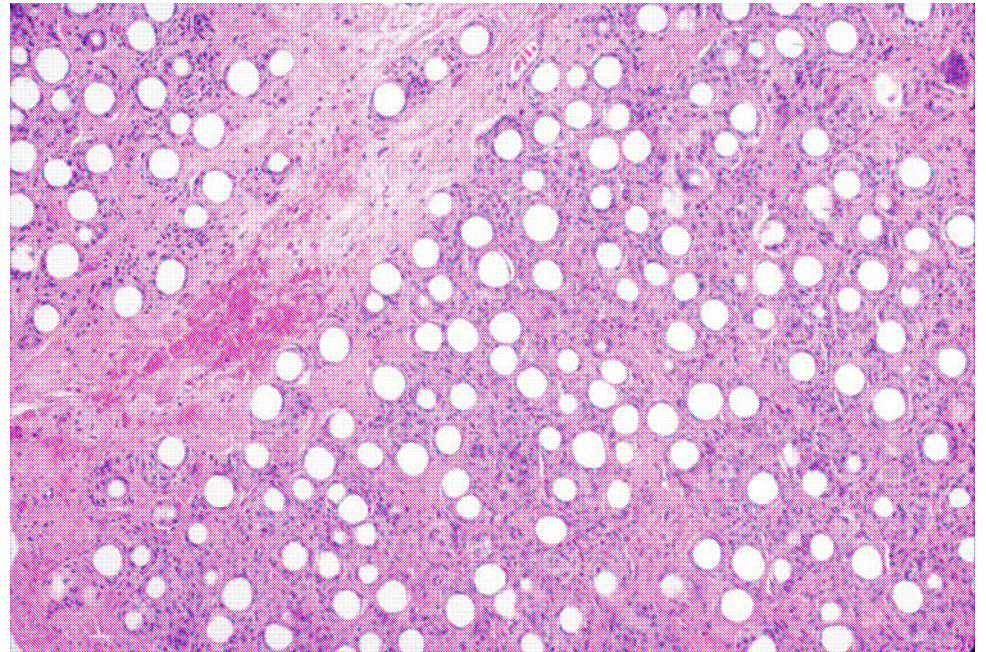
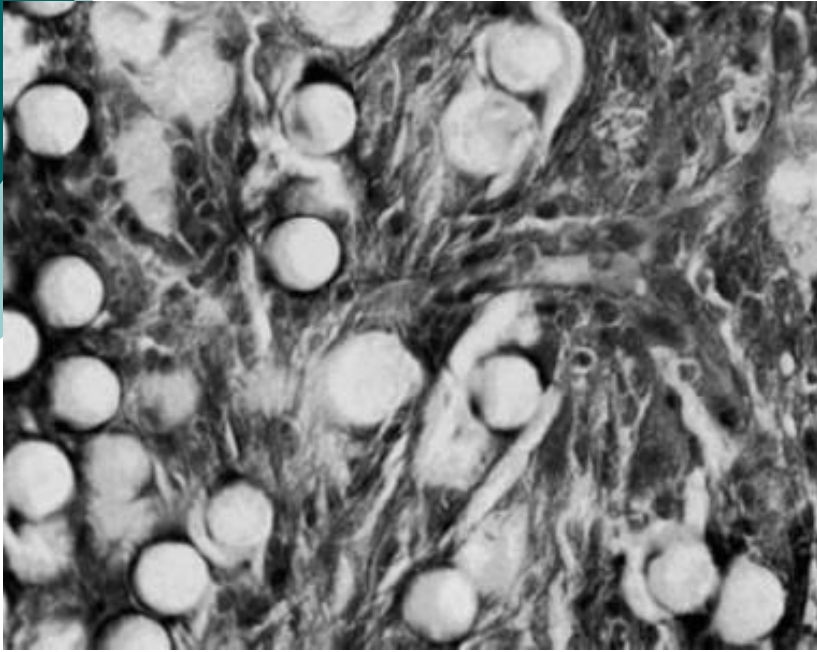
Ácido Hialurônico



Artecol - PMMA



Polimetilmetacrilato





BIBLIOGRAFIA

1. Rudolph, CM; Soyer, HP; Schuller-Petrovic, S; Kert, H. Foreign body granulomas due to injectable aesthetic microimplants. **Am J Surg Pathol 1999: 23(1):113-7.**
2. Mustachio, V; Cabibi, D; Minervini, MI; et al. A diagnostic trap for the dermatopathologist: granulomatous reactions from cutaneous microimplants for comestic purposes. **J Cutan Pathol 2007: 34: 281-3.**
3. Maly, A; Regev, E; Meir, K; Maly, B. Tissue reaction to liquid silicone simulating low-grade liposarcoma following lip augmentation. **J Oral Pathol Med 2004: 33: 314-6.**
4. Rongioletti, F. Granulomatous reactions from aesthetic dermal microimplants. **Ann Dermatol Venerol 2008: 135: 559-565.**
5. Christensen L. Normal and pathologic tissue reactions in soft tissue gel fillers. **Dermatol Surg 2007: 33: S168-S175.**
6. Martinez-Peñuela, A; Olmo, J; Boán JF; Idoate, MA. Incidental findings in negative sentinel lymph nodes of patients with malignant melanoma: report od three cases. **Am J Dermatopathol 2007: 29(1): 104-5.**
7. Weiss, SW; Goldblum, JR. Enzinger & Weiss's Soft Tissue Tumors. 5ª edição.