

# CASO DO MÊS

Sociedade Brasileira de  
Patologia

Rodrigo Vismari de Oliveira

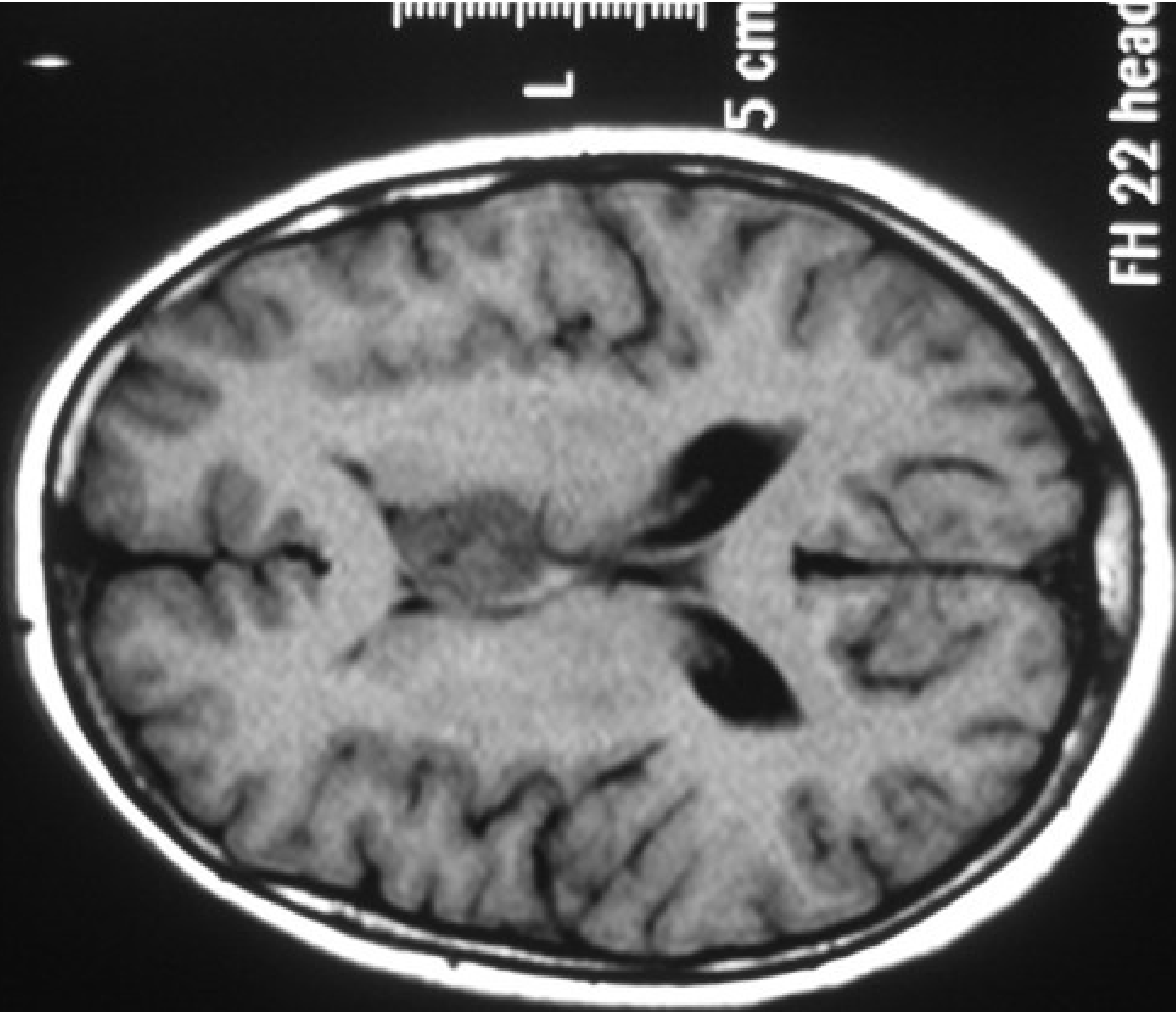
# História Clínica

- Sexo feminino, 51 anos.
- Clínica de cefaléia e turvação visual progressiva há 1 ano.
- Imagem: tumor cerebral no interior do terceiro ventrículo

FH-1 feet

11  
M  
1

A



L

5 cm

FH 22 head

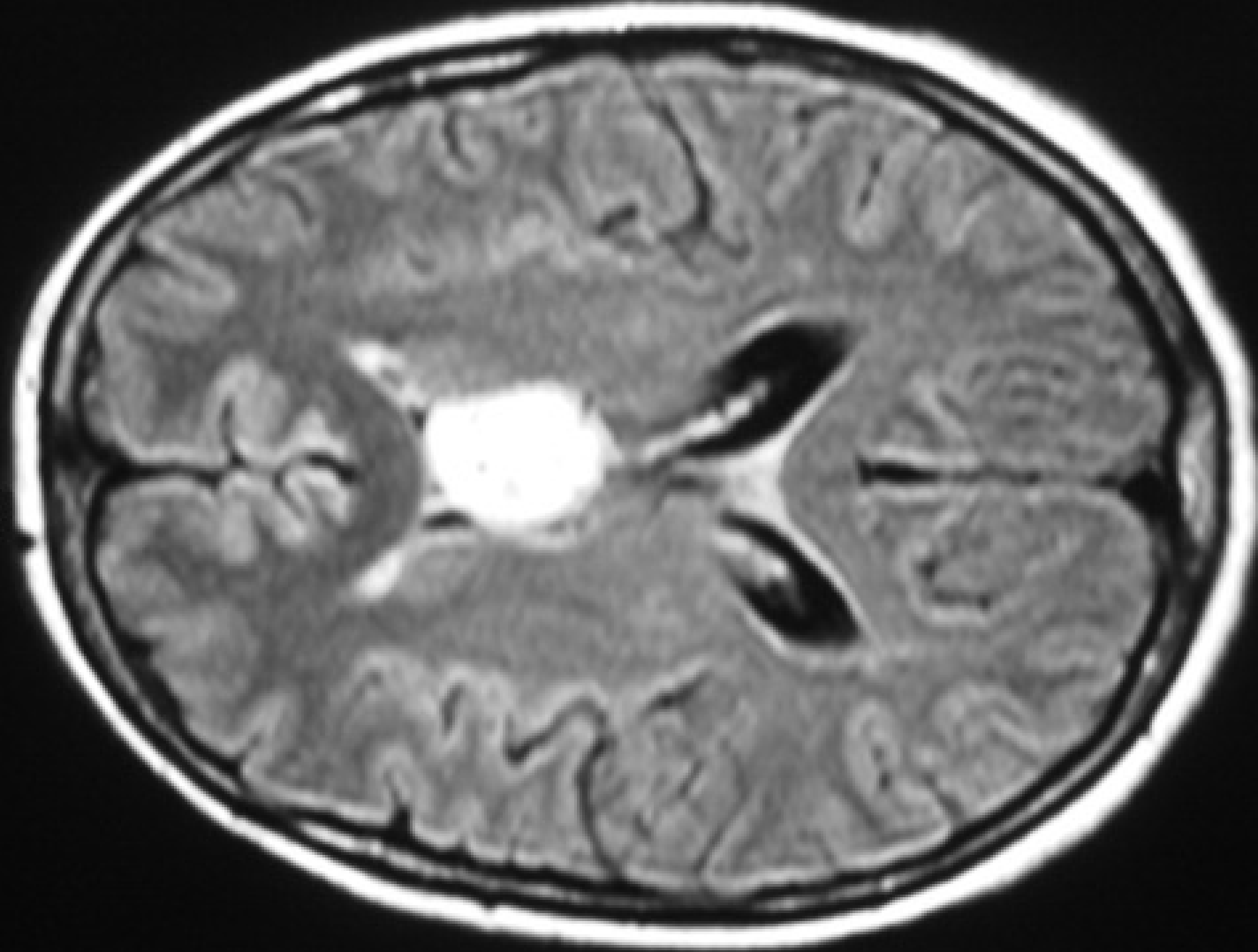
A

11  
M  
1

FH -1 f

SYM  
1

A



L

50

FH 22 he

8

DA V. MARTINS

H E VILA ALPI

ALO F

27-SEP-

1958

11:

B

SCAN

TSE

2:26

M

4860

120

0/1.4

/ 1.0

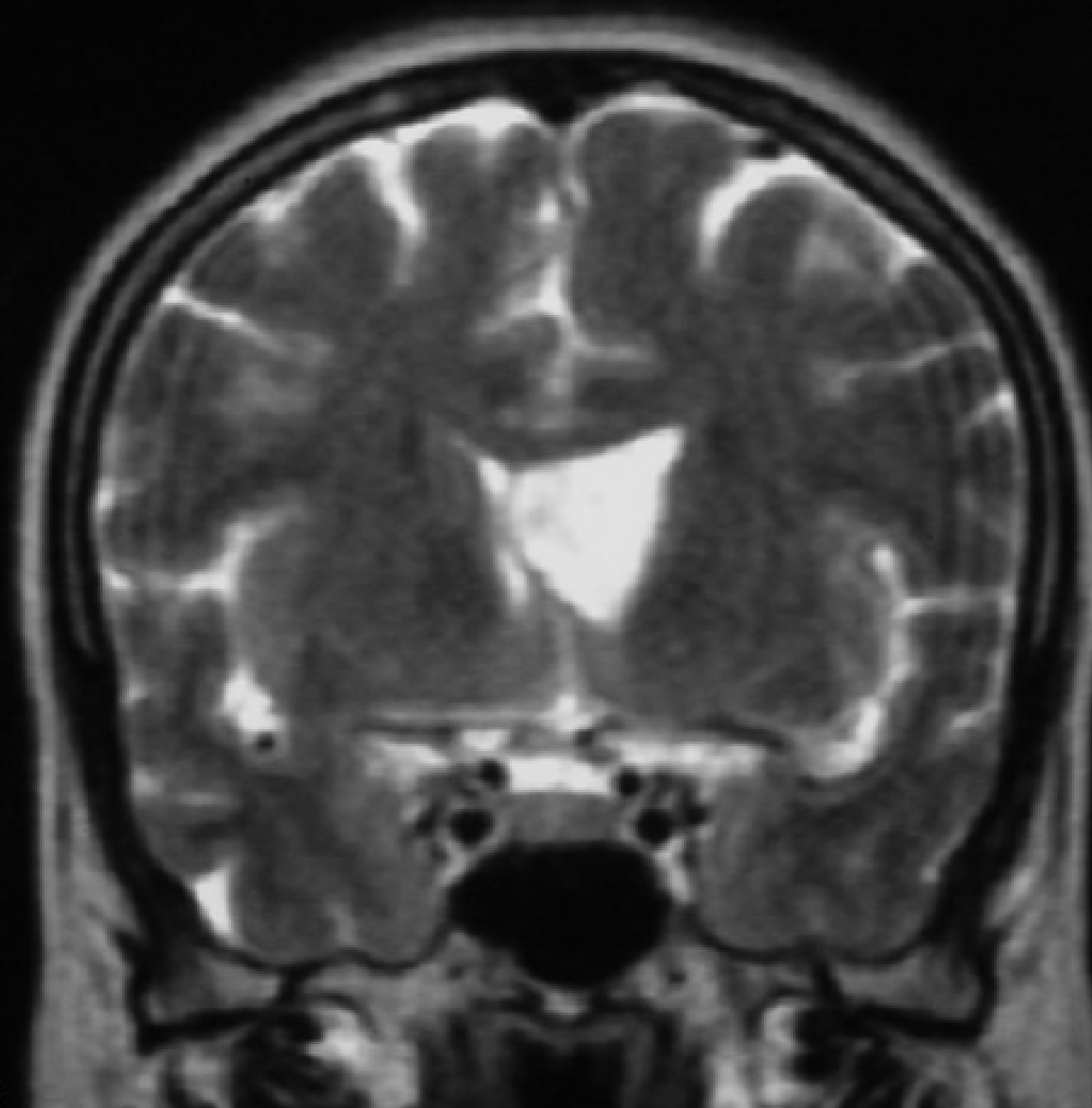
7/ 18

14.3

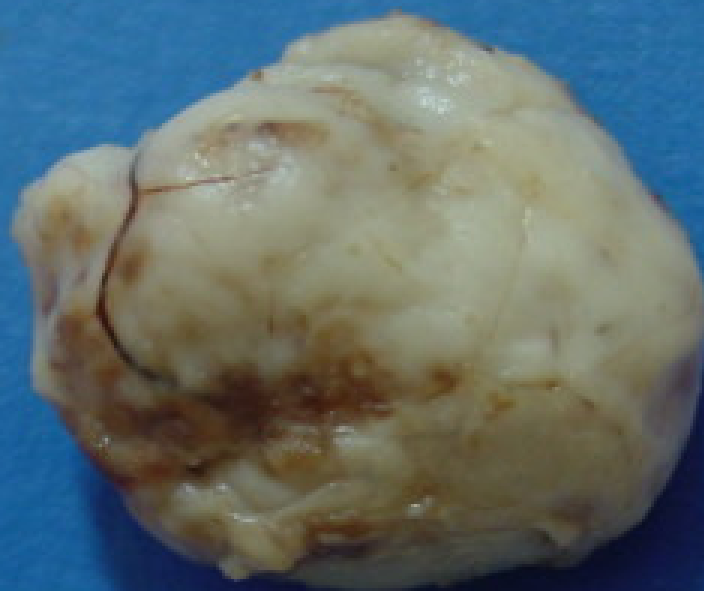0.9

54.7

R



L W 15



B

09057/08

3

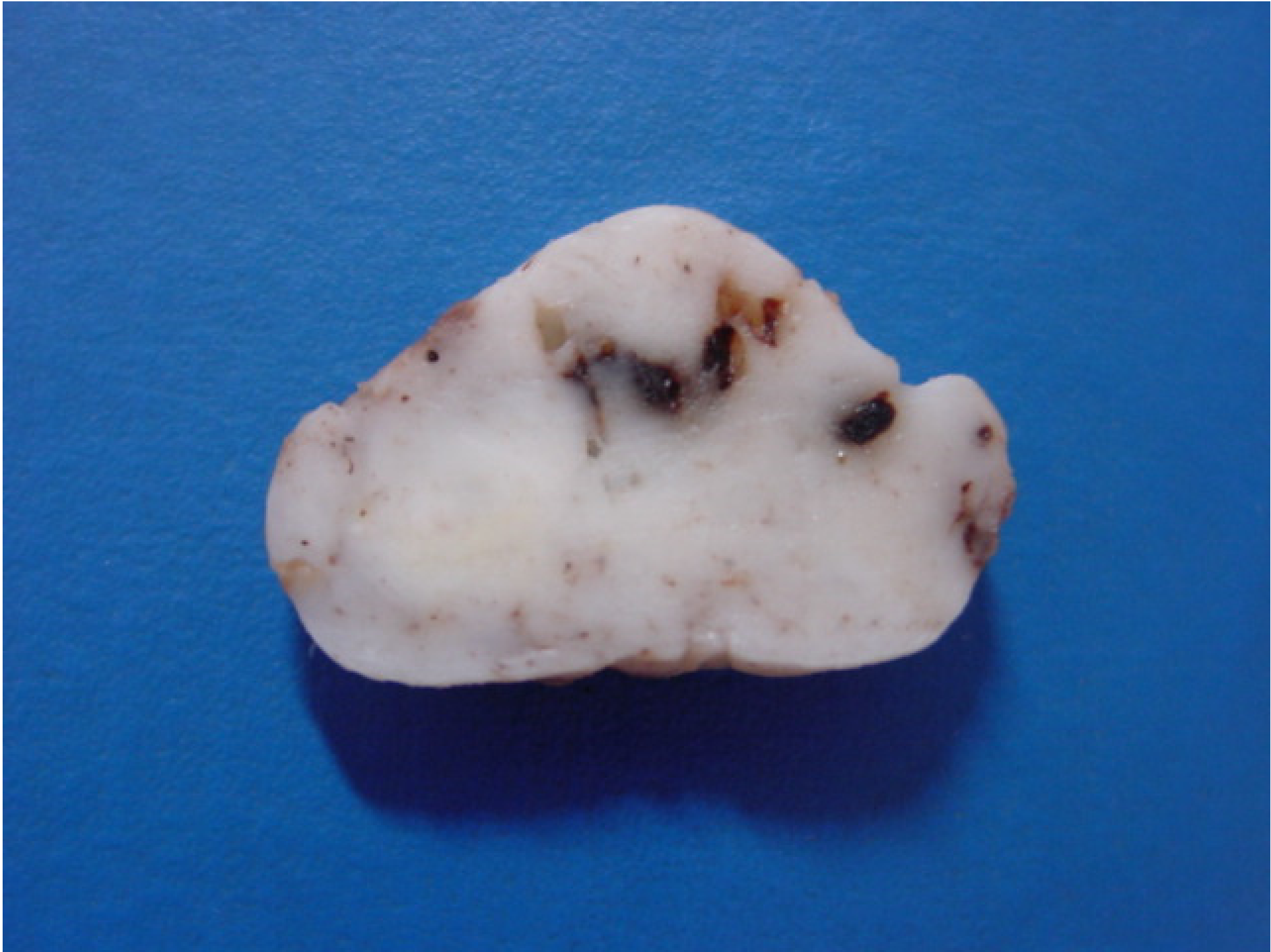4

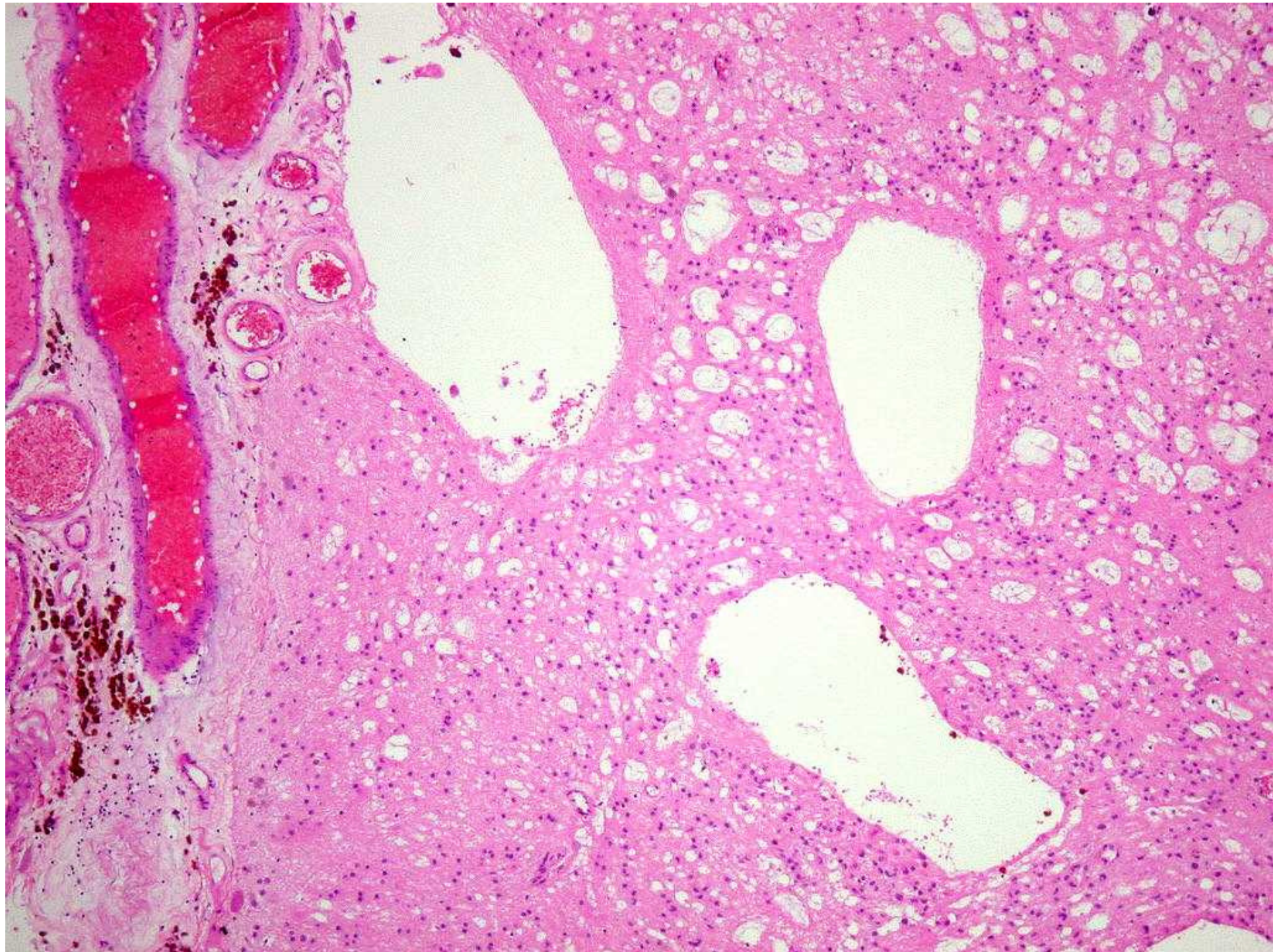
5

8

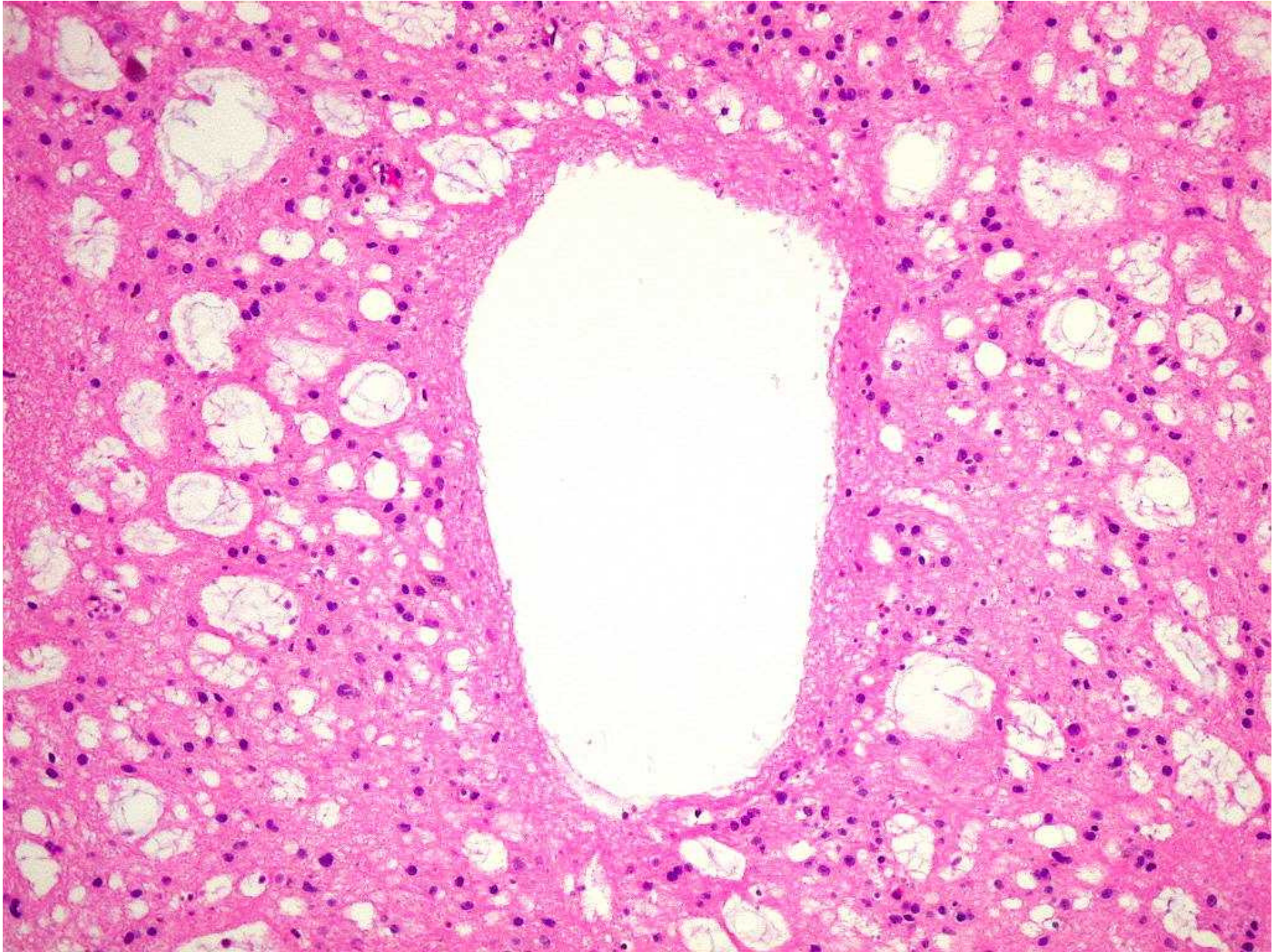
9

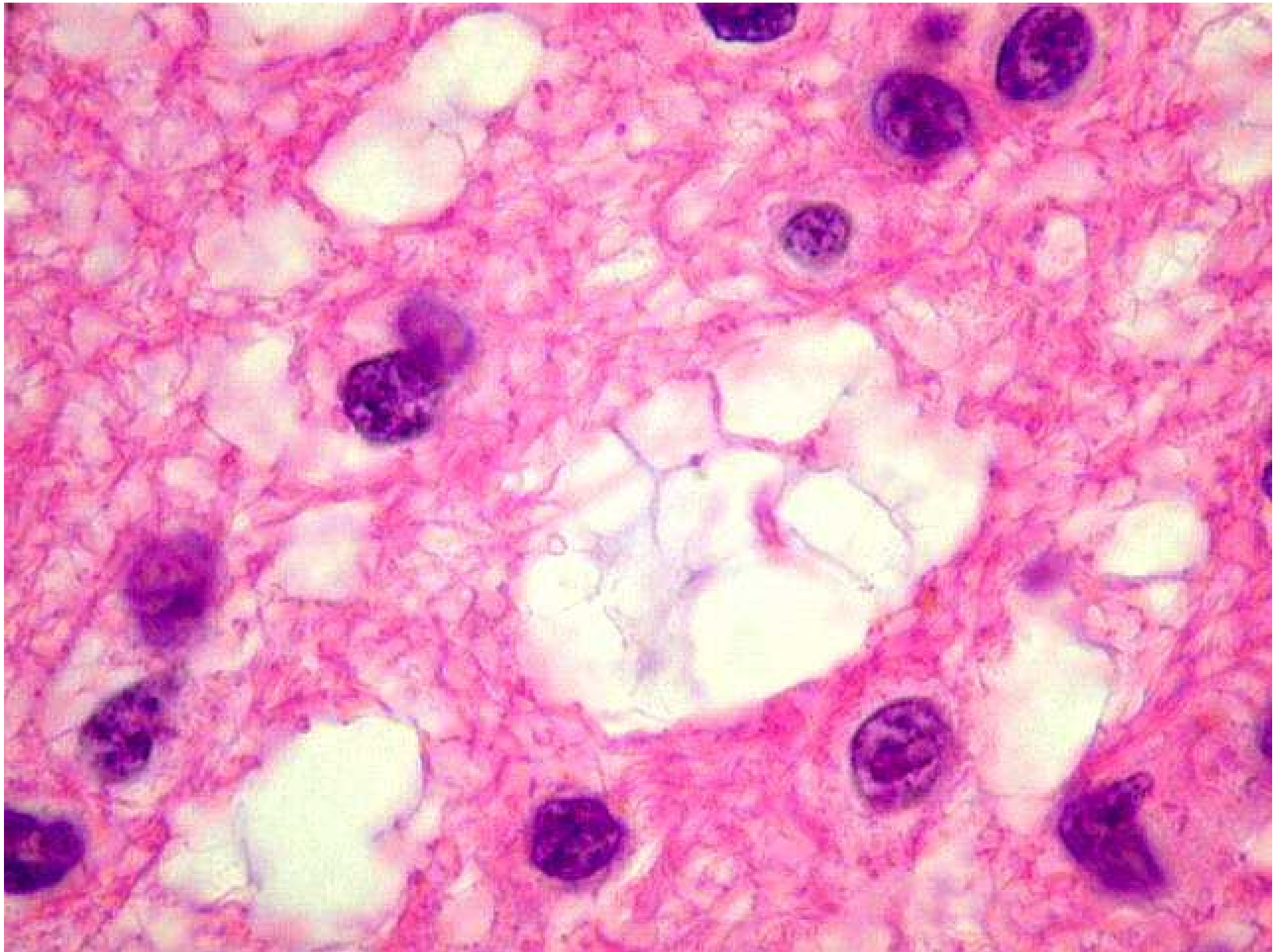
10

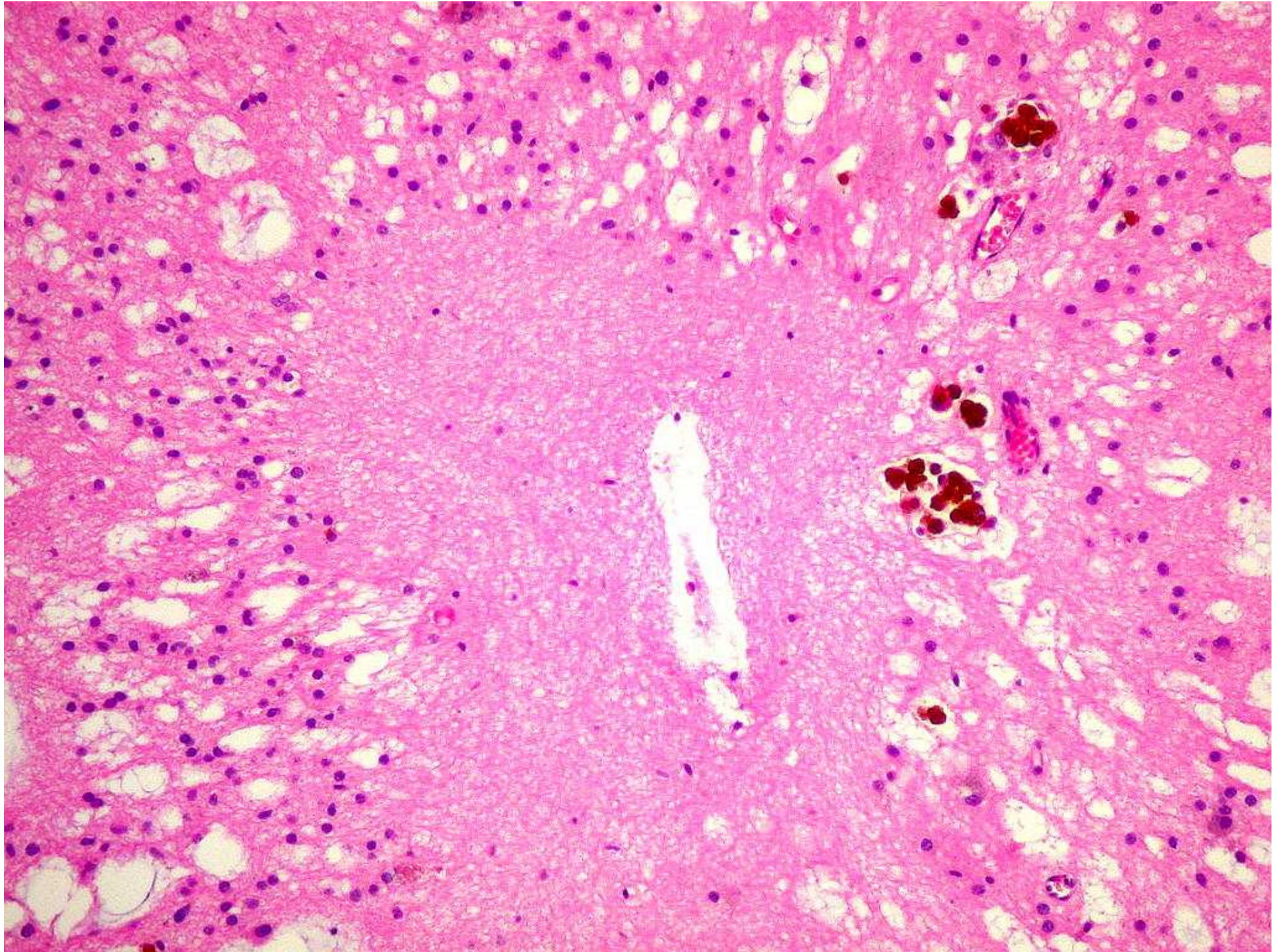


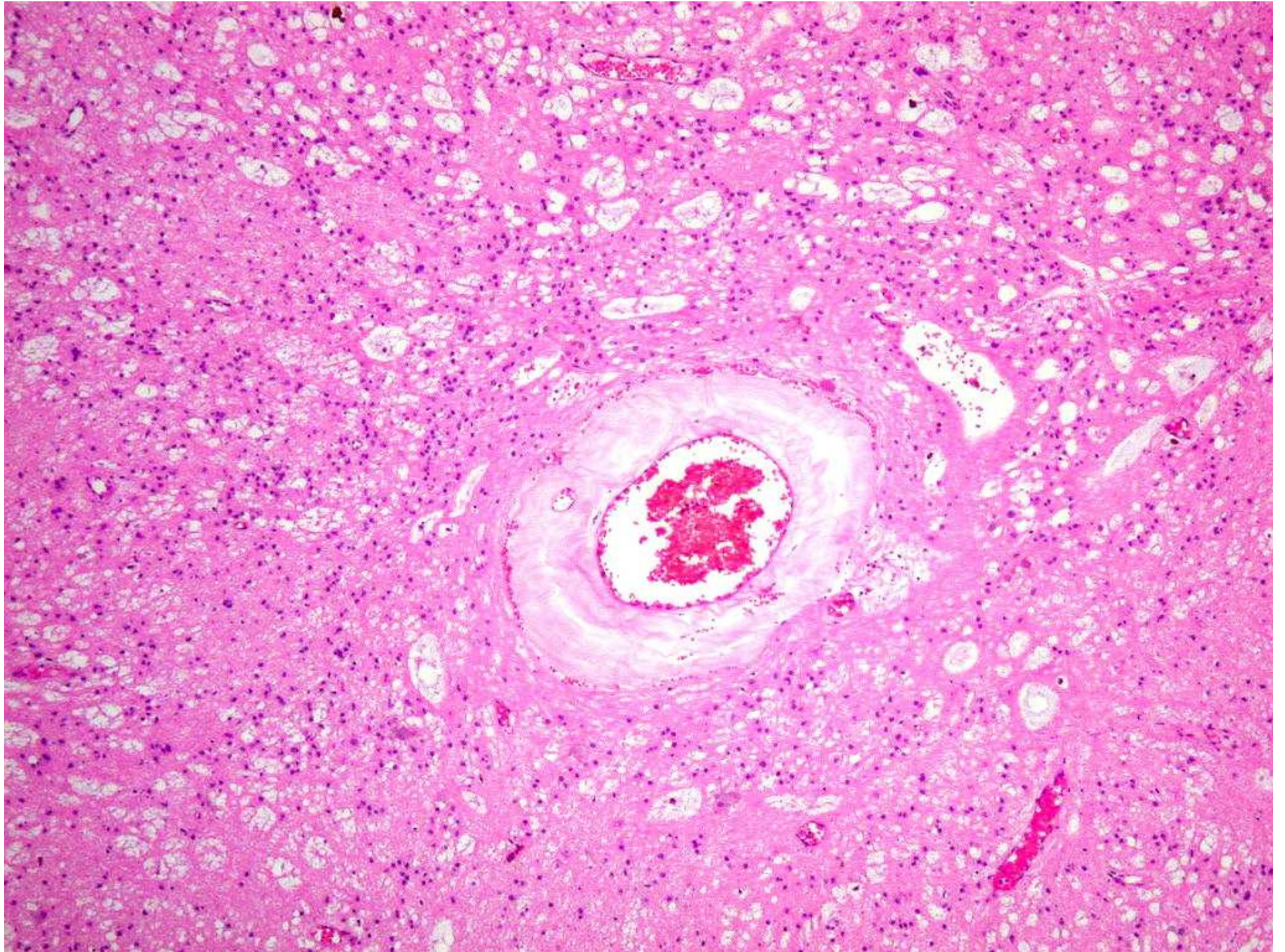


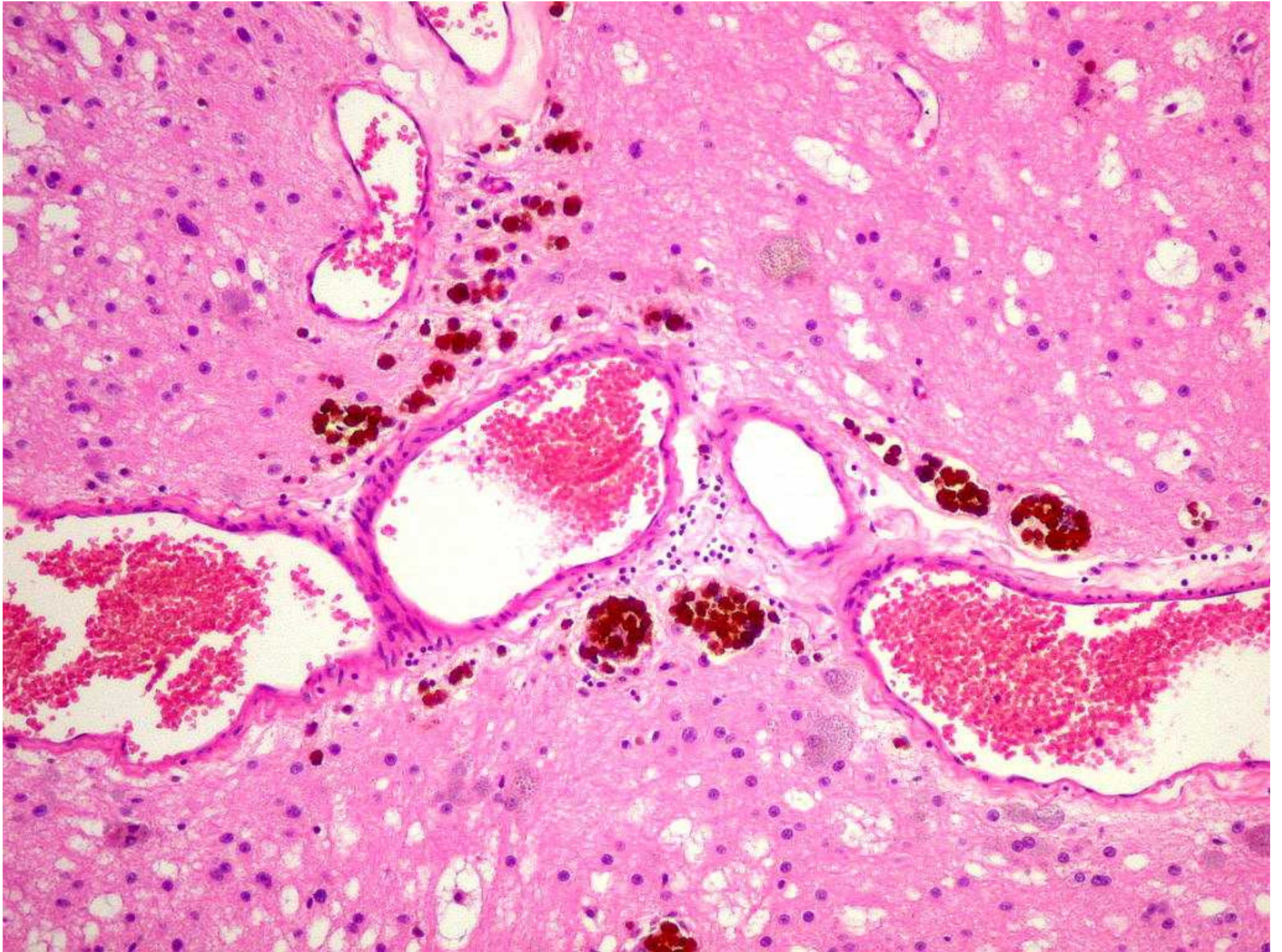


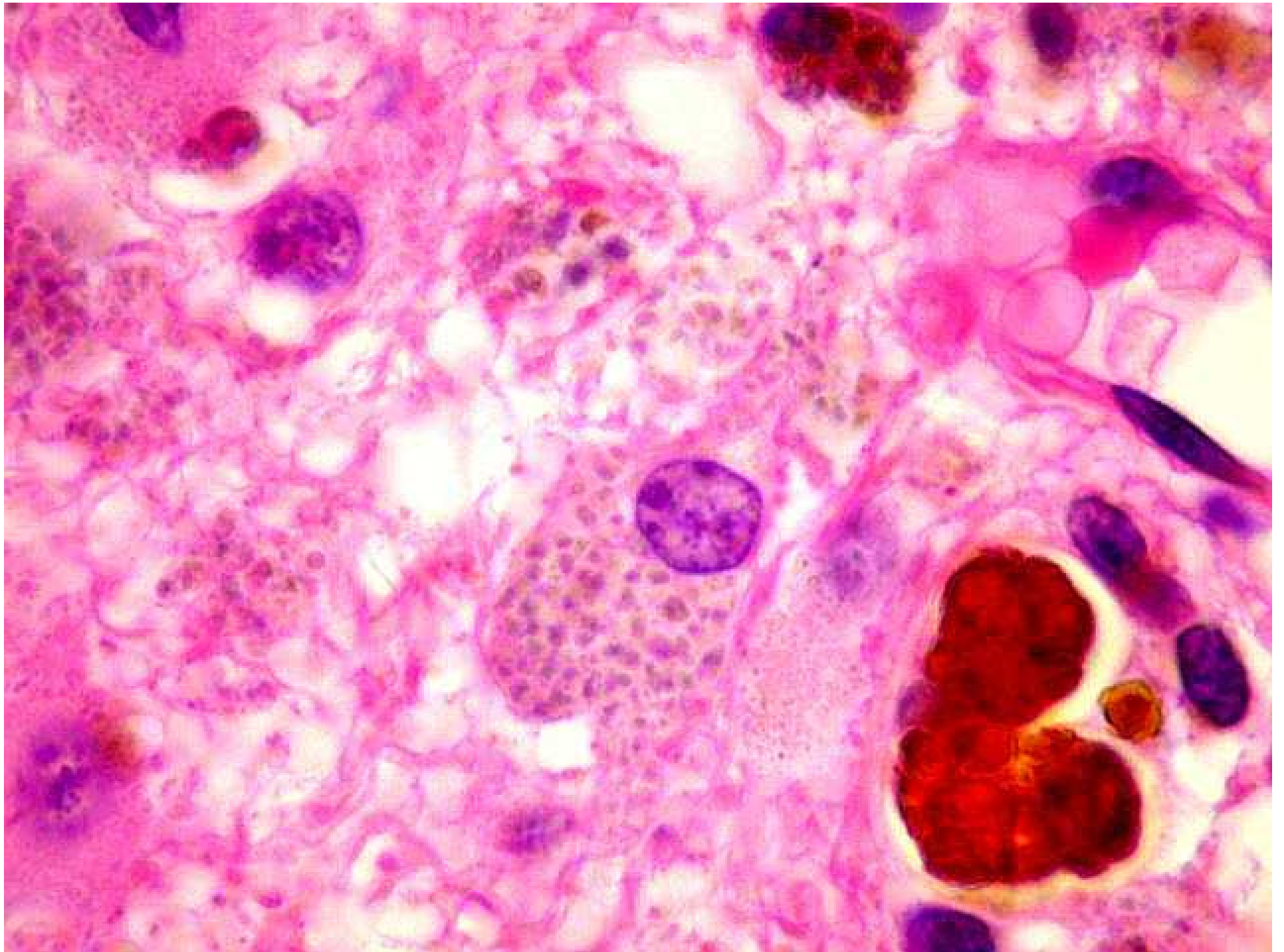


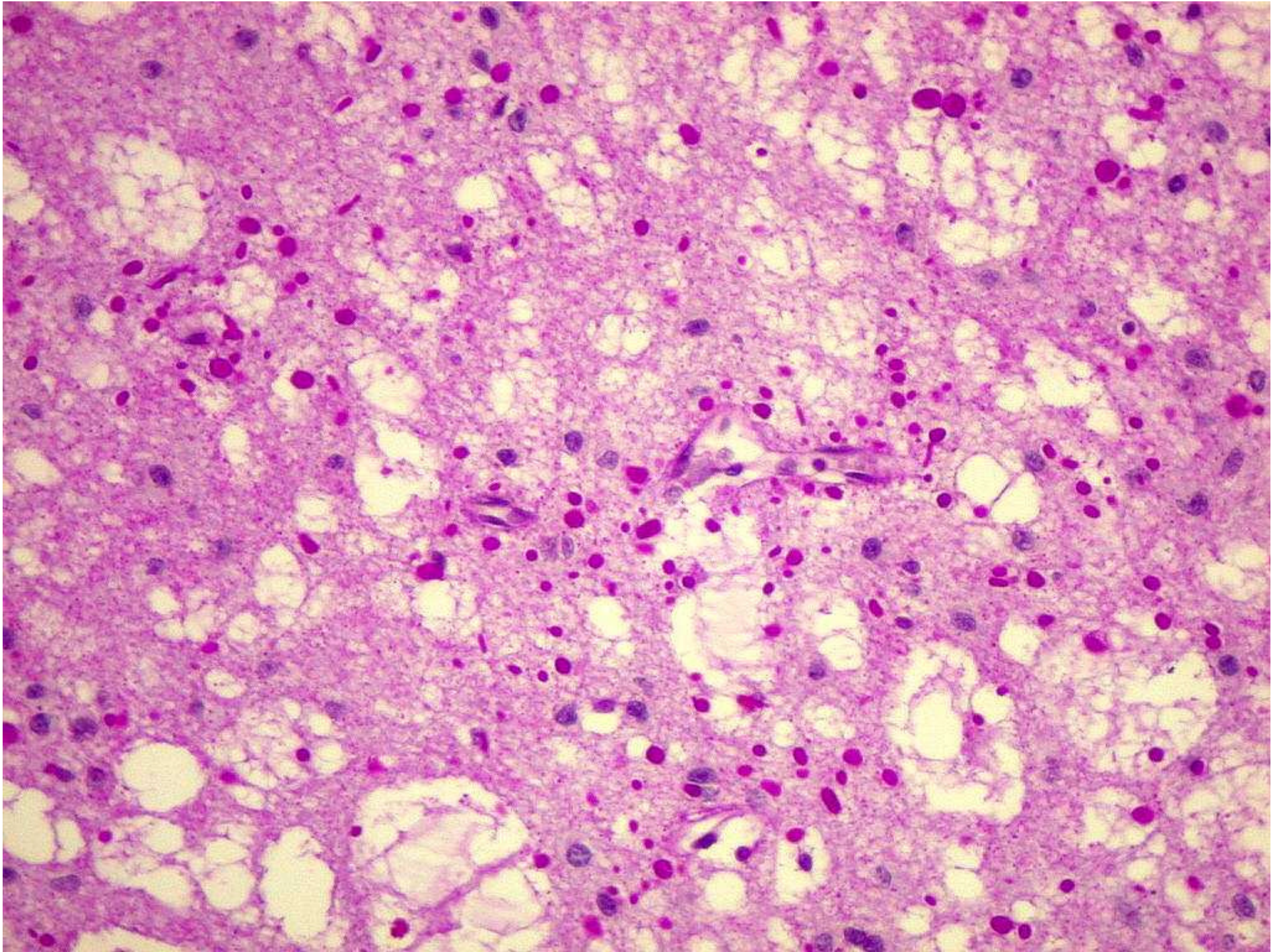













# CASO DO MÊS

## Diagnóstico?







*Obrigado pela  
participação!*