

CASO DO MÊS SBP

Dr^a. Cynthia Koepfel
Berenstein

Dr. Carlos Alberto
Ribeiro



Dados clínicos

- Paciente do sexo feminino de 50 anos
- “Revisão de tumor cerebral”
- Diagnóstico prévio: astrocitoma grau III
- Pedido de revisão de lâminas

Exames de imagem

- Lesão expansiva heterogênea possivelmente sólido-cística intra-axial no hemisfério cerebelar direito circundada por edema sugestivo de edema vasogênico

P1R

M = 532 L = 266

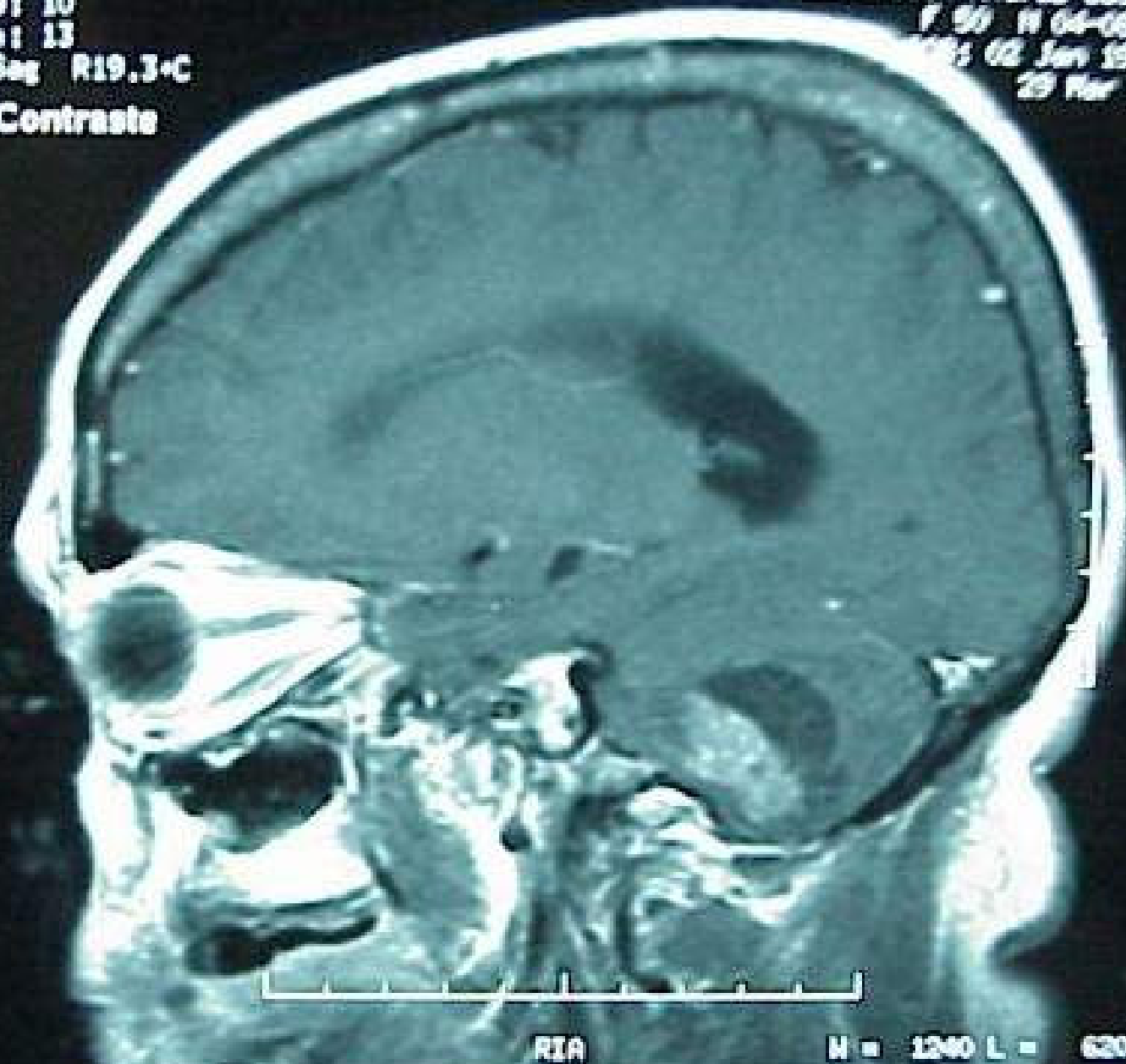Ex: 21108
Se: 10
In: 13
OSeg: R19.3-C
Contraste

LSP

HOSPITAL FELICIO RICO
Elizabeth Amal Costa
T. 50 11 04-0891
1995 02 Jan 1996
29 Mar 04

S2L

H1R



RIA

M = 1240 L = 620

Ex: 21108
Se: 11
In: 14
OCor: P41
Comp: 211

HOSPITAL FELICIO ROCHO
Elizab... General Costa
F. 5... 04-0891
DOB: 05 Jan 1954
20 Mar 04

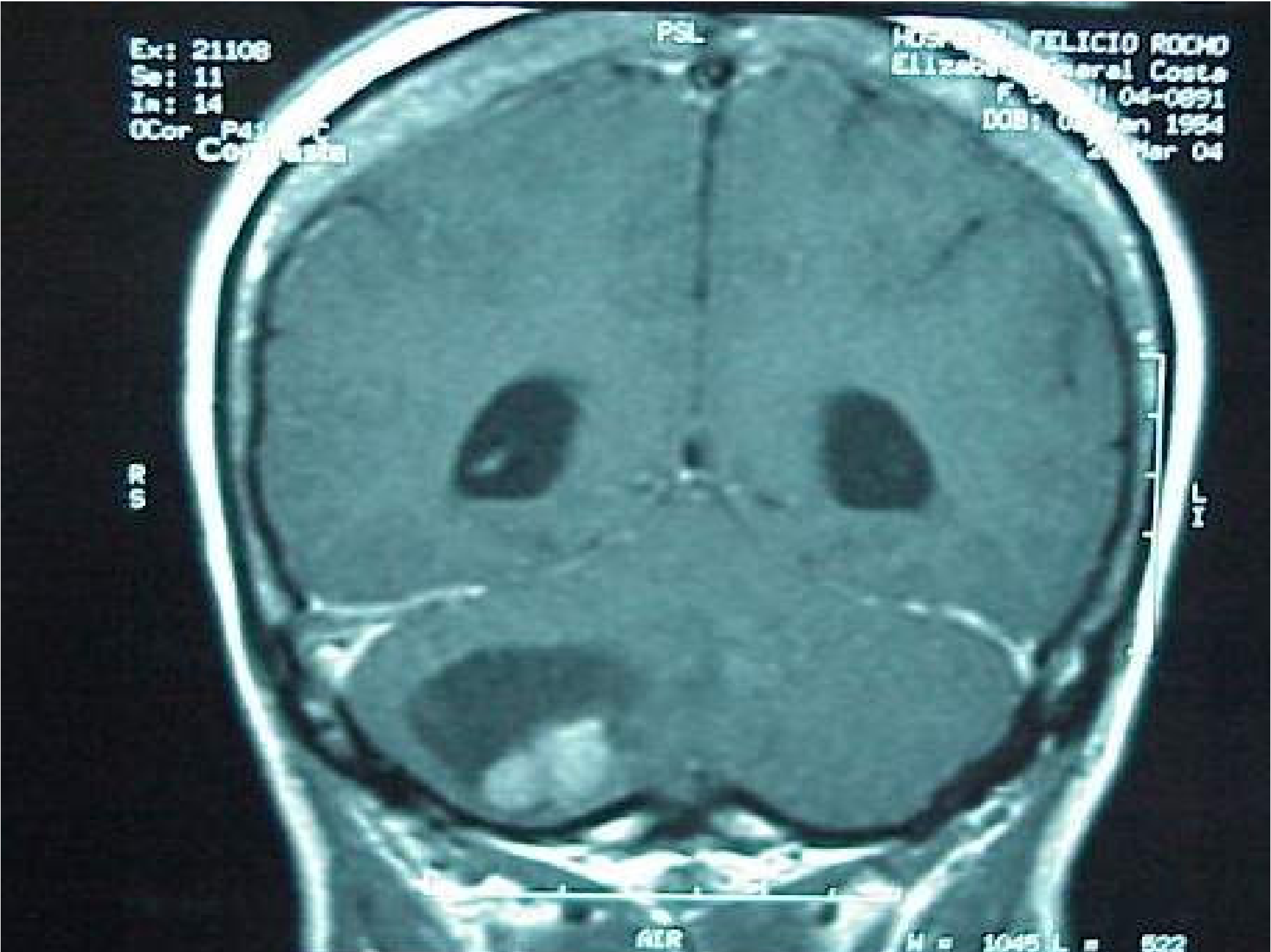PSL

RS

RL

REC

M = 1045 L = 522



Ex: 21108
Se: 5
In: 15
OCor P35/8

PSL

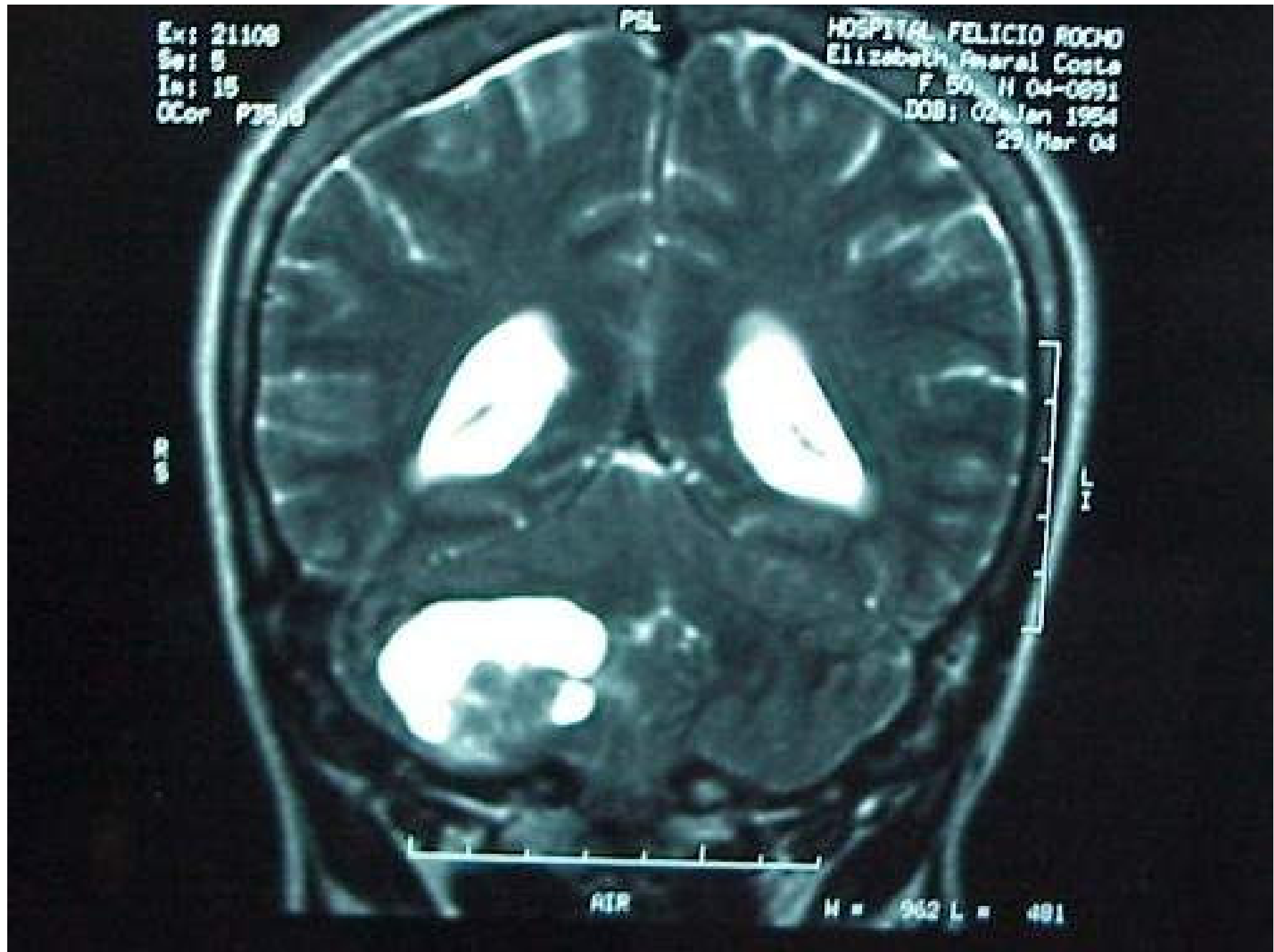
HOSPITAL FELICIO ROCHO
Elizabeth Arenal Costa
F. 50. H 04-0891
DOB: 02 Jan 1954
29 Mar 04

10/25

14/1

AIR

M = 262 L = 481



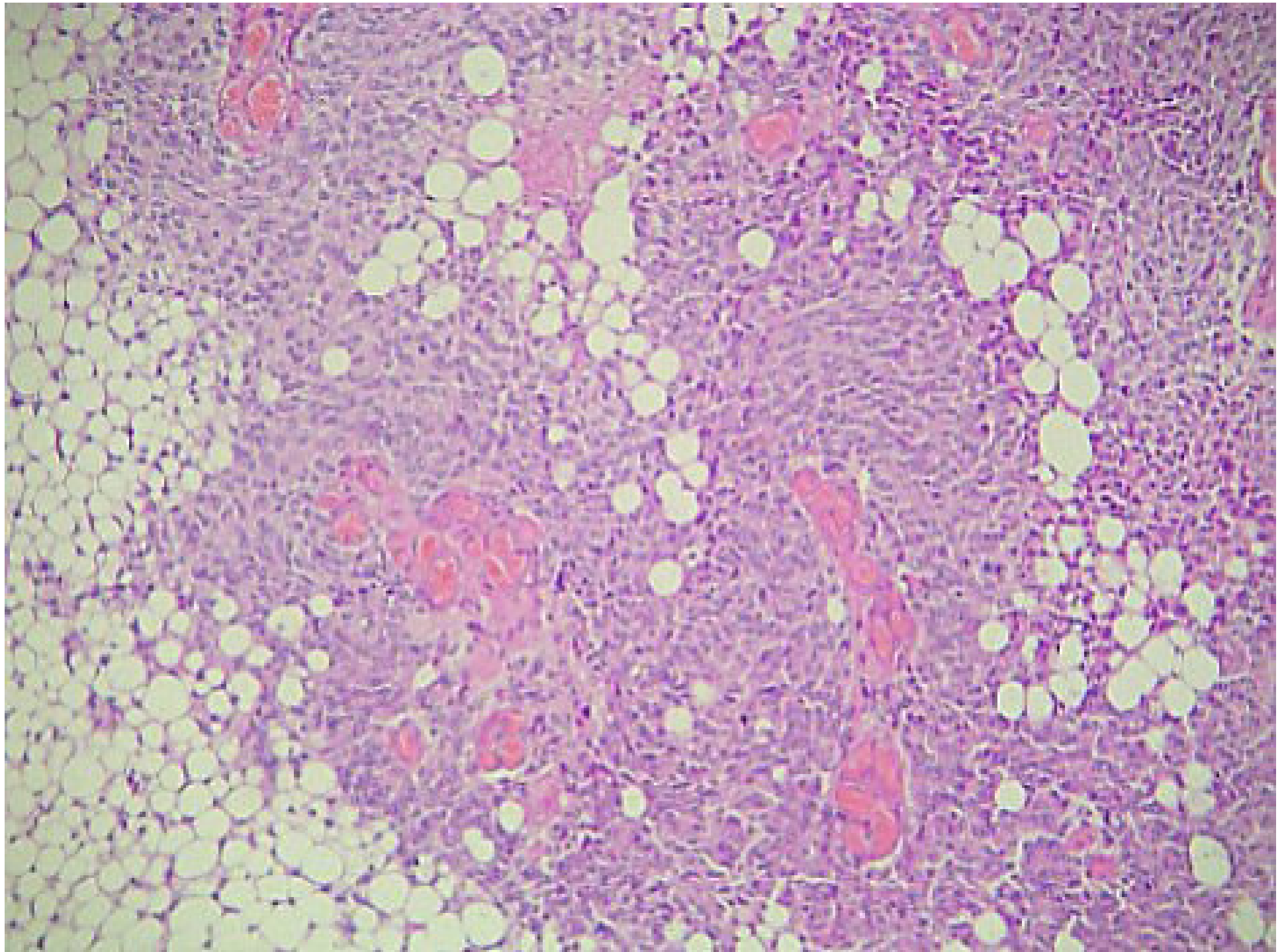
Exames de imagem

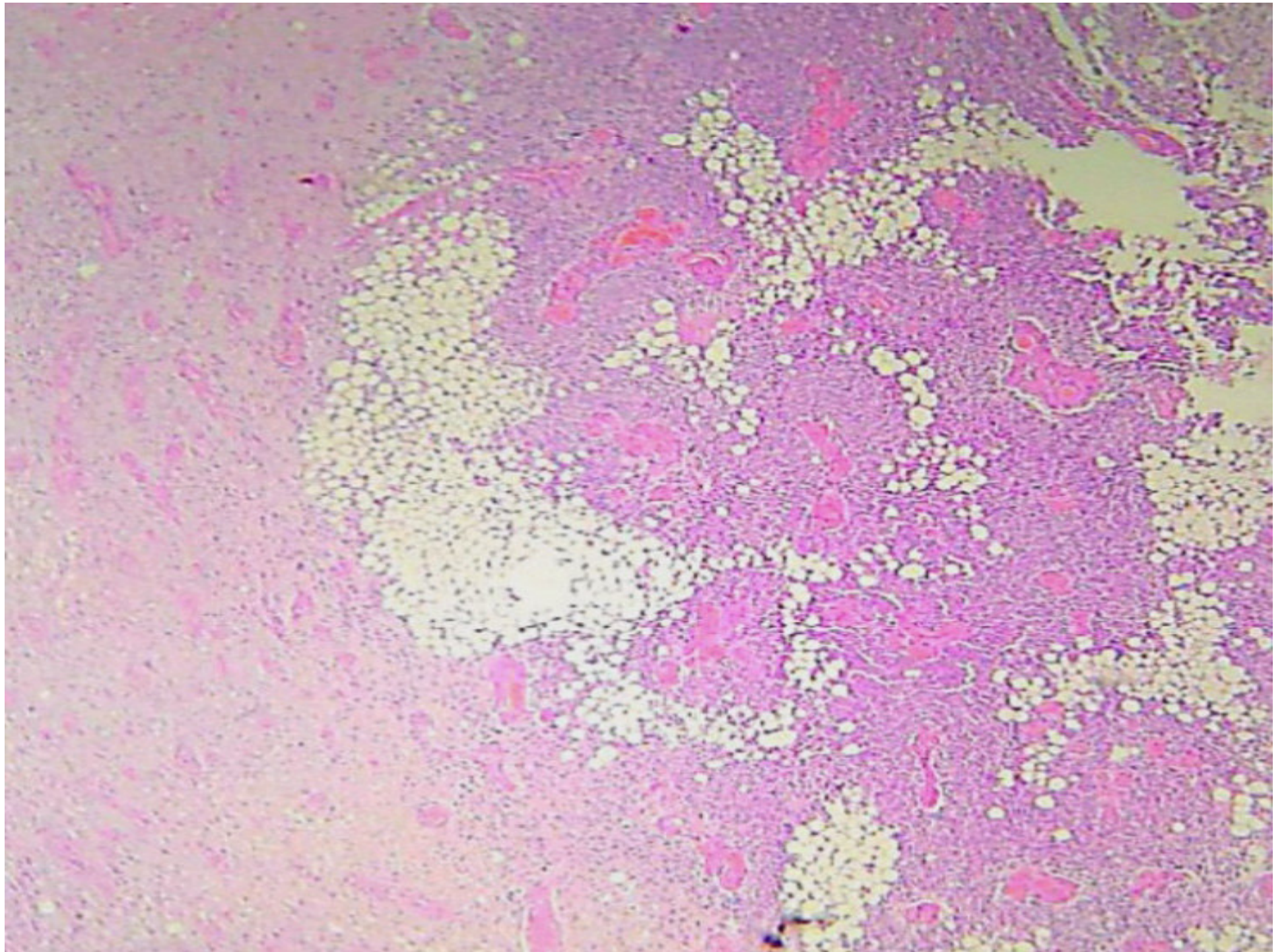
- O conjunto exerce efeito de massa sobre as estruturas adjacentes, havendo desvio do IV ventrículo e do tronco cerebral para a esquerda
- **HD**: Astrocitoma? Hemangioblastoma? Outros?

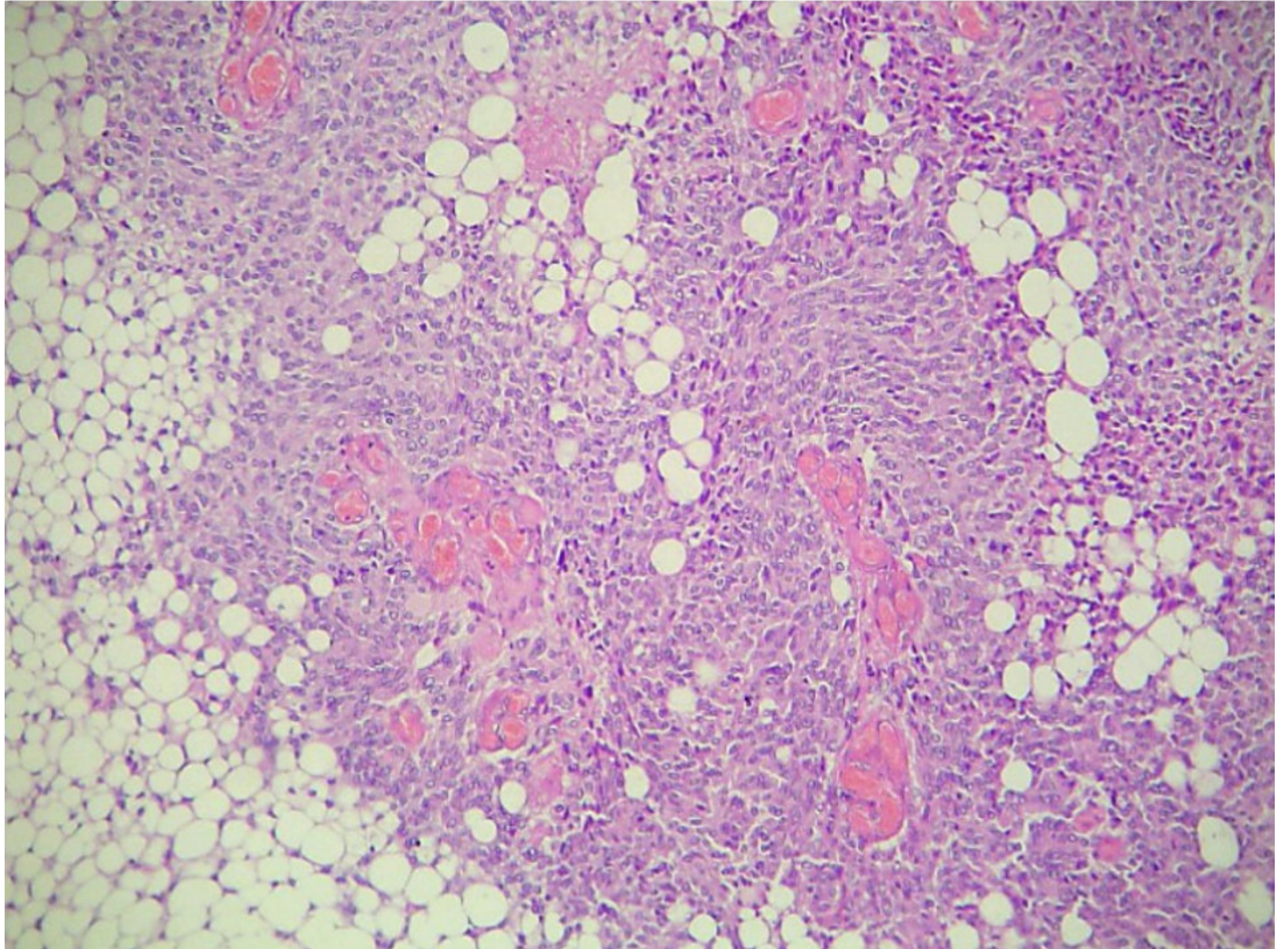


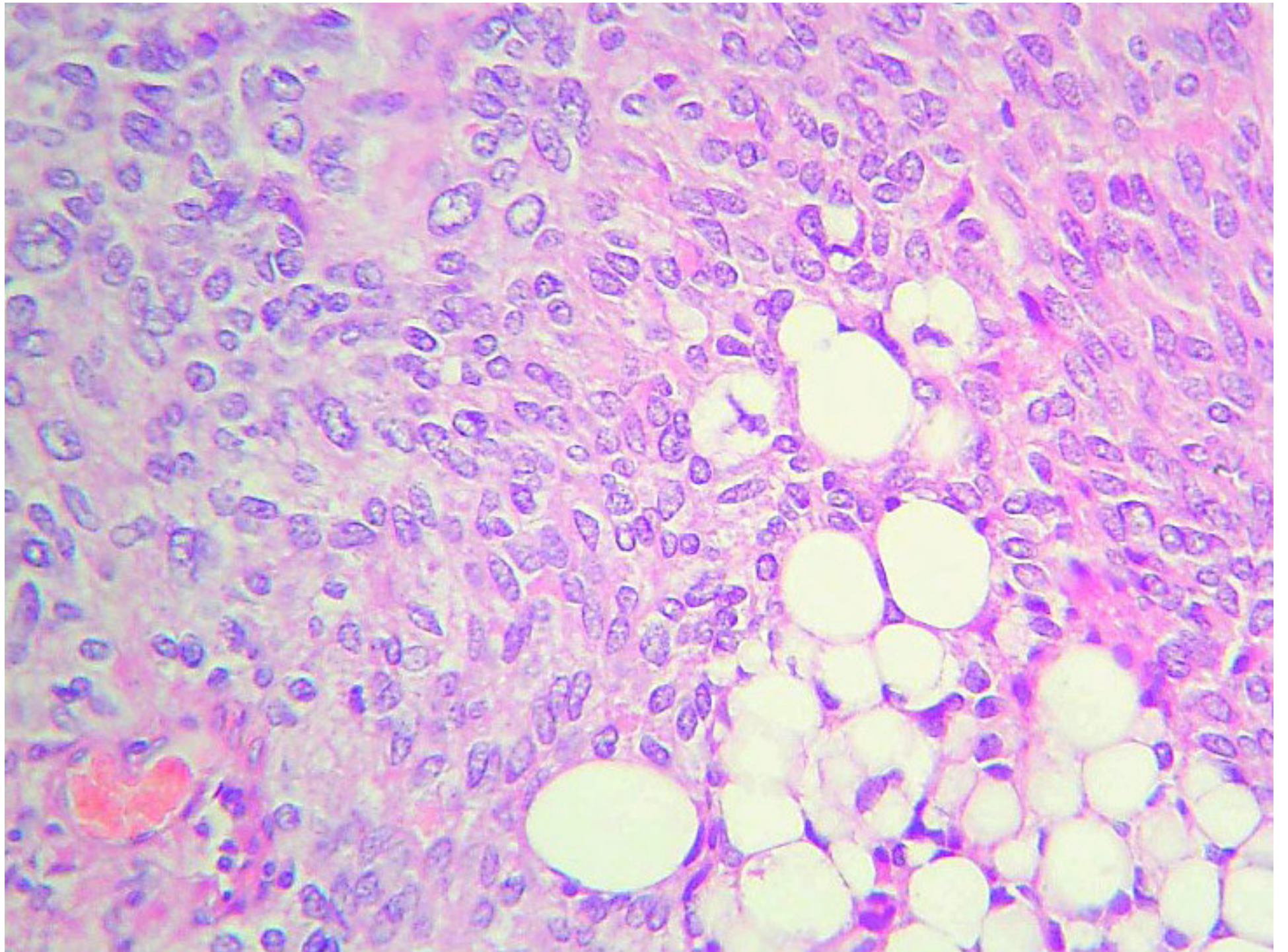
MICROSCOPIA

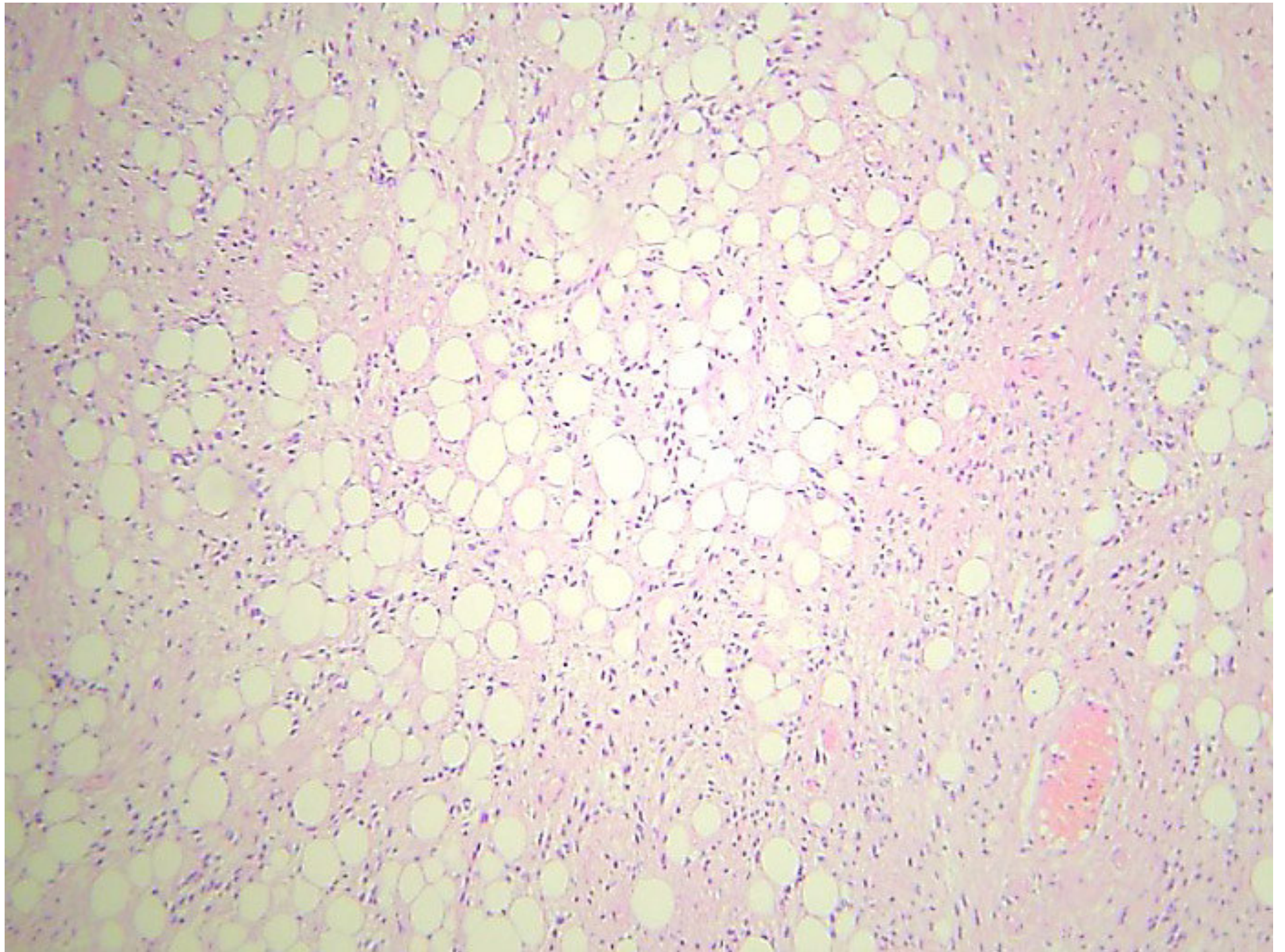


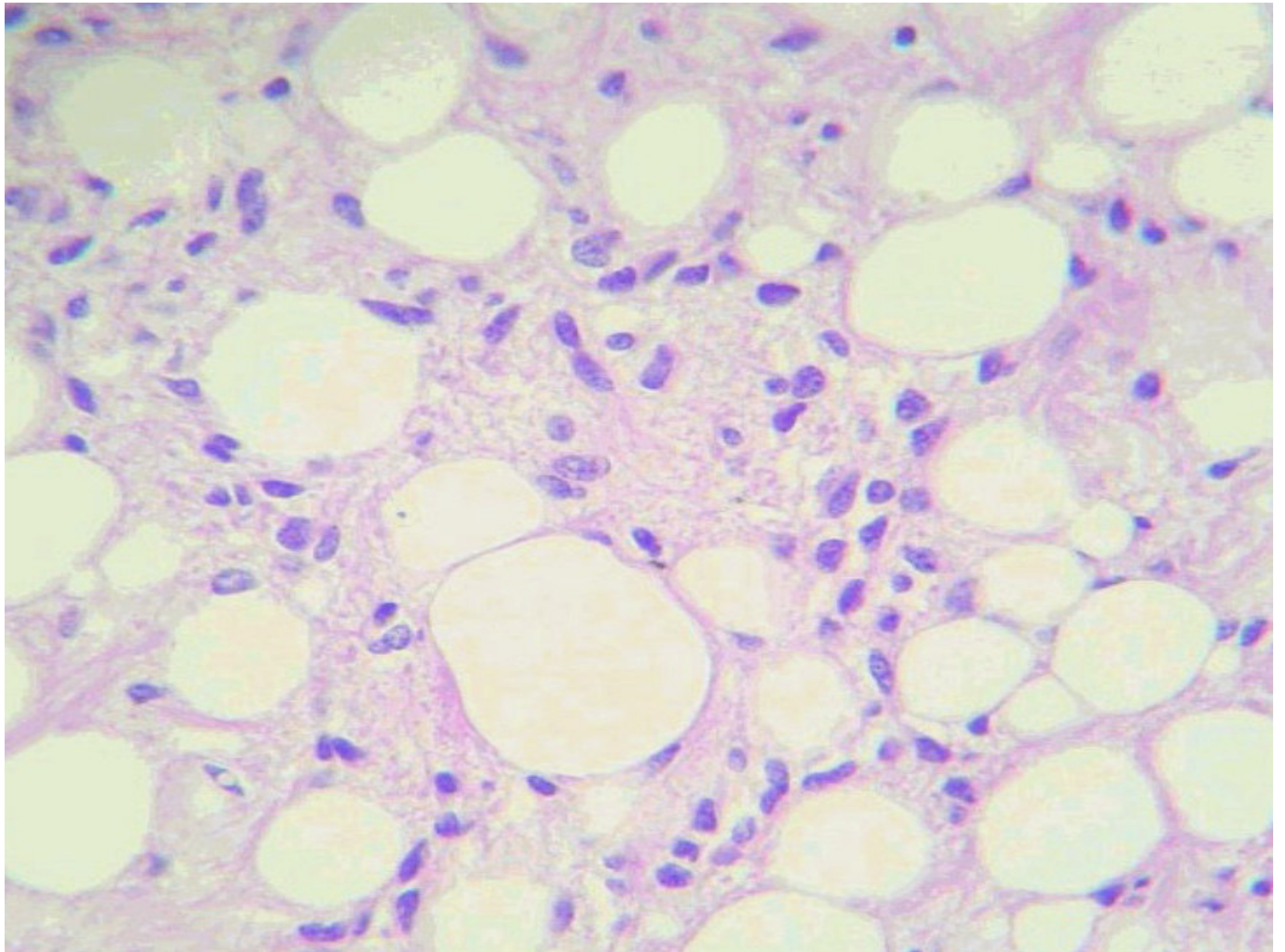


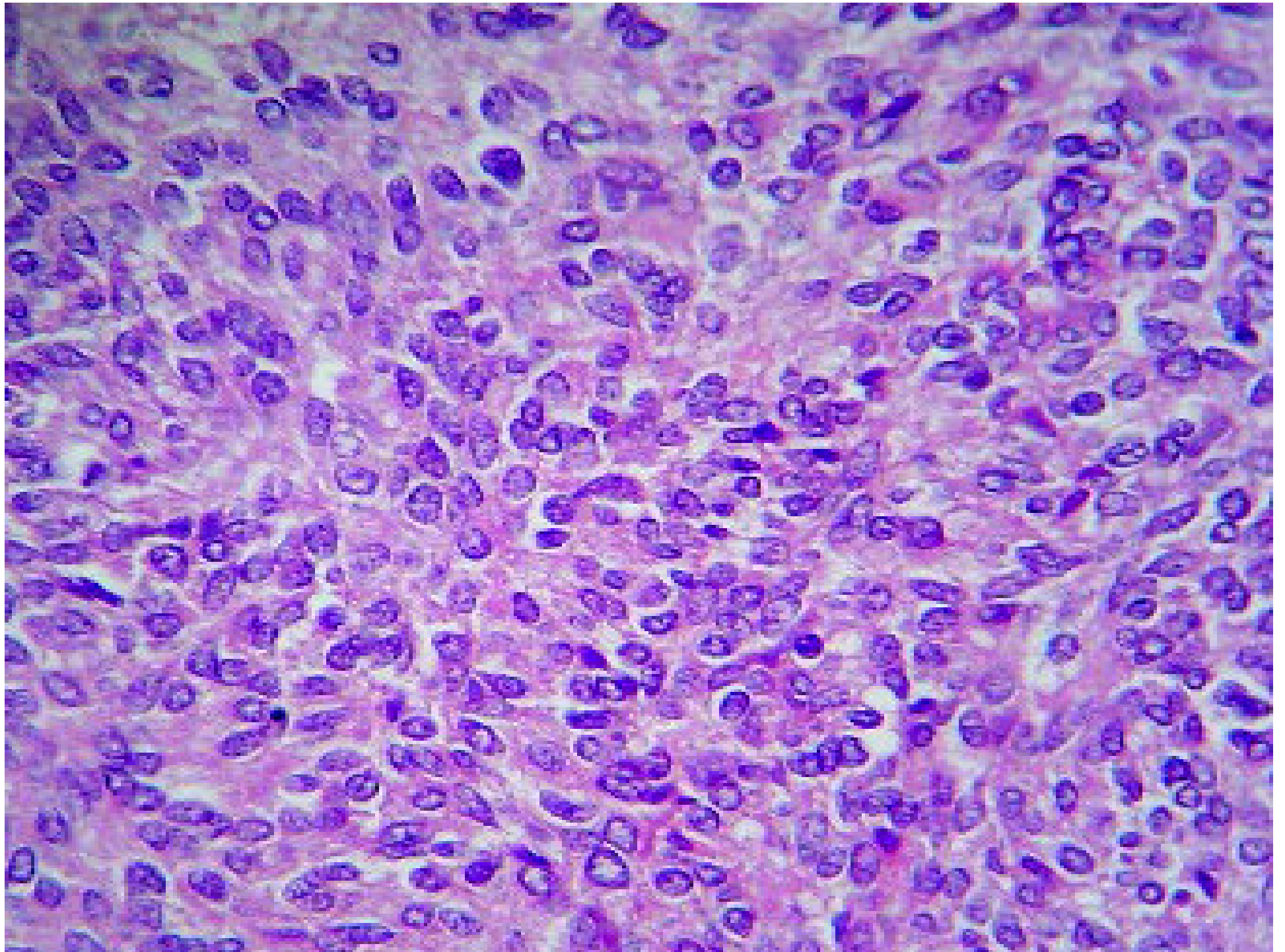


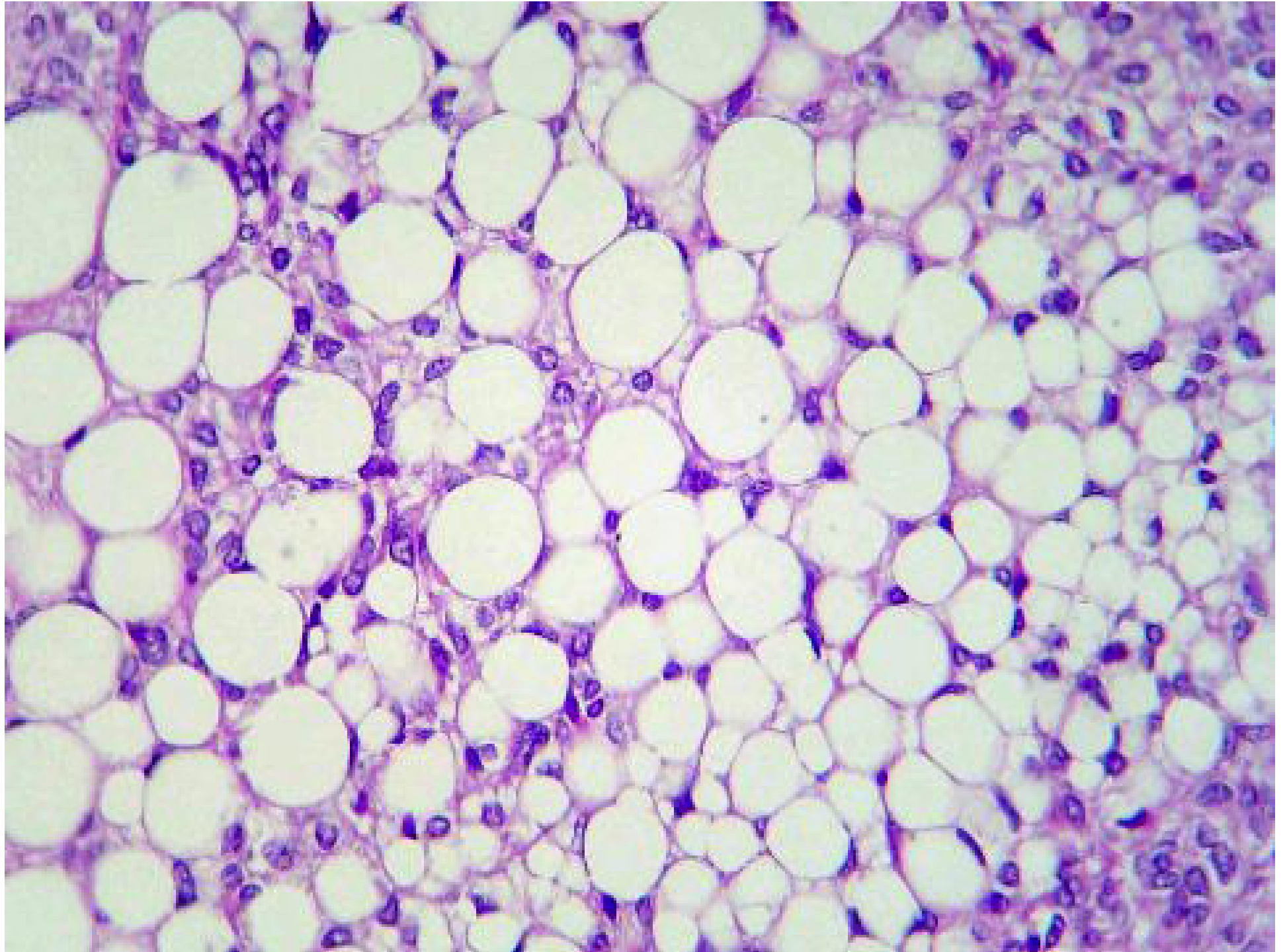


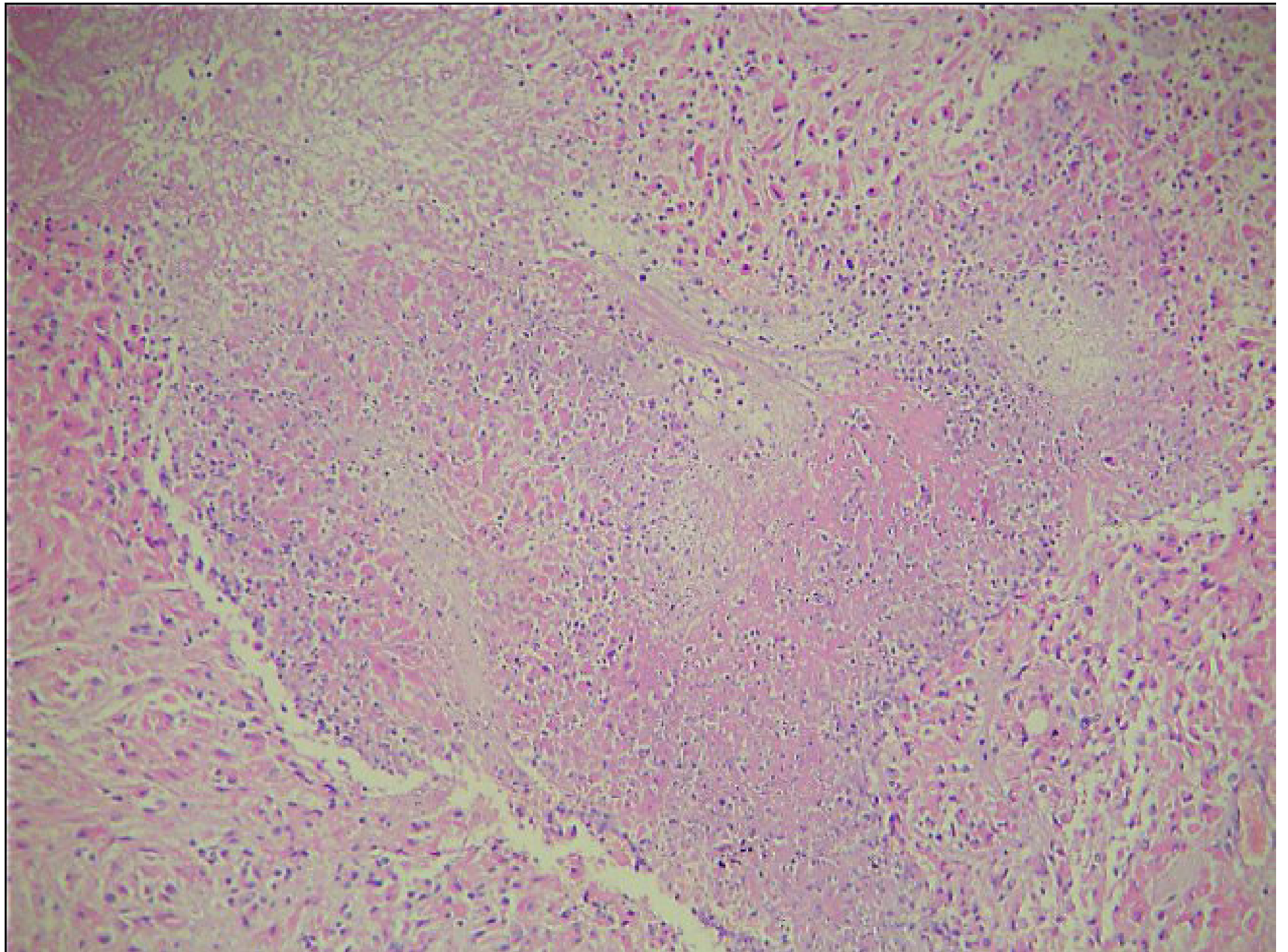


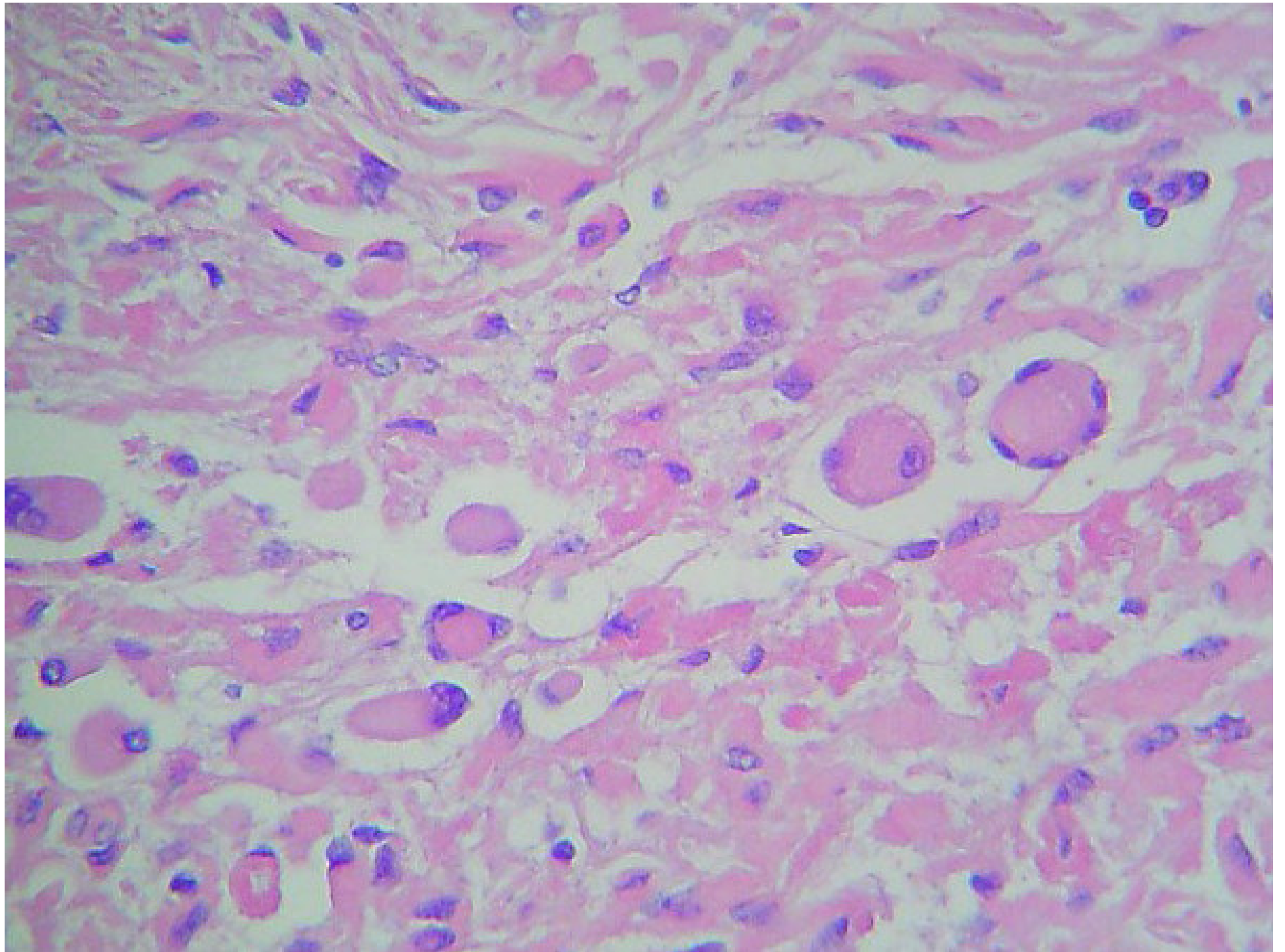












Qual é o diagnóstico?

